

THE POSSIBLE ROLE OF CURCUMIN-CHITOSAN NANOCOMPOSITE IN REDUCING THE IMPAIRMENT EFFECT OF CARBON TETRACHLORIDE ON THE TESTIS TISSUE IN LIVER FIBROSIS MODEL

Fatma Elraei M. Elsherbeny^a, Nehal A. Abu-Elnaga^a, Assma M. Abd El-Azez^a, Neamat H. Ahmed^{b,*}.

^a Zoology Department, Faculty of Science (Girls branch), Al-Azhar University, Cairo, Egypt.

^b Radiation Biology Department, National Center for Radiation Research and Technology (NCRRT), Egyptian Atomic Energy Authority, Cairo, Egypt.

*Corresponding Author: neamathanafi@gmail.com

Received: 29 Dec 2021; Revised: 15 Mar 2022; Accepted: 15 Mar 2022; Published: 01 Jun 2022

ABSTRACT

The goal of the study is to examine the action of Curcumin-Chitosan (Cur-Chito) nanocomposite supplementation against Carbon tetrachloride toxicity (liver fibrosis model) induced testis impairment. Four groups of 60 mice were under investigation; normal control, Carbon tetrachloride, prevention, and treatment group. Mice were IP injected with Carbon tetrachloride (0.5 ml/kg body weight) 3 times /week x4 weeks to induce liver fibrosis injury. While mice were orally administrated Cur-Chito nanocomposite (100ml/k.g. body weight) 5 times/week x 4 weeks as a style of prevention and treatment. The physiological and biochemical analysis, testis and body weights, semen concentration, were all recorded. The treatment with Carbon tetrachloride showed extensive collagen fibers in and around the portal areas in the liver tissue, atrophy of the seminiferous tubules, disrupted basement membrane, decreased sperm count, decreased testis weight, and body weight in the male reproductive system. Improvement in the histological examination (liver and testis tissues), sperm count, and oxidative status in the Cur-Chito nanocomposite administrated groups in comparison to the Carbon tetrachloride administrated groups. In conclusion (Cur-Chito) nanocomposite can prevent and treat testicular complications of liver and testis tissues in Carbon tetrachloride treated mice.

Keywords: Curcumin-Chitosan nanocomposite; Carbon tetrachloride toxicity; Liver fibrosis; Testis tissue damage.

1. INTRODUCTION

Carbon tetrachloride as a chemical compound can damage different organs (testes, kidneys, liver, brain, and lungs) [1]. As a consequence of oxidative stress (OS) state, following Carbon tetrachloride exposure testicular toxicity had been reported [2,3]. within the liver, Carbon tetrachloride is metabolized to free radicals like carbon trichloride (CCl₃). Through the cytochrome P450 oxygenase, enzyme-producing OS

condition CCl₃ free radicals are changed over to trichloromethyl peroxy radical. Through binding to the cytoplasmic membrane polyunsaturated fatty acids, Carbon tetrachloride starts the autoxidation of lipids resulting in membrane damage, reducing enzyme activity, disrupting sexual hormones, and finally inducing necrosis [4].

An extensive amplification of antioxidant enzymes and free radical scavengers against OS was included in testicles. Because peroxidative

damage may currently be considered the most critical reason behind impaired testicular functioning, this antioxidant shield is of significant importance. The body can be protected against various oxidative stresses caused by free radicals through body and food antioxidants [5].

Nowadays, we focused on the role and effect of phytochemicals on oxidative Stress-mediated testicular toxicity [6, 7]. Curcumin is an active compound that has many biological activities [8, 9] and protective action against toxicities [10, 11, and 12]. The pharmacological effects of curcumin could attribute to anti-inflammatory [11, 13], antioxidant [14, 15], anticancer [16] activities. Regardless of numerous therapeutic effects, the bioavailability of curcumin is relatively low with poor intestinal absorption and aqueous solubility, rapid metabolism in the liver and systemic elimination [17, 18, and 19], the nanoformulations of curcumin is the most effective tool to enhance the water solubility, thereby improving its dispersibility, absorption, and bioavailability [20, 21].

Chitosan is a modified natural carbohydrate polymer. Chitosan nanoparticles have gained widespread in pharmaceutical drug delivery [22, 23] and it provides a simple method of nanomedicine applications [22, 24] with better stability, low toxicity profile, and the reliability to be used as a food ingredient [25]. Chitosan has an antioxidant [26, 27], antimutagenicity [28], and anti-inflammatory [29] properties. As in Curcumin, the nanoparticle of Chitosan attracted the attention of researchers from different research areas [27, 30].

The present study aimed to investigate the effect of curcumin –Chitosan nanocomposite supplementation against carbon tetrachloride (CCl₄) induced testicular impairment in male mice

2. MATERIAL AND METHOD

Nano curcumin was purchased from Herbal-Cure co. India, chitosan, sodium tripolyphosphate (TPP), tween 80, and Carbon

tetrachloride from Sigma-Aldrich. All chemicals and solvents used in this study were of analytical grade.

2.1 Induction of liver injury by Carbon tetrachloride

Male mice were intraperitoneal (IP) injected with Carbon tetrachloride (0.5 ml/kg body weight) 1 ml in olive oil (1:1) three times/week x 4 weeks to induce liver fibrosis injury [31].

2.2 Preparation of Curcumin – Chitosan nanocomposite

The preparation of nanocomposite is based on electrostatic interaction between negatively and positively charged molecules such as polyanionic and cationic polymers [32]. In the case of curcumin-chitosan nanocomposite preparation by the aid of tripolyphosphate (TPP), the amino groups that existed on chitosan interact with anionic groups of TPP salt [33].

A stock solution of nano chitosan was made at 6 mg/ml in acidified distilled water and stirred for 10 min. Tween 80 was added to a stock solution of nano curcumin was made at 6 mg/ml dissolved in ethanol and stirred for 10 min. TPP solution as a cross-linker was added to emulsified nano curcumin-chitosan solution in a drop-wise manner and stirred for 10 min. At last, the mixture solution was transferred into a new flask and kept for subsequent analysis.

2.3 Characterization of nanocomposites

2.3.1 Fourier transforms infrared spectroscopy (FTIR)

In the FTIR characterization method, the pattern of the samples was dropped with potassium bromide in the ratio of 1:100 and after drying at room temperature, they were compressed to form discs which were later subjected to FTIR spectroscopy measurement (Genesis series, Unicam, England). These measurements were recorded on a JA SCO FTIR- 3600 and the spectrum was collected at a resolution of 4 cm⁻¹ in a wavenumber region of 400- 4000 cm⁻¹ at the National Center for Radiation Research and Technology (NCRRT), Atomic Energy Authority, Egypt.

2.3.2 Transmission Electron Microscopy (TEM)

Samples for TEM (Hitachi-H-7500) were prepared by drop-coating the nanoparticles solution into the carbon-coated copper grid and the solvent was allowed to evaporate by incubation at 37°C for 30 minutes in an incubator. size and morphology of the nanoparticles were estimated by TEM (JEOL electron microscope JEM-100 CX) at National Center for Radiation Research and Technology (NCRRT), Atomic Energy Authority, Egypt; operating at 80 kV accelerating voltage.

Practically, each mouse of prevention and treatment groups had received orally 0.5 ml of final curcumin – chitosan nanocomposite which contains 3 mg curcumin + 3 mg chitosan five times a week for 4 weeks. The curcumin–chitosan nanocomposite dose is 100 mg/kg body weight.

2.4 Experimental design

The present study has been carried out at the animal house of National Centre for Radiation Research and Technology (NCRRT), atomic Energy Authority (AEA), Cairo, Egypt. Six-week-old male albino mice 25 ± 10 g were obtained from National Cancer Institute (NCI), Cairo University, Egypt. the animals were housed with hygienic measures, constant illumination, suitable temperature, and humidity [34]. Animals were divided randomly into four groups in plastic cages; each group had 15 mice, was left to adapt for one week before the start of the experiment. The four groups are:

1- Negative control group (-ve G): mouse neither injected nor gavage with any treatments.

2- Positive control group (+ve G) mouse was injected intra-peritoneal with Carbon tetrachloride (0.5 ml/kg body weight) 1 ml in olive oil (1:1) three times a week for four weeks.

3- Prevention group (prev. G) lasts for four weeks where the mouse has injected Carbon tetrachloride as group 2 and gavage with Cur-Chito NP (100ml/k.g.) five times a week for four weeks at the same time.

4- Treatment group (treat. G) lasts for seven weeks where the mouse has injected IP with Carbon tetrachloride (0.5 ml/kg body weight) 1 ml in olive oil (1:1) three times a week for four weeks, and 100 ml / k.g. orally administrated with Cur-Chito NP five times a week for another four weeks at the beginning of the 4th week of seven weeks overall duration.

2.5 Investigations

The body weights were recorded from the beginning of the experiment till the end of the experiment.

At the end of the experiment time frame, they waited for 72 hours after the final dose. All experimental animals were weighted and anesthetic by diethyl ether and dissected. Testis and liver of each experimental animal were dissected and immediately washed with buffered saline.

Relative body weight = (final body weight/initial body weight) \times 100 [35].

2.6 Physiological and Biochemical analysis

a blood sample is collected directly from the heart, allowed to clot, and centrifuged at 1200 RPM to estimate inflammatory markers (AFP). The testis of each animal was excised immediately; one testis was washed with ice-cold saline and stored at -80°C . For the estimation of the testes tissue antioxidant enzyme (Glutathione (GSH) malondialdehyde (MDA)) concentrations, a biodiagnostic kit was used (Cairo, Egypt) [36].

2.6.1 Sperm count: According to Pant and Srivastava [37] method the epididymal sperm count was determined.

2.6.2 Histopathological examination: liver and testis tissue organs were fixed in 10% neutral buffered formalin, dehydrated through an ascending degree alcohol series (70, 80, 90, and 100% v/v), cleared with xylene, and embedded in paraffin.

Liver sections stained with Masson's trichrome stain evaluated the liver fibrosis. On the other hand, histopathological examination of the testis tissue sections by hematoxylin and eosin (H&E) staining was recorded.

2.6.3 Statistical analysis: All data are analyses were done using the Statistical Package for the Social Science version 20 for Windows (SPSS Inc, Chicago, IL). The obtained data are presented as mean \pm standard error (SE) for normally distributed continuous data. All data are analyzed statistically using a one-way analysis of variance (ANOVA).

3. RESULTS

3.1 Characterization of Curcumin-Chitosan (Cur-Chito) nanocomposite

Fig. (1) represents the morphology and size of Curcumin-Chitosan (Cur-Chito) nanocomposite. TEM observations revealed that Chitosan nanoparticles of cross-linking (10%) appear as small aggregates. Ultrafine chitosan nanoparticles, as shown by the TEM images, spherical shaped uniform solid dense structure and have nearly uniform particle size distribution, which is very important for drug delivery. The average particle size of chitosan nanoparticles is $60 \text{ nm} \pm 19 \text{ nm}$ and the size for

distribution ranged from 40 to 100 nm (Fig. 1 B). Cur-Chito nanocomposite was subjected to several characterization procedures. TEM results showed that the size ranged from 29 to 39.5 nm (Fig. 1 B). The Infrared spectrum (FTIR) spectra of chitosan, curcumin, and Cur-Chito nanocomposite are shown in (Fig. 1 C). For the essential peaks at cm^{-1} that confirm the formulation of Cur-Chito nanocomposite different spectrum was observed as new bands appeared at 1070 cm^{-1}

3.2 Liver inflammatory marker: Alpha-fetoprotein (AFP) level

The effect of curcumin-chitosan (Cur-Chito) nanocomposite on liver inflammatory marker level (Alpha-fetoprotein, AFP) of mice liver fibrosis induced by carbon tetrachloride (Carbon tetrachloride) was illustrated in Fig. (2). The mean of AFP in the positive control, prevention, and treatment groups were 0.746 ± 0.008 , 0.373 ± 0.010 , and $0.613 \pm 0.017 \text{ IU/mL}$, respectively, represented a highly significant increase

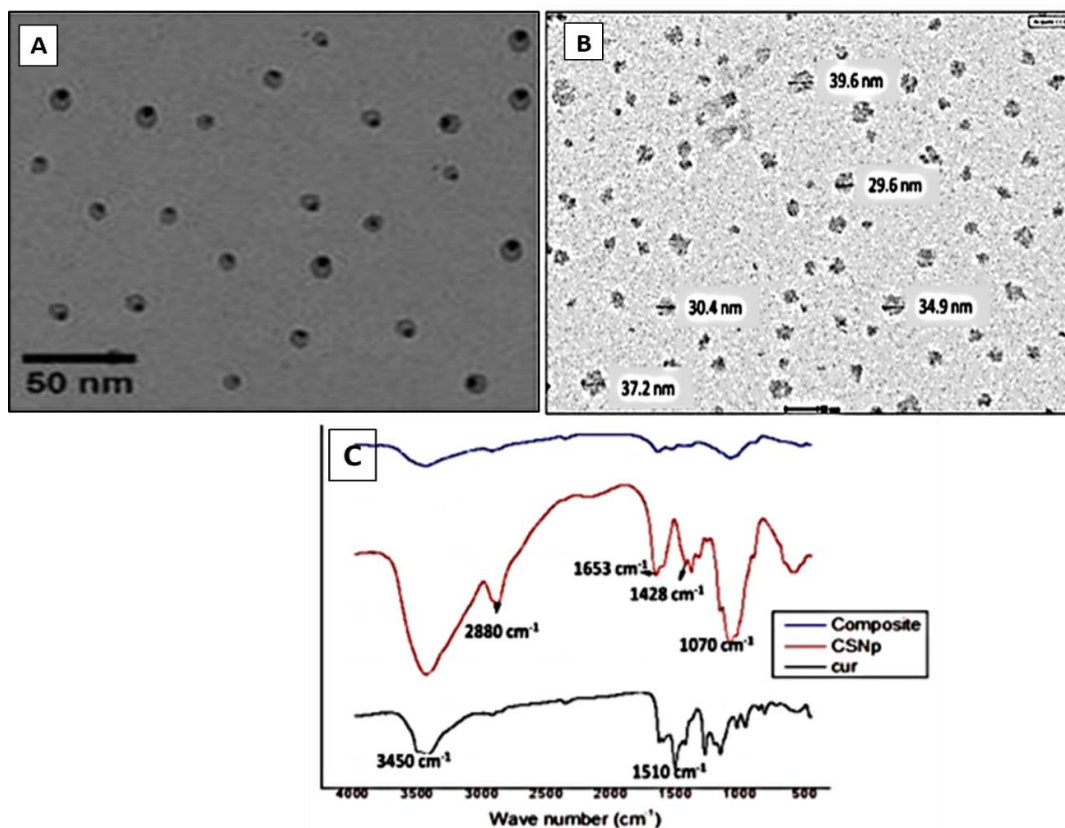


Fig. (1). Morphology and size of Chitosan nanoparticles and curcumin chitosan nanocomposite. (A) TEM Chitosan nanoparticles. (B) TEM curcumin chitosan (Cur-Chito) nanocomposite (C). An infrared spectrum of Curcumin, Chitosan nanoparticles, curcumin chitosan nanocomposite.

($P < 0.01$) than the negative control group (0.228 ± 0.011 IU/mL). In the opposed direction, the prevention and treatment groups showed a highly significant decrease ($P < 0.01$) against the positive control group.

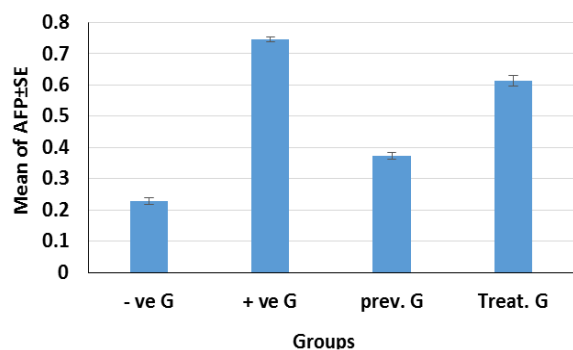


Fig. (2). Effect of curcumin - chitosan (Cur-Chito) nanocomposite on liver inflammatory marker AFP of mice liver fibrosis induced by Carbon tetrachloride

3.3 Histology and histopathology of the liver:

Liver fibrosis (Masson's trichrome stain):

The negative control group (-ve G) represented the normal distribution of collagen fibers around the central veins, branches of hepatic portal veins, and hepatocytes (**Fig.3 A and B**). Meanwhile, in the positive control group (+ ve G) extensive fibrosis in the periportal areas was recorded (**Fig. 3 C, D, and E**).

Meanwhile, in the prevention group (Prev. G) there was a decreased deposition of collagen fibers around the central veins, branches of the portal veins, and hepatocytes (**Fig.3-F and G**). Also, the treatment groups (treat. G) showed a high reduction of collagen fibers in the periportal areas and distinct with less deposition of them around the central veins, branches of the portal veins, and hepatocytes (**Fig.3-H and I**).

3.4 General examination for reproduction

3.4.1 Mean of relative body weight (g), testis weight (g), and sperm count (10^6 /ml suspension)

The effect of curcumin-chitosan (Cur-Chito) nanocomposite on the relative body weight, testis weight, and sperm count (10^6 /ml suspension) of mice suffering from liver fibrosis

induced by carbon tetrachloride (Carbon tetrachloride) is illustrated in Table (1). The mean of relative body weight in positive control and treatment groups were 106.58 ± 1.76 and 113.9 ± 2.42 g, respectively which recorded a highly significant decrease ($P < 0.01$) than the negative control group (134.91 ± 4.57 g). Meanwhile, in prevention group (120.28 ± 4.42 g) recorded a significant decrease ($P < 0.05$).

The negative effect of Carbon tetrachloride-induced liver fibrosis on fertility was observed in the +ve G, which recorded a highly significant decrease ($P < 0.01$) of testis weight and sperm count (0.36 ± 0.03 g and $39.17 \pm 3 \times 10^6$ /ml suspension respectively). On the other hand, the positive effect of curcumin-chitosan (Cur-Chito) nanocomposite occurs in the treat. G and prev. G groups from the fetal effect of Carbon tetrachloride-induced liver fibrosis on infertility. No statistical differences were recorded in the preve. G in testis weight and sperm count (0.62 ± 0.03 g and $64.17 \pm 3 \times 10^6$ /ml suspension respectively) than the - ve G group (0.59 ± 0.03 g and $71.67 \pm 5.27 \times 10^6$ /ml suspension, respectively).

Meanwhile, the treat. G group recorded a highly significant decrease ($P < 0.01$) in sperm count ($50.83 \pm 3 \times 10^6$ /ml suspension) but in the mean of testis weight recorded no statistical differences compared to -ve G group.

3.4.2 Status of oxidative stress and antioxidant status in the testis

The effect of curcumin-chitosan (Cur-Chito) nanocomposite on oxidative stress and antioxidant status of testis in mice suffering from liver fibrosis induced by Carbon tetrachloride was recorded in Table (2). The mean of testis MDA level in + ve G group was 386.74 ± 8.61 μ M/g, which recorded a highly significant increase ($P < 0.01$) than the - ve G group level (261.53 ± 3.89 μ M/g). However, in the same group, recorded a highly significant decrease ($P < 0.01$) in testis GSH level (25.60 ± 1.01 mg/g) compared to - ve G group level (39.62 ± 3.39 mg/g).

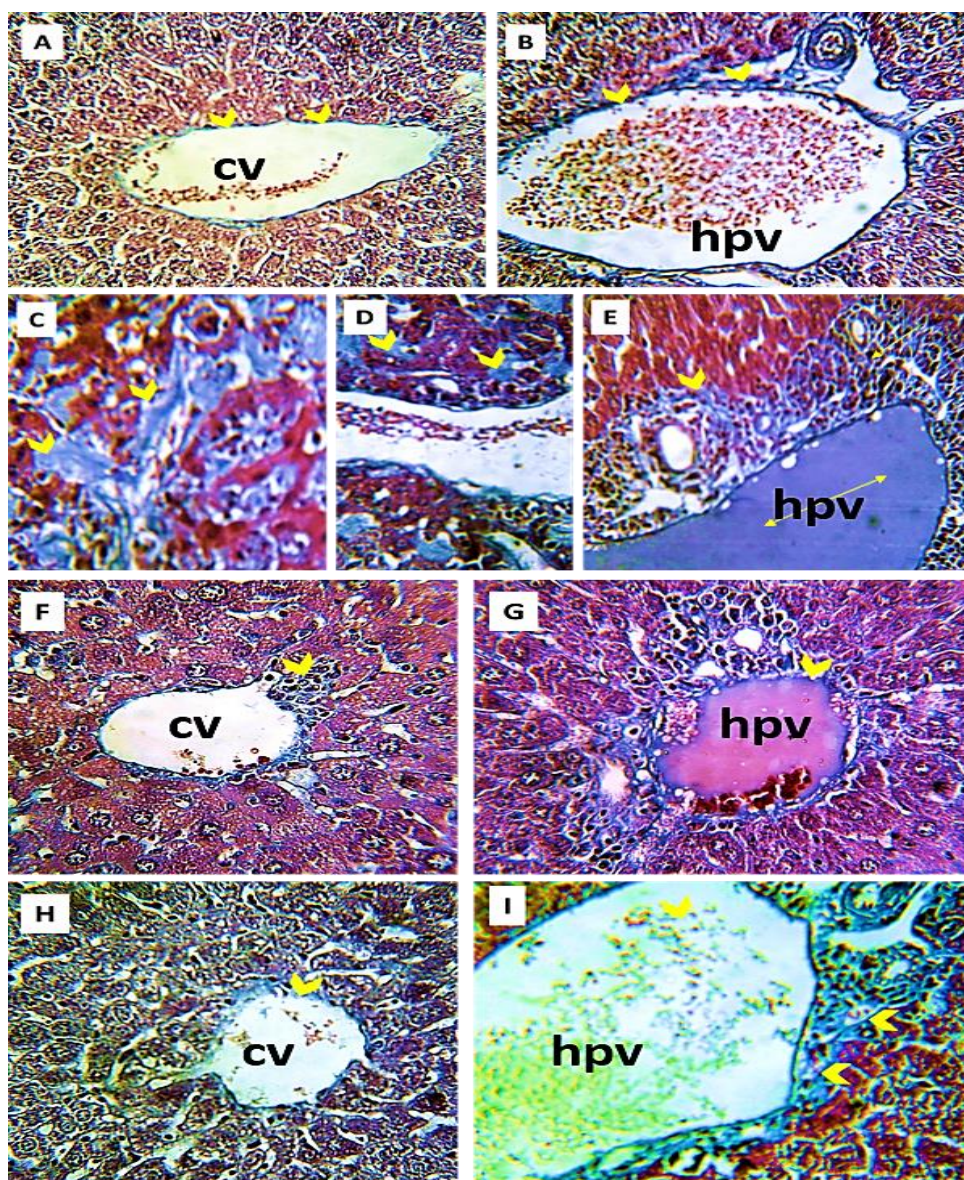


Fig. (3). Photomicrographs of liver tissue sections stained with Masson's trichrome stain represent: **A&B-** The negative control (- ve G) mouse liver section represents the normal distribution of the collagen fibers (arrowhead) around the central vein (CV), branches of the hepatic portal vein (hpv), and hepatocytes, (X 400). **C-E-**The positive group (+ ve G) treated with Carbon tetrachloride showing extensive collagen fibers (arrowhead) in and around the portal areas and dilated branches of the hepatic portal vein (hpv), (X 400). **F&G-** Prevention group (prev. G) showing decreased deposition of the collagen fibers (arrowhead) around the central vein (cv), branches of the hepatic portal vein (hpv), and hepatocytes than the positive control group, (X 400). **H&I-** Treatment group (Treat. G) showing normal deposition of the collagen fibers (arrowhead) around the central vein (cv) and hepatocytes (h), but they increased around the hepatic portal vein (hpv), (X 400).

Table 1: Effect of curcumin - chitosan (Cur-Chito nanocomposite) on the final body weight, testis weight, and sperm count of mice suffering liver fibrosis induced by Carbon tetrachloride

Group \ Parameter	Final body weight (g)	Testis weight (g)	Sperm count (10 ⁶ /ml suspension)
- ve G	134.91 ± 4.57	0.59 ± 0.03	71.67 ± 5.27
+ ve G	106.58 ± 1.76 ^{a**}	0.36 ± 0.03 ^{a**}	39.17 ± 3 ^{a**}
Prev. G	120.28 ± 4.42 ^{a*b*}	0.62 ± 0.03 ^{b**}	64.17 ± 3 ^{b**}
Treat. G	113.9 ± 2.42 ^{a**}	0.44 ± 0.08	50.83 ± 3 ^{a** b*}

Data recorded as mean ± S.E; (a) significant from - ve G; (b) significant from + ve G. (*) means statistically significant (P value <0.05); (**) means highly significant (P value <0.01). negative control group (- ve G); positive control group (+ ve:: prev). prevention group(G); treatment group (Treat. G).

On the other hand, no statistical differences in testis MDA and GSH levels of the prevention group ($290.29 \pm 15.97 \mu\text{M/g}$ and $44.89 \pm 3.54 \text{ mg/g}$ respectively) compared to the - ve G group level ($261.53 \pm 3.89 \mu\text{M/g}$ and $39.62 \pm 3.39 \text{ mg/g}$ respectively). The mean MDA level in the treat. G group was $215.43 \pm 16.92 \mu\text{M/g}$, recording a significant decrease ($P < 0.05$) than the - ve G group level. Whenever no statistical differences of prevention group in GSH level in the same groups.

3.4.3 The histopathological changes in the spermatogenesis

The standard histological testis structure (Fig.4- A) of the negative control group (- ve

G) showed the germinal cells from spermatogonia to spermatids with total sperms maturation. Seminiferous tubules have intact basement membranes with a regular appearance of Leydig cells (L). Meanwhile, the Carbon tetrachloride positive control group (+ve G) showed edema between the seminiferous tubules with atrophied and distorted Leydig cells, atrophy in some seminiferous tubules, disrupted basement membranes, and spermatogenic layers. Some tubules showed reduced spermatogenic layers in their cells (Fig.4-B-D), especially the spermatozoa (oligospermia).

Table 2: effect of curcumin - chitosan (Cur-Chito) nanocomposite on oxidative stress (MDA) and antioxidant status (GSH) of mice suffering from liver fibrosis induced by Carbon tetrachloride

Parameter		MDA ($\mu\text{M/g}$)	GSH (mg/g)
Group	Mean \pm S.E.		
- ve G	Mean \pm S.E.	$261.53 \pm 3.89^{b**}$	$39.62 \pm 3.39^{b**}$
+ ve G	Mean \pm S.E.	$386.74 \pm 8.61^{a**}$	$25.60 \pm 1.01^{a**}$
Prev. G	Mean \pm S.E.	$290.29 \pm 15.97^{b**}$	$44.89 \pm 3.54^{b**}$
Treat. G	Mean \pm S.E.	$215.43 \pm 16.93^{a*b**}$	33.83 ± 6.54

Legends as in Table 1

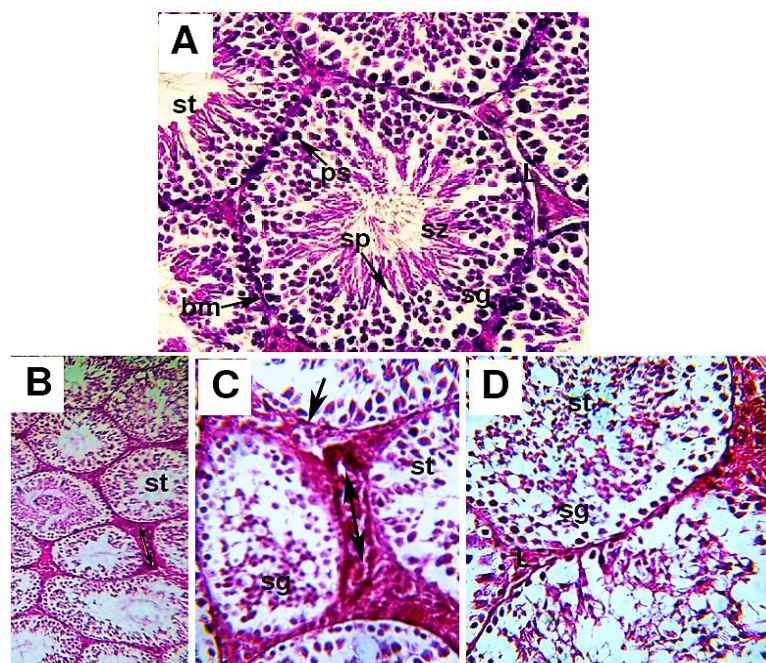


Fig. (4). photomicrographs of sections in testes of mice for the negative control (- ve G) and The positive control group (+ ve G). **A:** - ve G group representing, seminiferous tubules (st) have intact basement membranes (bm), interstitial spaces, Leydig cells (L) with all successive stages of spermatogenesis (spermatogonia (sg), primary spermatocytes (ps), spermatid (sp), numerous spermatozoa (Sz)). **B-D:** + ve G showing atrophy of the seminiferous tubules (st), disrupted basement membrane (arrow), reduced spermatogenic layers (sg) with the debris of them, and edema in the interstitial spaces (\downarrow) with atrophied and distorted Leydig cells (L). (H&E, A x400, B x100 & C-D x400)

The prevention group (Prev. G) showed improvement in the architecture of testicular tissue, but some of the seminiferous tubules have corrugated basement membranes. The present study showed successive spermatogenesis stages in some seminiferous tubules, and their lumens were filled with spermatozoa. Notice: widened spaces between the seminiferous tubules with fewer distorted Leydig cells (**Fig.5– A and B**). Meanwhile, most seminiferous tubules restored their usual appearance in the treatment group, but few showed reduced germ cells with pyknotic nuclei. Distorted some Leydig cells were also observed in the treat. G (**Fig.5–C and D**).

4. DISCUSSION

Activation of carbon tetrachloride (Carbon tetrachloride) into toxic free radicals reacts with critical biological substances such as proteins,

amino acids, nucleotides, nucleic acids, and lipids. in experimental models in rats, Carbon tetrachloride has been extensively used for hepatic fibrosis induction. In rats, chronic Hepatic responses to Carbon tetrachloride stimulation are similar to those in human cirrhosis [38].

Curcumin has cancer-inhibitory effects on many types of malignancies either in the reproductive, digestive, urinary, pulmonary, or nervous systems. Also, a protective effect against the development of conditions linked to inflammation was also recorded [39]. However, the use of curcumin in therapeutic applications is restricted by its metabolic instability and poor absorption and bioavailability [40]. Therefore, the use of curcumin in the nanoparticles form in this study to overcome these difficulties was recommended [41].

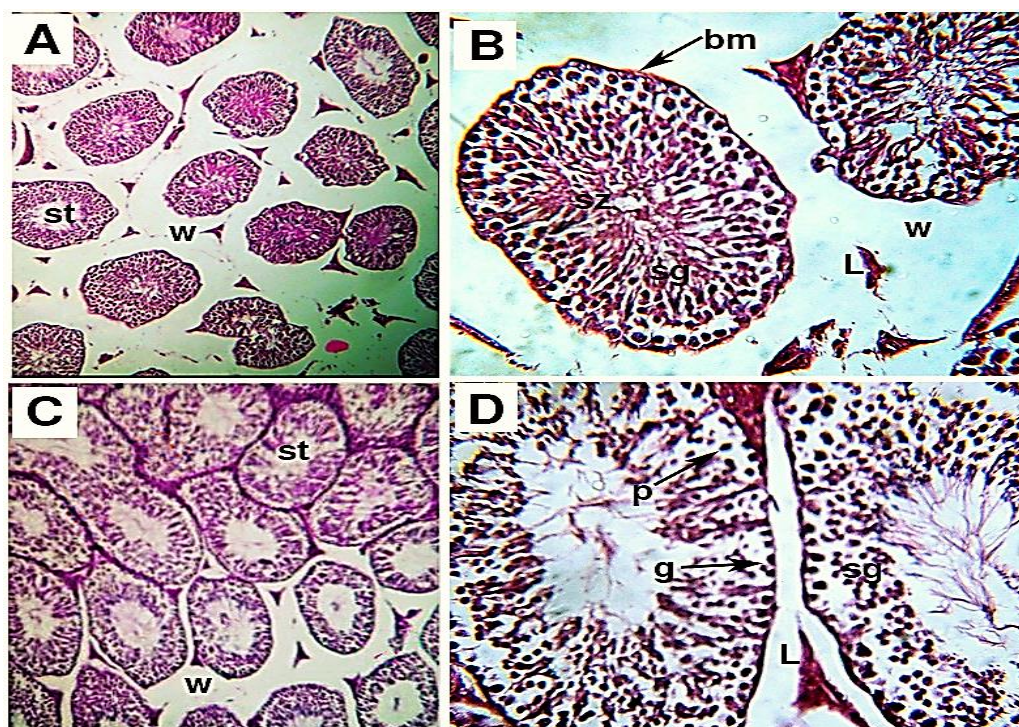


Fig. (5). photomicrographs of sections in testes of mice for the prevention (prev. G) and treatment (treat. G) groups: **A&B:** Prev. G shows the protection for the architecture of seminiferous tubules (st), which are lined by spermatogenic layer (sg) and corrugated basement membrane (bm). Their lumens contain spermatozoa (Sz). Widening space (w) between the seminiferous tubules and distorted Leydig cells (L) are noticed. Also, all successive stages of spermatogenesis (sg) are seen. **C&D:** Treat. G showing a reduction germ cells (g) number. The basal compartment of some seminiferous tubules (st) lined with germ cells with Pyknotic nuclei (p) and some seminiferous tubules are seen with more or less normal spermatogenic cell lines (sg) and some widening spaces (w) between the seminiferous tubules (st) and some distorted Leydig cells (L) are also seen. (H&E stain **A, C** x100 & **B, D** x 400).

To study the effect of Cur-Chito nanocomposite preventing liver fibrosis, in a Carbon tetrachloride-induced liver fibrosis model in male Albino mice.

Our data revealed that in Carbon tetrachloride-induced liver fibrosis model in male Albino mice showed extensive fibrosis in the hepatic periportal areas and a significant increase in inflammatory marker AFP enzymes' serum activities, indicating liver tissue damage.

Diminution of hepatocellular damage for the Gavage treatment of experimental animals with Cur-Chito nanocomposite in prev. G or treat. G groups. A less deposition of collagen fibers around the central vein, portal vein, and hepatocytes and decreased AFP enzymes activities compared to the + ve G group. Iwai et al., [42] recorded that curcumin might have protective potential against Carbon tetrachloride-induced liver damage.

The present study was recorded a highly significant reduction of relative body weight, testis weight, and sperm count in + ve G compared to - ve G control ones. In + ve G administration of Carbon tetrachloride in liver fibrosis model can generate free radicals leading to oxidative stress affecting testicular germline, testicular weight, and even sperm count [43].

Fidan and Dündar [44] proposed that keeping equilibrium between the reactive oxygen species (ROS) and the antioxidants maintained the normal cellular function [44]. During cellular metabolism or particular chemicals exposure ROS formed [45]. In male infertility permanent exposure of spermatozoa to the "oxygen paradox", results in excessive generation of ROS [46]. The use of antioxidants can prevent cell damages induced by ROS [47]. Many research in recent years focused on the use of nanoparticles as carrier molecules to empower nano-drugs to reach the chosen targets. Due to the smaller size of these nano-drugs particles, it can be transported easily to different body organs via blood circulation [48, 49].

In the present study, in + ve G induction of liver fibrosis due to Carbon tetrachloride administration caused histopathological alterations, a highly significant decrease in GSH, and a highly significant increase in MDA levels of testes tissues which indicates that the antioxidant defense system failed to inhibit the formation of free radicals and led to damage testes tissue.

Pretreatment with Cur-Chito nanocomposite in prev. G group before Carbon tetrachloride administration induced remarkable improvement in the histological examination and all biochemical parameters of the testes tissue.

Nano curcumin has a role in protecting tissues against oxidative damage through its antioxidant and anti-inflammatory properties [50,51].

On the other hand, chitosan nanoparticles singly or plus another supplement suppress the oxidative stress [52]. Also, in agreement with our results, the administration of curcumin nano-encapsulation as a daily supplement improved the spermatogenesis defects induced by Carbon tetrachloride-treated mice [53]. Also, chitosan nanoparticles could protect rat testis from oxidative damage and apoptosis caused by lead acetate, increasing antioxidants, and inhibiting caspase three expressions [54].

5. CONCLUSION

The use of Cur-Chito nanocomposite supplementation can prevent and treat testicular complications of liver fibrosis model in Carbon tetrachloride treated mice.

6. ACKNOWLEDGEMENT

The author is grateful to the Department of Cell Biology and Histology in the National Center for Radiation Research and Technology (NCERT), Egyptian Atomic Energy Authority, for her efforts and guidance.

REFERENCES

- [1] Ganie S, Haq E, Hamid A, Qurishi Y, Mahmood Z, Zargar B, Zargar M. Carbon tetrachloride-

- induced kidney and lung tissue damages and antioxidant activities of the aqueous rhizome extract of *Podophyllum hexandrum*. *BMC Complementary and Alternative Medicine*, 2011; 11(1):1-10.
- [2] Khaki A, Ouladsahebmadarek E, Javadi L, Farzadi L, Fathiazad F, Nouri M. Anti-oxidative effects of citro flavonoids on spermatogenesis in rat. *African Journal of Pharmacy and Pharmacology*, 2011; 5(6): 721-725.
- [3] Al-Olayan E, El-Khadragy M, Aref A, Othman M, Kassab R, Abdel Moneim A. The potential protective effect of *Physalis peruviana* L. against carbon tetrachloride-induced hepatotoxicity in rats is mediated by suppression of oxidative stress and downregulation of MMP-9 expression. *Oxidative Medicine and Cellular Longevity*, 2014; 2(1):12-7.
- [4] Abouzed, M.; Eltahir, H.; Taye, A. and Abdelrahman, M. (2016): Experimental evidence for the therapeutic potential of tempol in the treatment of the acute liver injury. *Molecular and Cellular Biochemistry*, 411(1-2): 107-115.
- [5] Devi R, Boruah D, Sharma D, Kotoky, J. Leaf extract of *Clerodendron colebrookianum* inhibits intrinsic hypercholesterolemia and extrinsic lipid peroxidation. *International Journal of PharmTech Research*, 2011; 3(2): 960-967.
- [6] El - Demerdash F, Jebur A, Nasr H, Hamid H. Modulatory effect of *Turnera diffusa* against testicular toxicity induced by fenitrothion and/or hexavalent chromium in rats. *Environmental Toxicology*, 2019; 34(3):330-339.
- [7] Hfaiedh M, Brahmi D, Zourgui M, Zourgui L. Phytochemical analysis and nephroprotective effect of cactus (*Opuntia ficus-indica*) cladodes on sodium dichromate-induced kidney injury in rats. *Applied Physiology, Nutrition, and Metabolism*, 2019; 44(3):239-247.
- [8] Amalraj A, Pius A, Gopi S, Gopi S. Biological activities of curcuminoids, other biomolecules from turmeric and their derivatives—A review. *Journal of Traditional and Complementary Medicine*, 2017; 7(2): 205-233.
- [9] Kocaadam B, Şanlıer N. Curcumin, an active component of turmeric (*Curcuma longa*), and its effects on health. *Critical Reviews in Food Science and Nutrition*, 2017; 57(13): 2889-2895.
- [10] El-Maddawy Z, El-Sayed Y. Comparative analysis of the protective effects of curcumin and N-acetyl cysteine against paracetamol-induced hepatic, renal, and testicular toxicity in Wistar rats. *Environmental science and pollution research*, 2018; 25(4), 3468-3479.
- [11] Cao L, Zhi D, Han J, Kumar- Sah S, Xie Y. Combinational effect of curcumin and metformin against gentamicin-induced nephrotoxicity: involvement of antioxidative, anti-inflammatory and anti-apoptotic pathway. *Journal Food Biochemistry*, 2019; 43:1-9.
- [12] Aslanturk A Uzunhisarcikli M. Protective potential of curcumin or taurine on nephrotoxicity caused by bisphenol A. *Environmental Science and Pollution Research*, 2020; 27(19): 23994-24003.
- [13] Zhang J, Tang L, Li G, Wang J. The anti-inflammatory effects of curcumin on renal ischemia-reperfusion injury in rats. *Renal Failure*, 2018; 40(1): 680-686.
- [14] Samarghandian S, Azimi-Nezhad M, Farkhondeh T, Samini F. Anti-oxidative effects of curcumin on immobilization-induced oxidative stress in rat brain, liver, and kidney. *Biomedicine and Pharmacotherapy*, 2017; 87:223-229.
- [15] Belhan S, Yıldırım S, Huyut Z, Özdek U, Oto G, Algül S. Effects of curcumin on sperm quality, lipid profile, antioxidant activity and histopathological changes in streptozotocin - induced diabetes in rats. *Andrologia*, 2020; 52(6): 13584-13594.
- [16] Tomeh M, Hadianamrei R, Zhao X. A review of curcumin and its derivatives as anticancer agents. *International Journal of Molecular Sciences*, 2019; 20(5):1033-1043.
- [17] Pan M, Huang T, Lin J. Biotransformation of curcumin through reduction and glucuronidation in mice. *Drug metabolism and disposition*, 1999; 27(4), 486-494.
- [18] Anand P, Kunnumakkara A, Newman R, Aggarwal B. Bioavailability of curcumin: problems and promises. *Molecular Pharmaceutics*, 2007; 4(6):807-818.
- [19] Dei Cas M, Ghidoni R. Dietary curcumin: correlation between bioavailability and health potential. *Nutrients*, 2019; 11(9):2147-2157.
- [20] Das R, Kasoju N, Bora U Encapsulation of curcumin in alginate-chitosan-pluronic composite nanoparticles for delivery to cancer cells. *Nanomedicine: Nanotechnology, Biology and Medicine*, 2010; 6(1):153-160.
- [21] Gera M, Sharma N, Ghosh M, Huynh D, Lee S, Min T, Jeong D. Nanoformulations of curcumin: an emerging paradigm for improved remedial application. *Oncotarget*, 2017; 8(39): 66680-66690.
- [22] Hadidi M, Pouramin S, Adinepour F, Haghani S, Jafari S. Chitosan nanoparticles loaded with clove essential oil: characterization, antioxidant

- and antibacterial activities. *Carbohydrate polymers*, 2020; 236:116075-116085.
- [23] Kravanja G, Primožič M, Knez, Ž, Leitgeb M. Chitosan-based (Nano) materials for novel biomedical applications. *Molecules*, 2019; 24(10): 1960-1970.
- [24] Bai K, Hong B, He J, Huang W. Antioxidant capacity and hepatoprotective role of chitosan-stabilized selenium nanoparticles in concanavalin a-induced liver injury in mice. *Nutrients*, 2020; 12(3):857-867.
- [25] Darwesh O, Sultan Y, Seif M, Marrez D. Bio-evaluation of crustacean and fungal nano-chitosan for applying as food ingredient. *Toxicology Reports*, 2018; 5: 348-356.
- [26] Elchinger P, Delattre C, Faure S, Roy O, Badel S, Bernardi T, Taillefumier C. Antioxidant activities of Peptoid-grafted chitosan films. *Applied Biochemistry and Biotechnology*, 2017; 181(1): 283-293.
- [27] Ivanova D, Yaneva Z. Antioxidant properties and redox-modulating activity of chitosan and its derivatives: Biomaterials with application in cancer therapy. *BioResearch open access*, 2020; 9(1): 64-72.
- [28] Chang S, Wu C, Tsai G. Effects of chitosan molecular weight on its antioxidant and antimutagenic properties. *Carbohydrate polymers*, 2018; 181:1026-1032.
- [29] Lee D, Shirley S, Lockey R, Mohapatra S. Thiolated chitosan nanoparticles enhance anti-inflammatory effects of intranasally delivered theophylline. *Respiratory Research*, 2006; 7(1):1-10.
- [30] Dragostin O, Tatia R, Samal S, Oancea A, Zamfir A, Dragostin I, Zamfir C. Designing of Chitosan Derivatives Nanoparticles with Antiangiogenic Effect for Cancer Therapy. *Nanomaterials*, 2020; 10(4): 698-702.
- [31] Haytham EL S A EL S, Lotfy EL S M, Tamer M Abo E, Rania A G. Effect of Carbon Tetrachloride (CCL4) on the liver in Adult Albino Rats: Histological study. *The Egyptian Journal of Hospital Medicine*, 2019; 76 (6): 4254-4261
- [32] Mirza A M, Sharafaldin Al-M, Majid P, Mahdi F, Kazem A, Hajar R, Zuhair M H, Mahdi K, Reza M. 2014 Curcumin-loaded Chitosan Tripolyphosphate Nanoparticles as a safe, natural, and effective antibiotic inhibits the infection of *Staphylococcus aureus* and *Pseudomonas aeruginosa* in vivo. *Iran J Biotech*. 2014;12(3): e1012
- [33] Suryani M, Ismail H. Preparation of curcumin nanoparticles and cellular uptake study on HeLa cells. In *International Conference on Latest Trends in Food, Biological & Ecological Science Proceeding*, 2015; 13-17.
- [34] Duse L, Baghdan E, Pinnapireddy S, Engelhardt K, Jedelská J, Schaefer J, Bakowsky U. Preparation and characterization of curcumin-loaded chitosan nanoparticles for photodynamic therapy. *Physica status solidi*, 2018; 215(15): 1700709-1700719.
- [35] Ali I, Ibrahim M. Malathion induced testicular toxicity and oxidative damage in male mice: The protective effect of curcumin. *Egyptian Journal of Forensic Science*, 2018; 8 (70):13-13.
- [36] Mohammed E, Nadia M, El-Hussieny E, Eman E, Hassan M, Zoheiry M. Effects of free and nanoparticulate curcumin on chemically induced liver carcinoma in an animal model. *Archives of Medical Science*, 2021;17(1):218-229.
- [37] Pant N, Srivastava S. Testicular and spermatotoxic effects of quinalphos in rats. *Journal of Applied Toxicology: An International Journal*, 2003; 23(4): 271-274..
- [38] Hashem A. Defensive impact of propolis against Carbon tetrachloride actuated rats' testicular damage. *Journal of Advanced Veterinary and Animal Research*, 2021 8(1): 70-77.
- [39] Heger, M, van Golen R, Broekgaarden M, Michel M. The molecular basis for the pharmacokinetics and pharmacodynamics of curcumin and its metabolites in relation to cancer. *Pharmacological Reviews*, 2014; 66(1): 222-307.
- [40] Yang D, Kim H, Park K, Kim J, Chun H. Preparation of poly-l-lysine-based nanoparticles with pH-sensitive release of curcumin for targeted imaging and therapy of liver cancer in vitro and in vivo. *Drug Delivery*, 2018; 25(1): 950-960.
- [41] Lammers T, Hennink W, Storm G. Tumour-targeted nanomedicines: principles and practice. *British journal of cancer*, 2008; 99(3): 392-397.
- [42] Iwai M, Morikawa T, Muramatsu A, Tanaka S, Mori T, Harada Y, Ishii M. Biological significance of AFP expression in liver injury induced by Carbon tetrachloride. *Acta Histochemica et Cytochemica*, 2000; 33(1): 17-22.
- [43] Oliveira H, Spanò M, Guevara M, Santos T, Santos C. de Lourdes Pereira M. Evaluation of in vivo reproductive toxicity of potassium chromate in male mice. *Experimental and Toxicologic Pathology*, 2010; 62(4): 391-404.

- [44] Fidan A, Dündar Y. The effects of *Yucca schidigera* and *Quillaja saponaria* on DNA damage, protein oxidation, lipid peroxidation, and some biochemical parameters in streptozotocin-induced diabetic rats. *Journal of Diabetes and its Complications*, 2008; 22(5), 348-356.
- [45] Qian Z, Jung W, Byun H, Kim S. Protective effect of an antioxidative peptide purified from gastrointestinal digests of oyster, *Crassostrea gigas* against free radical induced DNA damage. *Bioresource technology*, 2008; 99(9): 3365-3371.
- [46] Maneesh M, Jayalekshmi H. Role of reactive oxygen species and antioxidants on pathophysiology of male reproduction. *Indian Journal of Clinical Biochemistry*, 2006; 21(2): 80-89.
- [47] Grigorov B. Reactive oxygen species and their relation to carcinogenesis. *Trakia Journal of Sciences*, 2012; 10(3):83-92.
- [48] Yadav A, Flora S, Kushwaha P. Nanocurcumin prevents oxidative stress induced following arsenic and fluoride co-exposure in rats. *Def Life Sciences Journal*, 2016; 1(1): 69-77.
- [49] Elmi T, Esboei B, Sadeghi F, Zamani Z, Didehdar M, Fakhar M, Tabatabaie F. In Vitro Antiprotozoal Effects of Nano-chitosan on *Plasmodium falciparum*, *Giardia lamblia* and *Trichomonas vaginalis*. *Acta Parasitologica*, 2021, 66(1): 39-52.
- [50] El-Rahman S, Al-Jameel S. Protection of curcumin and curcumin nanoparticles against cisplatin-induced nephrotoxicity in male rats. *Sch. Acad. J. Biosci*, 2014; 2: 214-223.
- [51] Ansar S, Farhat S, Albati A, Abudawood M, Hamed S. Effect of curcumin and curcumin nanoparticles against lead-induced nephrotoxicity. *Biomedical Research* 2019; 30(1):938-970.
- [52] Abdel-Wahhab M, Aljawish A, El-Nekeety A, Abdel-Aziem S, Hassan N S. Chitosan nanoparticles plus quercetin suppress the oxidative stress, modulate DNA fragmentation and gene expression in the kidney of rats fed ochratoxin A-contaminated diet. *Food and Chemical Toxicology*, 2017; 99: 209-221.
- [53] Ahmed-Farid O, Nasr M, Ahmed R, Bakeer R. Beneficial effects of curcumin nano-emulsion on spermatogenesis and reproductive performance in male rats under protein deficient diet model: enhancement of sperm motility, conservancy of testicular tissue integrity, cell energy and seminal plasma amino acids content. *Journal of Biomedical Science*, 2017; 24(1): 1-14.

- [54] Sudjarwo S, Anwar C, Wardani G, Eraiko K. Antioxidant and anti-caspase 3 effect of chitosan-*Pinus merkusii* extract nanoparticle against lead acetate-induced testicular toxicity in rat. *Asian Pacific Journal of Reproduction*, 2019; 8(1):13-23.

الدور المحتمل لجسيمات الكيركومين-الشيتوزان النانومترية في الحد من التأثير الضار لرابع كلوريد الكربون على نسيج الخصية بنموذج التليف الكبدى

فاطمة الشربيني⁽¹⁾، نهال أبوالنجا⁽¹⁾، أسماء عبدالعزيز⁽¹⁾،
نعمات أحمد⁽²⁾

1. قسم علم الحيوان، كلية العلوم (بنات)، جامعة الأزهر، القاهرة، مصر
2. قسم البيولوجيا الإشعاعية، المركز القومي لبحوث وتكنولوجيا الإشعاع (NCRRT)، هيئة الطاقة الذرية المصرية، القاهرة، مصر.

الملخص

يهدف هذا العمل إلى فحص التأثير الوقائي لمكملات خليط من الكركمين والكيتوزان النانومترية كمضاد لسمية رابع كلوريد الكربون (نموذج للتليف الكبدى بالفئران) الذي يسبب ضعف نسيج الخصية بالفئران. تم تقسيم الفئران (25 جرام) إلى أربع مجموعات. مجموعة التحكم العادية ومجموعة محقونة برابع كلوريد الكربون ومجموعة الوقاية ومجموعة العلاج التليف الكبدى. تم حقن الفئران في التجريف البطنى برابع كلوريد الكربون ثلاث مرات في الأسبوع لمدة 4 أسابيع بجرعة 0.5 مقدارها مل / كجم من وزن الجسم للحث على الإصاية بالتليف الكبدى. و تم إعطاء الفئران عن طريق الفم خليط من مكملات الكركمين والكيتوزان النانومترية (100 مجم: 100 مجم) / 1 كجم من وزن الجسم 5 مرات في الأسبوع لمدة 4 أسابيع كطريقة للوقاية والعلاج من التليف الكبدى. تم تسجيل كل من التحليل الفسيولوجي والكيميائي الحيوي وأوزان الخصية والجسم وتركيز السائل المنوي. أظهرت النتائج ان الحقن برابع كلوريد الكربون أدى الى وجود ألياف الكولاجين واسعة النطاق داخل وحول مناطق البوابة في أنسجة الكبد وضمور الأنابيب المنوية وتعطل الغشاء القاعدي وانخفاض عدد الحيوانات المنوية وانخفاض وزن الخصية في الجهاز التناسلي الذكري ووزن الجسم بالفئران. اتضح تحسن الفحص النسيجي لكل من الكبد والخصية وعدد الحيوانات المنوية والحالة المؤكسدة في المجموعات المعالجة بجسيمات الكركمين والكيتوزان النانومترية مقارنة بالمجموعات مجموعة التحكم العادية والمجموعة المحقونة برابع كلوريد الكربون وفي الختام امكان تناول مكملات خليط من الكركمين والكيتوزان النانومتري منع وعلاج المضاعفات المحدثة بالخصية في الفئران المعالجة رابع كلوريد الكربون (نموذج للتليف الكبدى بالفئران).