



## Annual Research & Review in Biology

19(2): 1-17, 2017; Article no.ARRB.35608  
ISSN: 2347-565X, NLM ID: 101632869

# Evaluation of the Protective Effect of *Acacia senegal* Extract against di-(2-ethylhexyl phthalate) Induced Hepato- and Neurotoxicity in Rats

Mohamed Mahmoud Seif<sup>1#</sup>, Omar Abdel-Hamed Ahmed-Farid<sup>2</sup>  
and Wael Mahmoud Aboulthana<sup>3\*#</sup>

<sup>1</sup>Toxicology and Food contaminants Department, Food Industry and Nutrition Division, National Research Center, 33 Bohouth St., P.O. 12622, Dokki, Giza, Egypt.

<sup>2</sup>Department of Physiology, National Organization for Drug Control and Research, Giza, Egypt.

<sup>3</sup>Biochemistry Department, Genetic Engineering and Biotechnology Division, National Research Centre, 33 Bohouth St., P.O. 12622, Dokki, Giza, Egypt.

### Authors' contributions

This work was carried out in collaboration between all authors. All authors read and approved the final manuscript.

### Article Information

DOI: 10.9734/ARRB/2017/35608

#### Editor(s):

- (1) Viduranga Y. Waisundara, Faculty of Applied Sciences, Rajarata University of Sri Lanka, Mihintale, Sri Lanka.  
(2) George Perry, Dean and Professor of Biology, University of Texas at San Antonio, USA.

#### Reviewers:

- (1) Guadalupe Muñoz-Arenas, Benemérita Universidad Autónoma de Puebla, Mexico.  
(2) Arti Gupta, Uka Tarsadia University, India.  
(3) Martin Potgieter, University of Limpopo, South Africa.

Complete Peer review History: <http://www.sciencedomain.org/review-history/21758>

Original Research Article

Received 21<sup>st</sup> July 2017  
Accepted 30<sup>th</sup> October 2017  
Published 6<sup>th</sup> November 2017

## ABSTRACT

Di-(2-Ethylhexyl phthalate) (DEHP) is an aromatic diester used to improve plasticity of industrial polymers. It exhibited adverse changes in both liver and brain. The current study was planned to evaluate efficiency of *Acacia senegal* extract to ameliorate against liver and brain toxicity induced by DEHP. In this study, markers of the serum hepatic functions were elevated significantly ( $P < 0.05$ ) in the DEHP-treated group. In coincide with these results, the antioxidant enzymes declined significantly ( $P < 0.05$ ) associated with elevation of the lipid peroxidation product (LPO) in liver of DEHP-treated group. Furthermore, DEHP caused decline in activity of the antioxidant enzymes associated with elevation of LPO level in brain tissue. In consistent with these results, DEHP

\*Corresponding author: E-mail: [wmkamel83@hotmail.com](mailto:wmkamel83@hotmail.com), [wmkamel83@gmail.com](mailto:wmkamel83@gmail.com);

#Affiliation ID: 60014618

caused elevation of excitatory amino acids with decrease of inhibitory amino acids and monoamines in that tissue. *A. senegal* extract showed ameliorative effect by restoring activities of the antioxidant enzymes to normalcy with reducing the LPO level in the both tissues. The electrophoretic protein and lipoprotein patterns in liver tissue presented that the lowest similarity index (SI) values were noticed in the DEHP-treated group (66.67 and 71.43%, respectively). No changes detected in protein and lipoprotein patterns in brain tissue. DEHP caused electrophoretic quantitative mutagenicity by increasing quantity of the  $\alpha$ -EST2 band in liver tissue. As regards  $\beta$ -EST enzyme in liver and brain tissues, DEHP caused qualitative mutagenicity leading to decreasing the SI % in liver and brain tissue (66.67 and 25%, respectively). Moreover, it induced cleavage of the genomic DNA in both tissues. *A. Senegal* extract increased the SI values by restoring the normal bands and hiding the abnormal ones and maintained integrity of the genomic DNA pattern in liver tissue.

**Keywords:** Di-(2-Ethylhexyl phthalate); *Acacia Senegal*; electrophoresis; protein; esterases; genomic DNA.

## 1. INTRODUCTION

Phthalates are consisting of alkyl or dialkyl esters of phthalic acid (benzene dicarboxylic acid). They are metabolized into tomonophthalate by lipases or esterases in the intestines; monophthalate is degraded into oxidative metabolites. The monoesters are generally considered to be responsible for the general toxic effects [1]. Di-(2-Ethylhexyl phthalate) (DEHP) is an aromatic diester that used as plasticizer in polyvinyl chloride (PVC) resins for fabricating flexible vinyl products [2]. It is well known that the DEHP belongs to the peroxisome proliferator compounds which normally found in food packed from plastic materials. These compounds have been known to changes in metabolic pathways and subsequently induce liver enlargement [3].

It is a lipophilic compound that can be absorbed through skin and lungs by both humans and rodents. The general population is susceptible to be exposed to DEHP mainly through oral rout [4]. Dietary exposure to DEHP occurs through migration of the plasticizer from food packaging and from the environment where it exists as a contaminant in drinking water and aquatic food. Fatty foods such as milk, butter and meats are a major source. Because phthalate plasticizers are not chemically bound to PVC, they can easily leach and evaporate into food or the atmosphere. Moreover, low-molecular-weight phthalate esters, including DEHP are used to make coatings for oral medications [5]. DEHP is a well-known hepatotoxin as it stimulates proliferation of the hepatic peroxisomes and produce liver hypertrophy, hyperplasia and tumors. It causes induction of lipid metabolizing enzymes in the liver [6]. Also, it is shown to be hepatocarcinogenic causing hepatocellular

carcinomas and adenomas. The incidence of hepatocellular carcinoma is a DEHP dose dependent. DEHP and its metabolites are suspected of producing neurotoxicity and endocrine-disrupting effects [7].

Esterases catalyze the hydrolysis of ester bonds of various compounds (i.e., lipids, oils, and phthalates) and break them down into the corresponding carboxylic acids. The initial step in the degradation of phthalate esters seems to be a de-esterification reaction by specific esterases, to give rise to phthalate anions and alcohol [1,8]. DEHP is able to inhibit acetylcholinesterase activity and up-regulated transcripts of growth associated protein [9]. Moreover, it exhibits adverse effects on the behavior and brain-derived neurotrophic factor of rats. Therefore, DEHP endocrine disruptors may also contribute neurodevelopmental disorders such as disturbances of the neurotransmitters excitatory and inhibitory amino acids that subsequently lead to attention-deficit hyperactivity disorder and autism [10]. For this reason, the present study aims to reveal the deleterious effect of DEHP on both of liver and brains tissues.

The previous published researches emphasize that *Acacia* species exhibit various biological activities including antioxidant potential, anti-inflammatory, antitumor and neuronprotective [11]. *Acacia senegal*, commonly known as Gum Arabica, is a drought or arid region tree. It is a native of Africa and is also found in the Indian subcontinent and Pakistan. Official parts of *A. senegal* such as gum, seeds, fruits, leaves and bark are considered as the richest resources of bioactive tannins, flavonoids, phenolics, alkaloids, saponins, polysaccharides and terpenoids [12,13]. It is postulated that *Acacia senegal* gum is used for soothing mucous

membranes of the intestine and to cure bleeding, bronchitis, diarrhea, malaria, typhoid fever and respiratory tract infections besides possessing antiplatelet and antifertility activities [14]. *A. Senegal* gum contains neutral sugars (rhamnose, arabinose and galactose), acids (glucuronic acid and 4-methoxyglucuronic acid) and minerals (calcium, magnesium, potassium and sodium) [15]. Furthermore, it is rich in various effective phytoconstituents that are represented by flavone, catechin, polyphenols, tannins, chalcones, alkaloids and flavonoids [16]. It exhibited various pharmacological activities represented by the protection against cyclophosphamide induced urinary bladder cytotoxicity [17], limitation of the hepatotoxicity induced by acetaminophen [18] and antidiabetic activity against streptozotocin induced diabetes in rats [19]. The present study is planned to explore the possible ameliorative or therapeutic effect of *A. senegal* extract against liver and brain toxicity induced by DEHP.

## 2. MATERIALS AND METHODS

### 2.1 Extract Preparation

Plant material of matured *Acacia senegal* pod with seeds was purchased from Khedr El Attar, Khan El Khalili, Cairo, Egypt. It was oven dried and subjected to mechanical size reduction. As documented by Kannan et al. [20], the powdered material was soaked for one week at room temperature in ethanol (70%) at the concentration 10% (W/V). On the 7<sup>th</sup> day, extraction was carried out using ultrasonic sound bath accompanied by sonication (40 minutes) and filtered. The solvent was allowed to evaporate and the extract was concentrated by rotary evaporator (Panchun Scientific Co.) at 35°C. The gummy extract was freeze dried for further use.

### 2.2 Treatment Dose

Based on the results obtained by Meena et al. [21] and supported by Singh et al. [22] who reported that no deaths or adverse effects were detected during the 24-hour observation period in mice treated with up to 3000 mg/kg.bw. The dose at the concentration of 300 mg/kg.bw was chosen for the therapeutic application during the experiment.

### 2.3 Ethics Statement

The experimental design and animal handling were carried out according to experimental

protocol approved by Institutional Animal Ethics Committee of National Research Centre, Dokki, Giza, Egypt (No: 471/2016). Moreover, it was conducted in accordance with guidelines as per "Guide for the care and use of laboratory animal" and with permission from Committee for the Purpose of Control and Supervision of Experiments on Animals. Every effort was done to minimize the number of animals and their suffering.

### 2.4 Experimental Design

Healthy thirty six adult male rats (*Sprague Dawley*) of initial weights  $200 \pm 20$  g (9-12 weeks old) were housed in filter top polycarbonate cages. The animals were interned for 28 days and provided with water *ad libitum* and standard food and maintained under normal environmental conditions at  $25 \pm 2^\circ\text{C}$ . After an acclimatization period of 1 week, animals were equally divided into six groups (6 rats in each). Group I (Control group): Rats were fed with normal diet as *ad libitum* and received corn oil alone as vehicle for the extract via gavage for concessive 28 days. Group II (DEHP-treated group): Rats were fed with normal diet associated with the treatment orally with DEHP (1000mg / Kg bw) via gavage for concessive 28 days. The DEHP dose was selected according to Jain et al. [23]. Group III (*A. senegal* extract post-treated group): Rats received DEHP for the 14 day orally for 14 days followed by oral administration of *acacia* gum extract for another 14 days. Group IV (*A. senegal* extract simultaneous treated group): Rats received DEHP and treated orally with *acacia* gum extract at the same time and continue daily for 28 consecutive days via gavages. Group V (*A. senegal* extract treated group): Rats were fed with normal diet associated with the treatment orally with *acacia* gum extract (300mg / Kg) by stomach tube for concessive 28 days. Group VI (*A. senegal* extract pre-treated group): Rats received *acacia* gum extract orally for 14 days followed by DEHP for another 14 days.

### 2.5 Samples Collection

One day after the end of experimental period (i.e., on 29<sup>th</sup> day), all animals were fasted for 12 h. The animals were anesthetized through slight exposure to diethyl ether. The blood samples which were drawn by retro orbital puncture. The blood samples were allowed for clotting at room temperature and then centrifuged at 3000 rpm for 15 min; the serum was separated and kept in clean stoppered vials at  $-20^\circ\text{C}$  until the

biochemical assay. The animals were sacrificed by cervical dislocation. Liver and brain tissues were dissected out on ice quickly, cleaned and washed in ice-cold saline then homogenized in 0.01 M Tris-HCl buffer (pH 7.4). Aliquots of this homogenate were used for measuring markers of the oxidative stress and for the different electrophoretic patterns. Also, another brain tissue was homogenized in methanol (75%) in an ice jacket followed by deproteinization then centrifuged in cooling centrifuge at 4°C for 20 min at 5000 rpm for amino acids analysis.

## **2.6 Biochemical Analysis**

### **2.6.1 Liver functions**

Hepatic dysfunction was assessed by measuring activity of liver enzymes such as alanine aminotransferase (ALT), aspartate aminotransferase (AST) [24], alkaline phosphatase (ALP) [25] and acetylcholinesterase (AChE) [26] in serum samples using commercially available kits based on referenced methods.

### **2.6.2 Oxidative stress markers**

The lipid peroxidation (LPO) product was assayed in liver and brain tissue homogenates by spectrophotometric method [27] using a UV-Vis spectrophotometer (Shimadzu uv-2401 pc). Furthermore, the total antioxidant capacity (TAC) was estimated in these tissues by colorimetric method [28], which is based on capacity of the sample to inhibit production of thiobarbituric acid reactive substances from sodium benzoate under the influence of the free oxygen radicals. The antioxidant enzymes such as superoxide dismutase (SOD) [29], catalase (CAT) [30] and glutathione peroxidase activity (Gpx) [31] were measured in liver tissue homogenates.

### **2.6.3 Brain amino acids and monoamines**

Specimen of each brain tissue was weighed and homogenized in 75% aqueous HPLC grade methanol. The homogenate was spun at 4000 rpm for 10 min. and the supernatant was divided into two equal portions; the first one was dried at room temperature using vacuum (70 Millipore) and used for determination of excitatory (Aspartic (ASP) and Glutamic (GLU) and inhibitory amino acids (GABA and Glycine (GLY)) according to method described by Heinrichson and Meredith [32] who used High Performance Liquid

Chromatography (HPLC) equipped with the precolumn PITC derivatization technique. Whereas, the second portion was used for determination of brain monoamines (Noradrenalin (NE), dopamine (DA), serotonin (5HT)) and their metabolites (DOPAC, HVA and 5HIAA) by HPLC according to method suggested by Pagel et al. [33]. The resulting chromatogram identified each monoamine position and their metabolites concentration from the sample with respect to that of the standard.

## **2.7 Statistical Analysis**

Significant difference between groups were assessed by one way analysis of variance (one-way ANOVA) followed by least significant difference (LSD) test and confirmed by Bonferroni test to compare the significance among the rat groups. A "P" value of less than 0.05 was considered to indicate statistical significance.

## **2.8 Histopathological Examination**

After sacrifice, autopsy specimens were taken from liver tissues of different experimental groups and immediately fixed in 10% formal saline solution for 24 hr. The tissues were washed in tap water then dehydrated in serial dilutions of alcohol solutions. Tissue fragments were then cleared in xylene and embedded in paraffin and used for histopathological examination. Paraffin bees wax tissue blocks were prepared for sectioning at 4 microns thickness by sledge microtome. The tissue sections were collected on glass slides and deparaffinized then stained by hematoxylin and eosin (H&E) stain for examination through the light electric microscope [34].

## **2.9 Samples Preparation**

The tissues (liver and brain) were rapidly frozen with liquid nitrogen and ground then homogenized in water-soluble extraction buffer (0.2 mg / ml). The homogenates were centrifuged at 10,000 rpm for 10 min. The clear supernatant containing water-soluble proteins was transferred to new eppendorf tubes. Individual samples of each group were pooled together and used as one sample and protein concentration was estimated in all pooled samples according to method described by Bradford [35] using bovine serum albumin as standard.

## 2.10 Electrophoretic Protein and Lipoprotein Patterns

The polyacrylamide gel electrophoresis (PAGE) was carried out at the concentration 10% according to protocol documented by Laemmli [36] using Mini-gel electrophoresis (BioRad, USA). The native and denaturing gels were stained Coomassie Brilliant Blue G-250 for visualizing the protein bands [37]. The relative mobility (Rf), band intensity (Int) and quantity (Qty) of the electrophoretically separated proteins were determined in addition to the molecular weight (Mwt) which was estimated in comparison to marker of standard molecular weights with regularly spaced bands ranging from 6.458 to 195.755 KDa. Moreover, the gel was stained for lipoprotein pattern by Sudan Black B (SBB) [38].

## 2.11 Electrophoretic Localization of In-gel Enzyme Activity

The native gel was processed for localization of in-gel  $\alpha$ - and  $\beta$ -esterase (EST) activities according to method modified recently by Ahmad et al. [39] who postulated that the gel was incubated in reaction mixture containing  $\alpha$ ,  $\beta$ -naphthyl acetate ( $5.58 \times 10^{-3}$  mM, pH 7.5) as substrates along with dye coupler Fast Blue RR.

## 2.12 Genomic DNA Pattern

The genomic DNA was extracted from liver and brain tissues according protocol suggested by Barker et al. [40]. Purity and concentration of the genomic DNA were determined spectrophotometrically using a UV-Vis spectrophotometer (Shimadzu uv-2401 pc). Absorbance was measured at wavelengths of 260 and 280 ( $A_{260}$  and  $A_{280}$ , respectively) nm. The absorbance quotient ( $OD_{260}/OD_{280}$ ) provides an estimate of DNA purity. An absorbance quotient value of  $1.8 < \text{ratio (R)} < 2.0$  was considered to be good and accepted, purified DNA. A ratio of  $<1.8$  is indicative of protein contamination, where as a ratio of  $>2.0$  indicates RNA contamination. Integrity of the genomic DNA was assayed using gel electrophoresis (Bio-Rad, USA) by resolving DNA extracts on a 1.5% agarose containing ethidium bromide. The DNA bands were visualized on a UV transilluminator and photographed by Gel Documentation System then analyzed in comparison to DNA molecular weight marker

(HyperLadder II) with regularly spaced bands ranging from 50 bp to 2000 bp.

## 2.13 Data Analysis

The bands in polyacrylamide gel and the DNA fragments in agarose gel were analyzed using Quantity One software (Version 4.6.2). Percent of the similarity index (SI %) was calculated according to formula suggested by Nei and Li [41] to compare all treated groups to control group.

## 3. RESULTS AND DISCUSSION

Liver is a more sensitive target for DEHP exposure [42]. It is a major organ that is susceptible to be attacked by reactive oxygen species (ROS) [43]. The antioxidant system is required to be developed for maintaining the redox homeostasis in the liver. When the ROS produced in excessive rate, the homeostasis will be disturbed resulting in oxidative stress. Subsequently, this leads to liver injury and other chronic and degenerative disorders [44]. ALT activity is an important index to measure degree of cell membrane damage, while AST is an indicator of mitochondrial damage since it contains 80% of this enzyme [45]. Activity of AChE used as an indicator of liver function. Its activity falls in catabolism and rises in anabolism. Its activity altered in case of hepatocellular lesions [46]. Elevated levels of serum enzymes are considered as indicators of cellular leakage and loss of functional integrity of the cell membrane in liver [47]. As presented in Table 1, levels of hepatic markers (AST, ALT, ALP and AChE) were found to be significantly ( $P < 0.05$ ) elevated in the DEHP-treated group. This was in a consistent with results obtained by Barse et al. [48] who reported that the elevated levels of these markers in sera of DEHP-treated rats correspond to extensive hepatocellular damage and hence release of these in the blood circulation. As compared to DEHP-treated group, *A. senegal* extract decreased the hepatic markers significantly ( $P < 0.05$ ) and restored its levels to normalcy except in *A. senegal* extract pre-treated group (GVI). This might be attributed to presence of the higher flavonoid constituents that possess antioxidant properties and was found to be useful in treatment of liver damage. The flavonoids exhibited hepatoprotective activity through free radical scavenging property and its efficiency to inhibit the peroxidation reaction [49].

**Table 1. Prophylactic and therapeutic effect of acacia extract on levels of hepatic markers against liver toxicity induced by DEHP in rats**

	GI	GII	GIII	GIV	GV	GVI
ALT (U/L)	32.1±0.8	82±0.4 <sup>a</sup>	35±0.8 <sup>b</sup>	35±0.6 <sup>b</sup>	34.4±1.0 <sup>b</sup>	76.6±0.6 <sup>a</sup>
AST (U/L)	38.7±0.6	86.3±0.9 <sup>a</sup>	38.9±1.5 <sup>b</sup>	38.9±0.8 <sup>b</sup>	40.05±0.4 <sup>b</sup>	74.6±0.8 <sup>a</sup>
ALP (U/L)	52.5±0.6	87.7±0.8 <sup>a</sup>	54.5±1.4 <sup>b</sup>	54.5±0.9 <sup>b</sup>	53±1.3 <sup>b</sup>	86.3±0.9 <sup>a</sup>
AChE (U/L)	38.5±2.9	89.1±1.0 <sup>a</sup>	38.7±1.8 <sup>b</sup>	38.7±0.7 <sup>b</sup>	38.5±2.3 <sup>b</sup>	66.4±0.7 <sup>a</sup>

Values are expressed as mean ± SE for 6 rats /group. a: significant difference from GI group at  $P < 0.05$ , b: significant difference from GII at  $P < 0.05$ .

Group I: Control group; Group II: DEHP-treated group; Group III: *A. senegal* extract post-treated group; Group IV: *A. senegal* extract simultaneous treated group; Group V: *A. senegal* extract treated group; Group VI: *A. senegal* extract pre-treated group

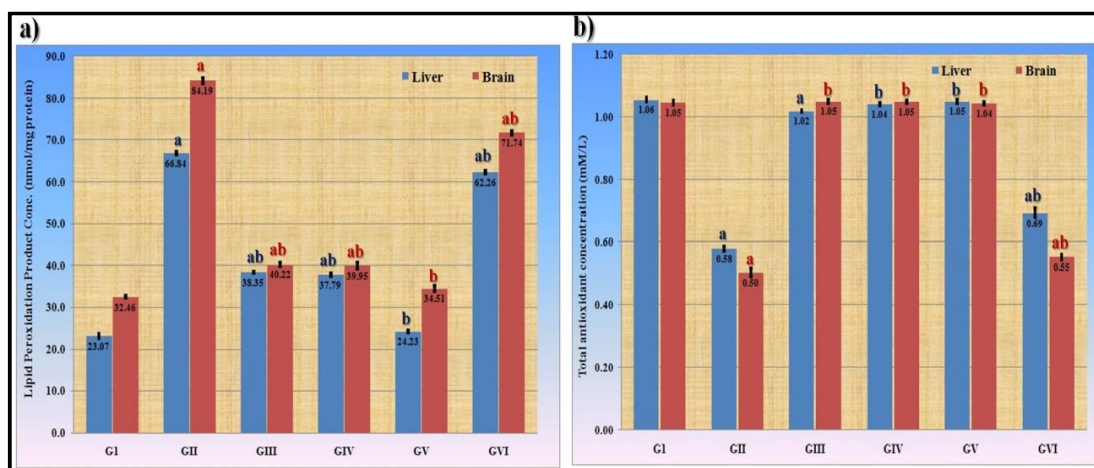
The LPO produced as a result of peroxidation of polyunsaturated fatty acids in the biological membrane. The LPO level is a measure of alterations and damage in structure of cellular membranes [50]. As revealed in Table 2, activities of enzymatic antioxidants (SOD, CAT and Gpx) decline significantly ( $P < 0.05$ ) in liver tissue of DEHP-treated group. Furthermore, Fig. 1 illustrated that DEHP caused significant ( $P < 0.05$ ) decline in TAC level associated with elevation of LPO level in that tissue. The increased LPO level associated with lowering the TAC level in liver of DEHP-treated group might be attributable to the failure to prevent formation of excess free radicals in a concomitant decline in activities of antioxidant enzymes in liver [20,23]. All these data revealed that DEHP increased oxidative stress through disturbance of cellular redox systems in rat liver [51]. In parallel to results of hepatic markers, *A. senegal* extract elevated levels of antioxidants with lowering the LPO level in all *A. senegal* extract treated groups except GVI with respect to the DEHP-treated group.

As illustrated histopathologically in Fig. 2, DEHP caused irreversible histopathological changes in liver tissue represented by infiltration in bands of fibrosis and inflammatory cells in the portal areas all over the parenchyma associated with dilatation in the congested portal vein. This was in a consistent with results of oxidative stress markers. These alterations might refer to disturbances in the redox system and the oxidative activity of DEHP with subsequent generation of superoxide anion stimulating the peroxidation process. The lipid peroxides accumulate in addition to production of nitric oxide leading to toxic disintegration of cellular organelles and alteration of membrane permeability with subsequent hepatocytes edema and vascular dilatation [6,52]. This was in consistent to results of liver functions and

markers of the oxidative stress. *A. senegal* extract significantly reversed these changes in rats of GIII and GIV groups, while the GVI group showed no LPO restoration. Generally, the body exhibits the ability to neutralize or prevent the toxicity produced by free radicals by using endogenous antioxidant enzymes through an effective defense mechanism. The balance between ROS generation and antioxidant defense mechanism may be lost in DEHP-induced hepatotoxicity as mentioned by Jain et al. [23].

As compared to healthy liver (GI), *A. senegal* extract lowered severity of the histological alterations to the mild stage of congestion of the hepatocytes in lacunae in all *A. senegal* extract treated groups except in *A. senegal* extract pre-treated group (GVI). *A. senegal* extract preserved the antioxidant levels in the GIII and GIV groups. The hepatoprotective effect of *A. senegal* extract was further accomplished by histopathological analysis. Histopathological findings of liver samples were in accordance with the results obtained in biochemical studies, indicating that *A. senegal* extract is able to inhibit DEHP induced hepatotoxicity. This might refer to presence of the phenolics and flavonoids (For example, polyphenolic compound Kaempferol, gallic acid, catechin and umbelliferone) which displayed potential scavenging efficiency against different species of free radicals and play an essential role in preventing oxidative stress [22,53].

It was emphasized that DEHP exerted significant ( $P < 0.05$ ) elevation in the LPO level associated with lowering in the TAC level in brain tissue (Fig. 1). The treatment with *A. senegal* extract lowered the LPO level with restoring the TAC level in all extract treated groups significantly ( $P < 0.05$ ) with respect to DEHP-treated group (GII). As illustrated in Table 3, it was noticed that DEHP



**Fig. 1. Prophylactic and therapeutic effect of acacia extract against liver and brain toxicity induced by DEHP on a) lipid peroxidation (LPO) product and b) total antioxidant capacity (TAC) in rats. Values inside column are expressed as mean. a shows the significance ( $p < 0.05$ ) in comparison to the G1 group and b shows the significance ( $p < 0.05$ ) in comparison to GII group**

Group I: Control group; Group II: DEHP-treated group; Group III: *A. senegal* extract post-treated group; Group IV: *A. senegal* extract simultaneous treated group; Group V: *A. senegal* extract treated group; Group VI: *A. senegal* extract pre-treated group

**Table 2. Prophylactic and therapeutic effect of acacia extract on activities of enzymatic antioxidants against liver toxicity induced by DEHP in rats**

	G1	GII	GIII	GIV	GV	GVI
SOD (U/mg protein)	8.31±0.2	5.36±0.1 <sup>a</sup>	8.11±0.1 <sup>b</sup>	7.96±0.1 <sup>b</sup>	8.51±0.2 <sup>b</sup>	5.6±0.1 <sup>a</sup>
CAT (μmol/min/mg protein)	21.8±0.17	9.02±0.3 <sup>a</sup>	20.8±0.7 <sup>b</sup>	20.8±0.2 <sup>b</sup>	21.0±0.6 <sup>b</sup>	9.6±0.2 <sup>a</sup>
Gpx (μg/mg protein)	15.2±0.2	9.4±0.5 <sup>a</sup>	17.07±0.6 <sup>b</sup>	14.6±0.2 <sup>b</sup>	14.6±0.3 <sup>b</sup>	9.2±0.2 <sup>a</sup>

Values are expressed as mean ± SE for 6 rats /group. a: significant difference from G1 group at  $P < 0.05$ , b: significant difference from GII at  $P < 0.05$ .

Group I: Control group; Group II: DEHP-treated group; Group III: *A. senegal* extract post-treated group; Group IV: *A. senegal* extract simultaneous treated group; Group V: *A. senegal* extract treated group; Group VI: *A. senegal* extract pre-treated group

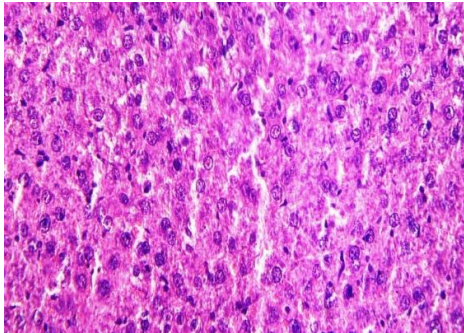
caused significant ( $p < 0.05$ ) elevation of excitatory amino acids (ASP and GLU) associated with decrease inhibitory amino acids (GABA and GLY) in brain tissue. DEHP can pass to brain through the blood barriers due to its chemical structure inducing neurotoxicity by increase excitatory and decrease inhibitory amino acids. In the current study, the excitatory amino acids increased in association with decreasing the inhibitory amino acids. This might occur as a result of neurotoxicity by increase GLU that could be reflecting an alteration of GLU uptake. Moreover, DEHP result in activation of the glutamatergic system and glutamate pathway leading to counter effects on the release of GABA involvement of the  $Ca^{2+}$ -related excitotoxic process, possibly mediated by the N-methyl-D-aspartate subtype of glutamate receptors [54]. N-methyl D-aspartate,  $\alpha$ -amino-3-hydroxy-5-methyl-4-isoxazolepropionic acid and kainate

receptors are the glutamate receptors which activate in case of neurotoxicity. This subsequently leads to increase  $Ca^{+2}$  and  $Na^{+}$  and decrease  $K^{+}$  level in the cell resulting to cellular neuronal death [55]. Additionally, in the present study DEHP caused significant decline in monoamines and their metabolites (DOPAC, HVA and 5HIAA) which declared important pathway implicated to neurotoxicity that mediated by monoamine oxidase. The inhibitory amino acids (GABA and GLY) level in DEHP-treated group was significantly decreased. This may be due to inhibition of GABA synthesis or destruction of GABAergic neurons [56]. *A. senegal* extract showed amelioration effect for brain amino acids in *A. senegal* extract treated groups except *A. senegal* extract post-treated group (GIII) in comparing with DEHP-treated group (GII) and almost recovery in comparing with control (G1) group. On the other hand, GVI

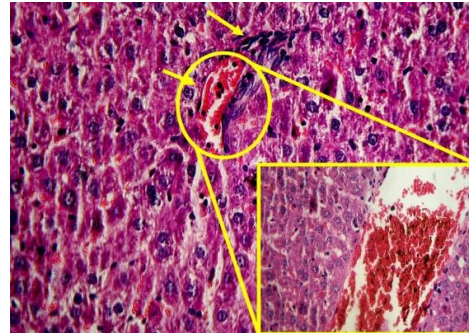


showed slightly amelioration in comparing with GII. *A. senegal* extract simultaneous treated

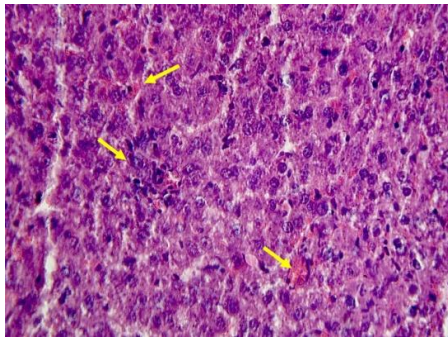
group (GIV) showed no significant changes in comparing with GI.



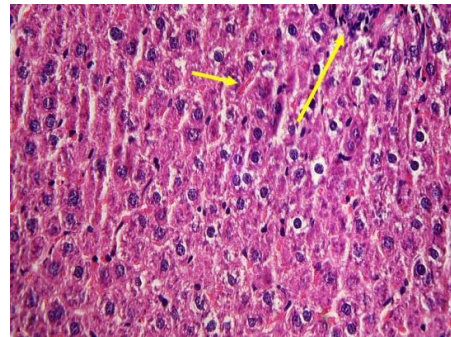
**GI:** Liver section showing no histopathological alteration with normal histological structure of the hepatocytes in the lacunae was recorded (H&E, X 400)



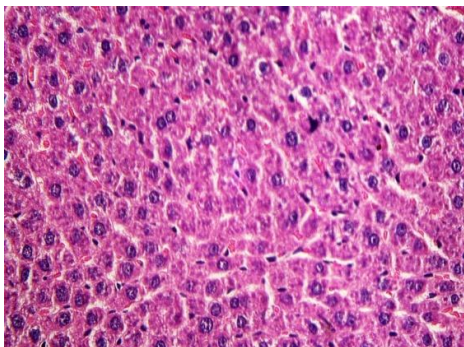
**GII:** Liver section showing dilated congested portal vein with thickened hyalinized wall. In addition, bands of fibrosis and inflammatory cells infiltration were detected in the portal areas all over the parenchyma (H&E, X 400)



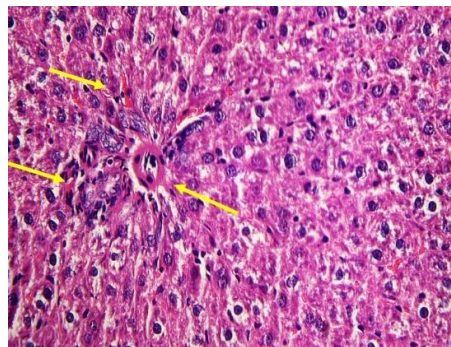
**GIII:** Liver section showing mild congestion of the hepatocytes in the lacunae (H&E, X 400).



**GIV:** Liver section showing mild dilated portal vein with thickened hyalinized wall (H&E, X 400)



**GV:** There was no histopathological alteration and normal histological structure of the hepatocytes in the lacunae (H&E, X 400)



**GVI:** Liver section showing mild dilated congested portal vein and inflammatory cells infiltration in the portal areas all over the parenchyma (H&E, X 400)

**Fig. 2.** Histological examination of liver toxicity induced by DEHP and possible prophylactic or therapeutic role of *acacia* extract

Group I: Control group; Group II: DEHP-treated group; Group III: *A. senegal* extract post-treated group;  
Group IV: *A. senegal* extract simultaneous treated group; Group V: *A. senegal* extract treated group;  
Group VI: *A. senegal* extract pre-treated group



**Table 3. Prophylactic and therapeutic effect of acacia extract on excitatory and inhibitory amino acids against brain toxicity induced by DEHP in rats**

Groups	Amino acids concentration ( $\mu\text{mol/g}$ )			
	ASP	GLU	GABA	GLY
GI	1.13 $\pm$ 0.16	0.96 $\pm$ 0.10	8.34 $\pm$ 0.88	3.79 $\pm$ 0.37
GII	2.23 $\pm$ 0.18 <sup>a</sup>	2.13 $\pm$ 0.37 <sup>a</sup>	4.51 $\pm$ 0.55 <sup>a</sup>	1.77 $\pm$ 0.20 <sup>a</sup>
GIII	2.11 $\pm$ 0.23 <sup>a</sup>	2.08 $\pm$ 0.27 <sup>a</sup>	5.75 $\pm$ 0.46 <sup>ab</sup>	2.08 $\pm$ 0.20 <sup>a</sup>
GIV	1.08 $\pm$ 0.10	1.16 $\pm$ 0.06	8.21 $\pm$ 0.62	3.55 $\pm$ 0.20
GV	1.11 $\pm$ 0.10	0.84 $\pm$ 0.06	7.79 $\pm$ 1.06	3.91 $\pm$ 0.37
GVI	1.58 $\pm$ 0.19 <sup>ab</sup>	0.96 $\pm$ 0.16 <sup>b</sup>	8.24 $\pm$ 0.59 <sup>b</sup>	3.62 $\pm$ 0.45 <sup>ab</sup>

Values are expressed as mean  $\pm$  SE for 6 rats /group. a: significant difference from GI group at  $P < 0.05$ , b: significant difference from GII at  $P < 0.05$ .

Group I: Control group; Group II: DEHP-treated group; Group III: *A. senegal* extract post-treated group; Group IV: *A. senegal* extract simultaneous treated group; Group V: *A. senegal* extract treated group; Group VI: *A. senegal* extract pre-treated group

DEHP caused significant ( $P < 0.05$ ) reduction in monoamines (NE, DA and 5HT) and their metabolites (DOPAC, HVA and 5HIAA) in comparing with control group (GI). As compared to DEHP-treated group, *A. senegal* extract exhibited showed amelioration effect in groups (GIV, GVI) and almost recovery with respect to control (GI) group. On the other hand, GIII showed slightly amelioration in comparing to GII and showed no significant changes in comparing to GI (Table 4). Earlier researches performed by Keddy et al. [57] confirmed the presence of flavonoids, tannins, flavone, catechin, polyphenols and alkaloids in *A. senegal* extract. The flavonoids exert the ability to inhibit the enzymes (kinases and phosphatases) which act as critical proteins for signal transduction pathways to regulate oxidative stress and cell survival [57]. The present results postulated that the *A. senegal* extract has significant neuroprotective and mild treated activity without side effects. This may be probably due to the higher content of tannins and flavonoids that exhibit antioxidant properties through their ability to donate hydrogen and chelate metals [58]. Mean-while, *A. senegal* extract (phenolic acids) in GIV and GVI groups prevented DEHP induced neurotoxicity by lowering ASP and GLU concentration as well as elevation in GABA, GLY and monoamines (norepinephrine, dopamine and serotonin) in rat brain. Our results in line with Radad et al. [59] who explained the neuroprotective effect of Ginsenosides (flavonoids) as a neuroprotective effects on dopaminergic cells stressed with glutamate. Amelioration and neutralization of excitatory, inhibitory amino acids, monoamines and their metabolites due to co or/ pre treatment of *A. senegal* extract near normal group may attributed to the antioxidant capacity for phenolic content

that decrease LPO that the major marker for amino acids and monoamines disrupted in brain rat intoxicated with DEHP. Obtained data were in agreement with Benavente-Garcia et al. [60] who found that flavanoids and catechins are important antioxidants and superoxide scavengers. Their scavenging efficiency depends on the concentration of phenol and the number and location of the hydroxyl groups.

As compared to the corresponding control (Fig. 3a), several protein bands disappeared in DEHP-treated group associated with appearance of one characteristic band (Rf 0.40, Mwt 30.19 KDa, Int 972.08 and Qty 9.61). Moreover, the lowest SI value was noticed in the DEHP-treated group (66.67%). Furthermore, it could be observed that 2 abnormal characteristic lipoprotein bands were identified at Rfs 0.18 (Int. 2295.22 and Qty 7.56) and 0.48 (Int. 2905.98 and Qty 9.57) (Fig. 4a). The lowest SI value was observed in the DEHP-treated group (71.43%) and this was constant with results of the protein pattern. The treatment with *A. senegal* extract increased the SI value by restoring the normal bands and hiding the abnormal bands. On the other hand, the electrophoretic protein and lipoprotein patterns in brain tissue (Fig. 3b and 4b) showed no alterations in number or arrangement of the bands in all treated group with respect to control group (the highest SI value 100%). During the current study, DEHP induced changes in the liver electrophoretic protein pattern. This was in accordance with Watanabe et al. [61] who postulated that phthalate caused quantitative changes in about 12 proteins which are considered as part of the pleiotropic response in rat liver. This might be attributed due to peroxisome proliferation, activation of enzymes in the lipid oxidation metabolic pathway.

Moreover, DEHP caused alterations in the electrophoretic lipoprotein pattern. This might refer to ability of phthalates to alter lipid metabolism through its inhibitory effect on hepatic cholesterologenesis and 3-hydroxy-3-methylglutaryl CoA reductase (EC 1.1.1.34) which is considered as the key regulatory enzyme in hepatic sterol synthesis [62].

As presented in Fig. 5a, it was revealed that DEHP caused no qualitative alterations in number and arrangement of  $\alpha$ -EST bands in liver tissue. Otherwise, it caused mutagenicity at the quantitative level by increasing quantity of the  $\alpha$ -EST2 band (Rf 0.78, Int. 3148.55 and Qty

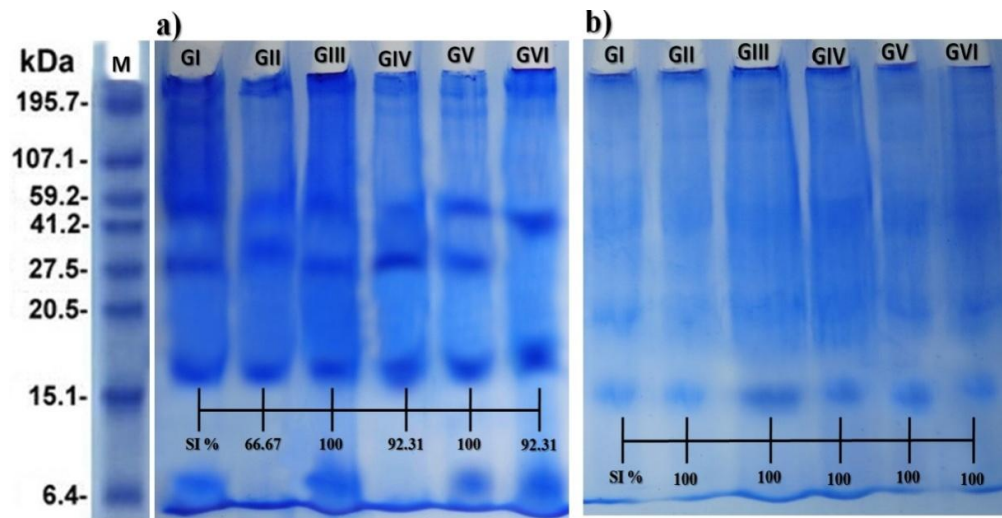
16.96) (Fig. 5b). The treatment with *A. senegal* extract decreased quantity of the  $\alpha$ -EST2 band in all extract treated groups. As regards  $\beta$ -EST enzyme, it was observed that DEHP caused qualitative mutagenicity represented by disappearance of  $\beta$ -EST2 band with appearance of 3 characteristic ones at Rfs 0.31, 0.43 and 0.52 (Int. 1131.16, 5391.56 and 1178.68; Qty 0.76, 3.60 and 0.79, respectively). Moreover, the lowest SI % was noticed in DEHP-treated group (66.67%). *A. senegal* extract increased the SI % to the highest value (100%) through restoring the  $\beta$ -EST2 band associated with hiding the characteristic ones (Fig. 6a).

**Table 4. Prophylactic and therapeutic effect of acacia extract on monoamines and their metabolites against brain toxicity induced by DEHP in rats**

Groups	Monoamines concentration ( $\mu\text{g/g}$ )					
	NE	DA	5HT	DOPAC	HVA	5HIAA
GI	0.98±0.07	2.09±0.20	0.87±0.10	0.84±0.04	0.66±0.07	0.71±0.06
GII	0.43±0.03 <sup>a</sup>	1.02±0.17 <sup>a</sup>	0.57±0.04 <sup>a</sup>	0.49±0.07 <sup>a</sup>	0.48±0.07 <sup>a</sup>	0.51±0.06 <sup>a</sup>
GIII	0.583±0.06 <sup>ab</sup>	1.25±0.14 <sup>a</sup>	0.65±0.08 <sup>ab</sup>	0.61±0.06 <sup>ab</sup>	0.55±0.05 <sup>ab</sup>	0.53±0.01 <sup>a</sup>
GIV	0.70±0.07 <sup>ab</sup>	1.56±0.25 <sup>ab</sup>	0.66±0.05 <sup>ab</sup>	0.76±0.04 <sup>b</sup>	0.71±0.06 <sup>b</sup>	0.70±0.10 <sup>b</sup>
GV	0.81±0.08	1.87±0.13	0.77±0.06	0.76±0.07	0.67±0.09	0.75±0.05
GVI	0.70±0.10 <sup>ab</sup>	1.98±0.10 <sup>b</sup>	0.827±0.02 <sup>b</sup>	0.74±0.05 <sup>ab</sup>	0.70±0.10 <sup>b</sup>	0.73±0.08 <sup>b</sup>

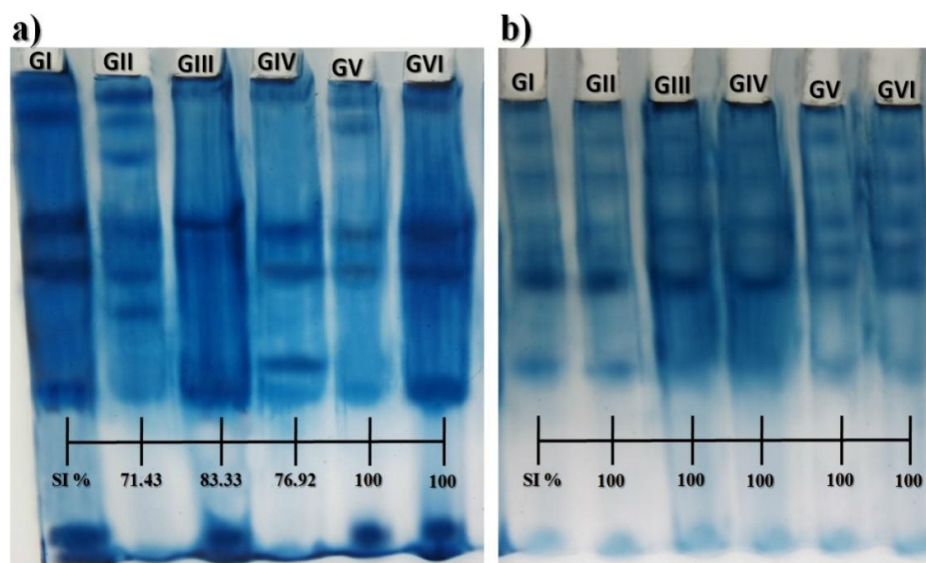
Values are expressed as mean  $\pm$  SE for 6 rats /group. a: significant difference from GI group at  $P < 0.05$ , b: significant difference from GII at  $P < 0.05$ .

Group I: Control group; Group II: DEHP-treated group; Group III: *A. senegal* extract post-treated group; Group IV: *A. senegal* extract simultaneous treated group; Group V: *A. senegal* extract treated group; Group VI: *A. senegal* extract pre-treated group



**Fig. 3. Electrophoretic protein patterns showing prophylactic and therapeutic effect of daily oral administration of acacia extract against tissue toxicity induced by DEHP on a) liver tissue and b) brain tissue of rats**

Group I: Control group; Group II: DEHP-treated group; Group III: *A. senegal* extract post-treated group; Group IV: *A. senegal* extract simultaneous treated group; Group V: *A. senegal* extract treated group; Group VI: *A. senegal* extract pre-treated group



**Fig. 4. Electrophoretic lipoprotein patterns showing prophylactic and therapeutic effect of daily oral administration of acacia extract against tissue toxicity induced by DEHP on a) liver tissue and b) brain tissue of rats**

Group I: Control group; Group II: DEHP-treated group; Group III: *A. senegal* extract post-treated group; Group IV: *A. senegal* extract simultaneous treated group; Group V: *A. senegal* extract treated group; Group VI: *A. senegal* extract pre-treated group


Moreover, in the brain tissue,  $\alpha$ -EST pattern was represented by only one band. DEHP caused no qualitative abnormalities. Otherwise, it caused qualitative alterations by enhancing quantity of the  $\alpha$ -EST band (Rf 0.21, Int. 1618.29 and Qty 15.66). The treatment with *A. senegal* extract decreased quantity of the  $\alpha$ -EST band in all extract treated groups (Fig. 5b). As regards  $\beta$ -EST enzyme, it was noticed that phthalate caused mutagenicity represented qualitatively by disappearance of  $\beta$ -EST1,  $\beta$ -EST2,  $\beta$ -EST3 and  $\beta$ -EST5 bands with existence of 2 characteristic bands at Rfs 0.44 and 0.75 (Int. 105.78 and 318.21 ; Qty 0.54 and Qty 1.62, respectively). Furthermore, it caused quantitative alterations through decreasing quantity of the  $\beta$ -EST4 band (Rf 0.86, Int. 190.50 and Qty 0.97) with respect to control one (Rf 0.86, Int. 284.94 and Qty 1.61) (Fig. 6b). In addition, the lowest SI value was observed in DEHP-treated group (25%). The SI % increased and reached the highest value (100%) in all *A. senegal* extract treated groups through restoring the absent bands and hiding the characteristic ones. Moreover, quantity of the  $\beta$ -EST4 band still lowered in all DEHP-treated groups that treated with extract in combination. Esterases belong to the lysosomal lipolytic enzymes that catalyze hydrolysis of the neutral lipids (triglyceride and cholesterol esters) which are introduced into cells as components of

lipoproteins and lipid deposits [63]. During the present study, DEHP caused mutagenicity detected electrophoretically in the  $\alpha$ - and  $\beta$ -esterases. This might be attributable to its effect on the membrane bound enzymes that are sensitive to changes in membrane fluidity which reflects alterations in the physical state of the membrane-lipids [64]. Moreover, the inhibitory or stimulatory effect of phthalates on various membrane bound enzymes is an indirect effect of their ability to modify membrane fluidity. In addition, phthalates exhibit lipophilic activity and can partition across organellar membranes and disturb the physical composition of the lipid microenvironment surrounding the particulate enzymes [65]. In the brain tissue, DEHP caused quantitative changes in the  $\alpha$ - and  $\beta$ -EST patterns. This may be attributed to the inhibitory effect of DEHP on ChE. Consequently, this leads to accumulation of Ach and then activation of glutamatergic neurones by increase GLU that is a major agonist of N-methyl D-aspartate receptors and a major excitatory neurotransmitter in the central nervous system, as well as being a potent excitotoxin [66].

As illustrated in Fig. 7a, it was noticed DEHP induced cleavage of the genomic DNA in liver tissue giving 3 unique fragments at Rfs 0.17, 0.56 and 0.88 (Mwts 2585, 1100 and 1384 BP;

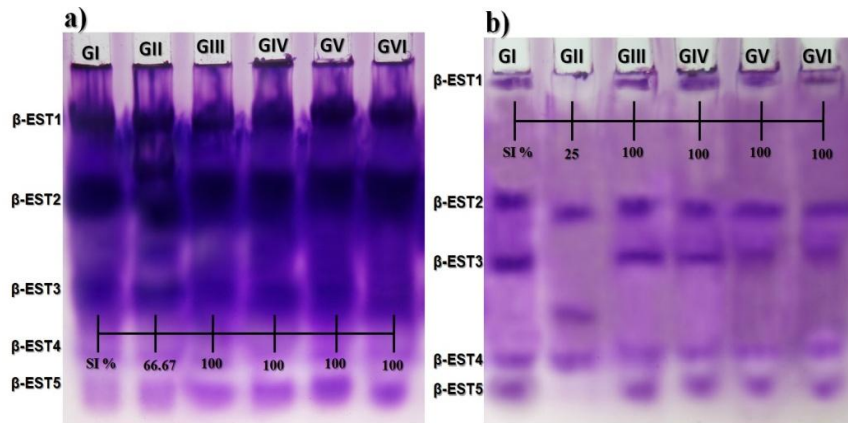
Q % 9.97, 14.05 and 20.49, respectively). With respect to control, the genomic DNA remains integrated in the DEHP-treated groups that treated with *A. senegal* extract in GIII and GIV groups. While in the GVI group, there was extra band identified at Rf 0.18 (Mwt 2552 BP and Q % 9.54). Furthermore, DEHP induced DNA damage severely in the brain tissue (Fig. 7b) giving 4 fragments at Rfs 0.1, 0.26, 0.51 and 0.80 (Mwts 3465, 2015, 1214 and 798 BP; Q % 4.33, 3.60, 3.36 and 9.02, respectively). In addition, the

genomic DNA pattern still damaged in brain tissue of *A. senegal* extract treated groups. It was noticed that 3 fragments were identified at Rfs 0.10, 0.33 and 0.50 (Mwts 3542, 1631 and 1223 BP; Q % 3.88, 5.05 and 6.98, respectively) in GIII group, 2 fragments identified at Rfs 0.10 and 0.30 (Mwts 3516 and 1777 BP; Q % 4.92 and 4.55) in GIV group. In addition 3 fragments were identified at Rfs 0.10, 0.52 and 0.83 (Mwts 3465, 1196 and 766 BP; Q % 8.04, 3.99 and 8.31, respectively) in GVI group.



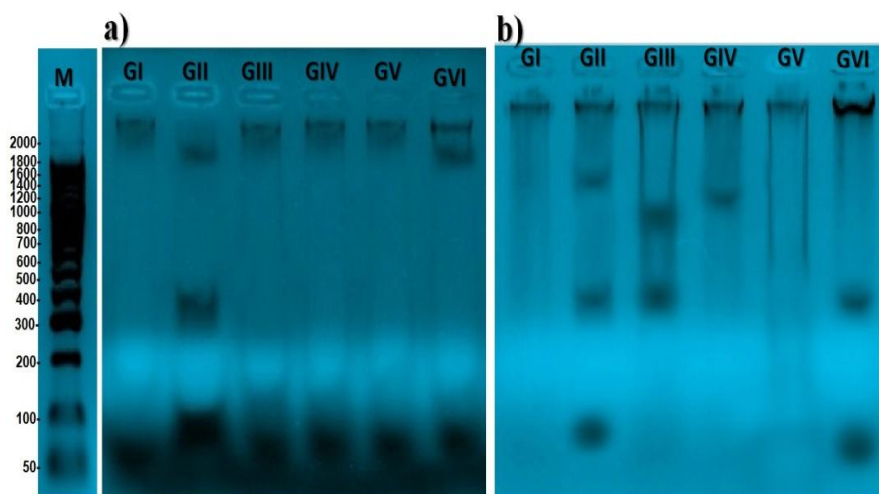
**Fig. 5. Electrophoretic  $\alpha$ -esterase pattern showing prophylactic and therapeutic effect of daily oral administration of *acacia* extract against tissue toxicity induced by DEHP on a) liver tissue and b) brain tissue of rats**

Group I: Control group; Group II: DEHP-treated group; Group III: *A. senegal* extract post-treated group; Group IV: *A. senegal* extract simultaneous treated group; Group V: *A. senegal* extract treated group; Group VI: *A. senegal* extract pre-treated group



**Fig. 6. Electrophoretic  $\beta$ -esterase pattern showing prophylactic and therapeutic effect of daily oral administration of *acacia* extract against tissue toxicity induced by DEHP on a) liver tissue and b) brain tissue of rats**

Group I: Control group; Group II: DEHP-treated group; Group III: *A. senegal* extract post-treated group; Group IV: *A. senegal* extract simultaneous treated group; Group V: *A. senegal* extract treated group; Group VI: *A. senegal* extract pre-treated group



**Fig. 7. Genomic DNA pattern showing prophylactic and therapeutic effect of daily oral administration of acacia extract against tissue toxicity induced by DEHP on a) liver tissue and b) brain tissue of rats**

Group I: Control group; Group II: DEHP-treated group; Group III: *A. senegal* extract post-treated group;  
Group IV: *A. senegal* extract simultaneous treated group; Group V: *A. senegal* extract treated group;  
Group VI: *A. senegal* extract pre-treated group

During the current study, DEHP exhibited ability to produce DNA damage. This was in accordance with Kornbrust et al. [67] who suggested that phthalate induced DNA damage, either directly or as a result of the peroxisomes proliferation associated with increased production of hydrogen peroxide and other DNA-damaging oxygen radicals.

Treatment with *A. senegal* extract reversed these changes in the electrophoretic and genomic patterns. This might be attributed to ability of the extract to inhibit xanthine oxidase and superoxide radicals and hence to normalize the imbalanced antioxidant system in hepatocytes [20,68]. These findings were supported by results of the oxidative stress markers reported earlier. As regards in the brain tissue, phthalate induced cleavage of the genomic brain DNA. This may refer to the severe changes which include alterations in DNA methylation, histone proteins, non-coding RNA, or chromatin arrangement leading to corresponding gene expression changes in the brain and hence modifications in neuronal cells [69]. *A. senegal* extract could not prevent the DNA damage in the brain. This because dose of the extract was not sufficient to exhibit its beneficial activity on the genomic DNA. In parallel to the study suggested by Sharma et al. [70], *A. senegal* can be added as an adjuvant to existing therapies for the treatment of brain related disorders. However, further studies

required to reveal the most suitable dose targeting different brain areas to prove the benefits conclusively.

#### 4. CONCLUSION

The present study was conducted that DEHP caused elevation of hepatic enzymes (ALT, AST, ALP and AChE) with lowering activities of antioxidant enzymes (TAC, SOD, CAT and Gpx). In coincide with these biochemical results, it was noticed that DEHP caused severe histopathological alterations in the liver tissue. *A. senegal* extract lowered the hepatic markers and restored activities of the antioxidant enzymes to normal values. Also, the adverse effect of DEHP targeted the brain tissue. This finding was supported by elevation of excitatory amino acids (ASP and GLU) and decline of inhibitory amino acids (GABA and GLY) and monoamines in brain of DEHP-treated rats. *A. senegal* extract exhibited ameliorative effect on levels of brain amino acids, monoamines and their metabolites. DEHP caused mutagenicity in the native protein, lipoprotein and isoenzyme patterns and in liver tissues. No changes detected in electrophoretic protein and lipoprotein patterns in brain of DEHP-treated group. Furthermore, DEHP induced cleavage of the genomic DNA in liver and brain tissues. *A. senegal* extract exhibited beneficial activity by restoring the normal bands and hiding the abnormal ones.



## COMPETING INTERESTS

Authors have declared that no competing interests exist.

## REFERENCES

1. Benjamin S, Pradeep S, Josh MKS, Kumar S, Masai E. A monograph on the remediation of hazardous phthalates. *J. Hazard. Mater.* 2015;298:58–72.
2. Green R, Hauser R, Calafat AM, Weuve J, Schettler T, Ringer S, Huttner K, Hu H. Use of di(2-ethylhexyl) phthalate-containing medical products and urinary levels of mono(2-ethylhexyl) phthalate in neonatal intensive care unit infants *Environ. Health Perspect.* 2005;113:1222-1225.
3. Buang Y. The enlargements of liver size induced by orotic acid and di (2-ethyl hexyl) phthalate occur in different metabolic pathways. *Journal of Applied Pharmaceutical Science.* 2011;01(08):71-75.
4. Jönsson BA, Richthoff J, Rylander L, Giwercman A, Hagmar L. Urinary phthalate metabolites and biomarkers of reproductive function in young men. *Epidemiology.* 2005;16:487-493.
5. Erythropel HC, Maric M, Nicell JA, Leask RL, Yargeau V. Leaching of the plasticizer di(2-ethylhexyl)phthalate (DEHP) from plastic containers and the question of human exposure. *Applied Microbiology and Biotechnology.* 2014;98(24):9967–9981.
6. Rusyn I, Peters JM, Cunningham ML. Modes of action and species-specific effects of di-(2-ethylhexyl)phthalate in the liver. *Crit. Rev. Toxicol.* 2006;36:459-479.
7. Kluwe WM, Huff JE, Matthews HB, Irwin R, Haseman JK. Comparative chronic toxicities and carcinogenic potentials of 2-ethylhexyl-containing compounds in rats and mice. *Carcinogenesis.* 1985;6:1577–1583.
8. Cartwright CD, Owen SA, Thompson IP, Burns RG. Biodegradation of diethyl phthalate in soil by a novel pathway. *FEMS Microbiol. Lett.* 2000;186:27-34.
9. Xu H, Shao X, Zhang Z, Zou Y, Chen Y, Han S, Wang S, Wu X, Yang L, Chen Z. Effects of di-n-butyl phthalate and diethyl phthalate on acetylcholinesterase activity and neurotoxicity related gene expression in embryonic zebrafish. *Bull. Environ. Contam. Toxicol.* 2013;91:635–639.
10. Frith U. Mind blindness and the brain in autism. *Neuron.* 2002;32:969–979.
11. Malviya S, Rawat S, Gahshi Z. Medicinal attributes of *Acacia nilotica* Linn - A comprehensive review on ethno pharmacological claims. *Int. J. of Pharm. and Life Sci.* 2011;2(6):830- 837.
12. Al-Yahya AA, Al-Majed AA, Gado AM, Daba MH, Al-Shabanah OA, Abd-Allah AR. *Acacia Senegal* gum exudate offers protection against cyclophosphamide induced urinary bladder cytotoxicity. *Oxid Med Cell Longev.* 2009;2(4):207–213.
13. Almahy HA, Nasir OD. Phytochemical and mineral content of the leaves of four Sudanese *Acacia* species. *Journal of Stored Products and Postharvest Research.* 2011;2(11):221–226.
14. Tung YT, Wu JH, Huang CC, Peng HC, Chen YL, Yang SC, Chang ST. Protective effect of *Acacia confusa* bark extract and its active compound gallic acid against carbon tetrachloride-induced chronic liver injury in rats. *Food Chem. Toxicol.* 2009; 47(6):1385-1392.
15. Leung AY. *Encyclopedia of common natural ingredients used in food, drugs, and cosmetics.* John Wiley & Sons, New York; 1980.
16. Fatope MO, Marwah RG, Al Mahrooqi R, Varma GB, Al Abadi H, Al-Burtamani SS. Antioxidant capacity of some edible and wound healing plants in Oman. *J. Food Chem.* 2007;101(2):465-470.
17. Abd-Allah ARA, Al- Yahya AA, Al-Majed AA, Gado AM, Daba MH, Al-Shabanah OA, El-Azab AS. *Acacia senegal* gum exudate offers protection against cyclophosphamide induced urinary bladder cytotoxicity. *Oxidative Medicine and Cellular Longevity.* 2009;2(4):207-213.
18. Gamal El-din AM, Mostafa AM, Al-Shabanah OA, Al-Bekairi AM and Nagi MN. Protective effect of arabic gum against acetaminophen-induced hepatotoxicity in mice. *Pharmacol. Res.* 2003;48(6):631-635.
19. Hooda MS, Pal R, Bhandari A, Singh J. Antidiabetic activity of *Acacia senegal* pod extract in streptozotocin induced diabetic rats. *Int. J. of Indigenous Medicinal Plants.* 2013;46(4):1400-1404.
20. Kannan N, Sakthivel KM, Guruvayoorappan C. Protective Effect of *Acacia nilotica* (L.) against Acetaminophen-Induced Hepatocellular Damage in Wistar Rats. *Hindawi*

- Publishing Corporation, Advances in Pharmacological Sciences; 2013. Article ID 987692, 9 pages.
21. Meena PD, Kaushik P, Shukla S, Soni AK, Kumar M, Kumar A. Anticancer and antimutagenic properties of *Acacia nilotica* (Linn.) on 7,12-dimethylbenz(a)anthracene-induced skin papillomagenesis in Swiss albino mice. *Asian Pacific Journal of Cancer Prevention*. 2006;7(4):627–632.
  22. Singh BN, Singh BR, Sarma BK, Singh HB. Potential chemoprevention of N-nitrosodiethylamine-induced hepatocarcinogenesis by polyphenolics from *Acacia nilotica* bark. *Chem. Biol. Interact*. 2009;181(1):20-28.
  23. Jain GC, Pareek H, Khajja BS, Jain K, Jhalani S, Agarwal S, Sharma S. Modulation of di-(2-ethylhexyl) phthalate induced hepatic toxicity by *Apium graveolens* L. seeds extract in rats. *African Journal of Biochemistry Research*. 2009; 3(5):222-225.
  24. Reitman S, Frankel S. Colorimetric method for aspartate and alanine transferases. *Am. J. Clin. Pathol*. 1957;28(1):56–63.
  25. Kind PRM, King EJ. Estimation of plasma phosphatase by determination of hydrolysed phenol with amino antipyrine. *J. Clin. Pathol*. 1954;7:322-326.
  26. Ellman GL, Courtney KD, Andres V Jr., Featherstone RM. A new and rapid colorimetric determination of acetylcholinesterase activity. *Biochem. Pharmacol*. 1961;7:88-95.
  27. Ohkawa H, Ohishi N, Nagi K. Assay of lipid peroxides in animal tissue by thiobarbituric acid reaction. *Anal. Biochem*. 1979;95: 351-358.
  28. Koracevic D, Koracevic G, Djordjevic V, Andrejevic S, Cosic V. Method for the measurement of antioxidant activity in human fluids. *J. Clin. Pathol*. 2001;54:356-361.
  29. Sun Y, Oberley LW, Li Y. A Simple Method for Clinical Assay of Superoxide Dismutase. *Clin. Chem*. 1988;34:479-500.
  30. Aebiech H. In Bergmeter HU, (Ed). *Methods in Enzymatic Analysis*, Weinheim, Verlag Chemie. 1982;3:273-282.
  31. Lawrence RA, Burk RF. Glutathione peroxidase activity in selenium-deficient rat liver. *Biochem. Biophys. Res. Commun*. 1976;71:952–958.
  32. Heinrikson RL, Meredith SC. Amino acid analysis by RP-HPLC: Precolumn Derivatization with phenylisothiocyanate. *Anal. Biochem*. 1984;136:65-74.
  33. Pagel P, Blome J, Wolf HU. High-performance liquid chromatographic separation and measurement of various biogenic compounds possibly involved in the pathomechanism of Parkinson's disease *Journal of Chromatography B*. 2000;746:297-304.
  34. Bancroft JD, Stevens A, Turner DR. *Theory and Practice of Histological Techniques*. Fourth Ed. Churchill Livingstone, New York, London, San Francisco, Tokyo; 1996.
  35. Bradford MM. A rapid and sensitive method for the quantitation of microgram quantities of protein utilizing the principle of protein-dye binding. *Anal. Biochem*. 1976; 72:248-254.
  36. Laemmli UK. Cleavage of structural proteins during the assembly of the head of Bacteriophage T4. *Nature*. 1970;227: 680-685.
  37. Hames BD. One-dimensional polyacrylamide gel electrophoresis. In: *Gel electrophoresis of proteins*: B.D. Hames B.D. and Rickwood D., 2nd ed. Oxford university press, NY. 1990;1-147.
  38. Subramaniam HN, Chaubal KA. Evaluation of intracellular lipids by standardized staining with a Sudan black B fraction. *J. Biochem. Biophys. Methods*. 1990;21(1): 9-16.
  39. Ahmad A, Maheshwari V, Ahmad A, Saleem R, Ahmad R. Observation of esterase-like-albumin activity during N'-nitrosodimethyl amine induced hepatic fibrosis in a mammalian model. *Maced. J. Med. Sci*. 2012;5(1):55–61.
  40. Barker DL, Hansen MS, Faruqi AF, Giannola D, Irsula OR, Lasken RS, Latterich M, Makarov V, Oliphant A, Pinter JH. Two Methods of Whole-Genome Amplification Enable Accurate Genotyping Across a 2320-SNP Linkage Panel. *Genome Res*. 2004;14(5):901–907.
  41. Nei M, Li WS. Mathematical model for studying genetic variation in terms of restriction endonuclease. *Proc. Natl. Acad. Sci., USA*. 1979;76:5269–5273.
  42. Dirven HA, van den Broek PH, Jongeneelen FJ. Effect of di(2-ethylhexyl)phthalate on enzyme activity levels in liver and serum of rats. *Toxicology*. 1990;65(1-2):199-207.
  43. Sanchez-Valle V, Chavez-Tapia NC, Uribe M, Mendez-Sanchez N. Role of oxidative

- stress and molecular changes in liver fibrosis: A review. *Curr. Med. Chem.* 2012; 19:4850–4860.
44. Li AN, Li S, Zhang YJ, Xu XR, Chen YM, Li HB. Resources and biological activities of natural polyphenols. *Nutrients.* 2014;6: 6020–6047.
  45. Gao J, Tang X, Dou H, Fan Y, Zhao X, Xu Q. Hepatoprotective activity of Terminalia catappa L. leaves and its two triterpenoids. *Journal of Pharmacy and Pharmacology.* 2004;56(11):1449–1455.
  46. Burnett W. An Assessment of the Value of Serum Cholinesterase as a Liver Function Test and in the Diagnosis of Jaundice. *Gut.* 1960;1(4):294–302.
  47. Orisakwe OE, Hussaini DC, Afonne OJ. Testicular effects of sub-chronic administration of Hibiscus sabdariffa calyx aqueous extract in rats. *Int. J. Pharm. Bio. Sci.* 2013;4(4):(B)1366–1376.
  48. Barse AV, Chakrabarti T, Ghosh TK, Pal AK, Jadhao SB. Endocrine disruption and metabolic changes following exposure of cyprinus carpio to diethyl phthalate. *Pesticides Biochemistry and Physiology.* 2007;88:36–42.
  49. Pal R, Hooda MS, Bias CS, Singh J. Hepatoprotective activity of Acacia Senegal Pod against Carbon Tetrachloride-Induced Hepatotoxicity in Rats. *Int. J. Pharm. Sci. Rev. Res.* 2014; 26(1):165-168.
  50. Naik SR. Antioxidants and their role in biological functions: An overview. *Indian Drugs.* 2003;40(9):501–516.
  51. Erkekoglu P, Zeybek ND, Giray BK, Rachidi W, Kizilgun M, Hininger-Favier I, Favier A, Asan E, Hincal F. The effects of di(2-ethylhexyl)phthalate on rat liver in relation to selenium status. *Int. J. Exp. Path.* 2014;95:64–77.
  52. Izunya AM, Nwaopara AO, Odike MAC, Oaikheni GA, Bankole JK. Histological effects of oral administration of Artesunate on the liver in Wistar Rats. *Res. J. Appl. Sci. Eng. Technol.* 2010;2:314-318.
  53. Rajbir S, Bikram S, Sukhpreet S, Neeraj K, Subodh K, Saroj A. Umbelliferone—an antioxidant isolated from *Acacia nilotica* (L.) Willd. Ex. Del. *Food Chemistry.* 2010; 120(3):825–830.
  54. Hunter D, Perry KMA, Evans RB. Toxic polyneuritis arising during the manufacture of tricresyl phosphate. *Br. J. Ind. Med.* 1994;1:227-231.
  55. Wang Y, Qin Z. Molecular and cellular mechanisms of excitotoxic neuronal death. *Apoptosis.* 2010;15:1382-402.
  56. Klastersky J. Side effects of ifosfamide. *Oncology.* 2003;65(Suppl 2):7–10.
  57. Keddy PGW, Dunlop K, Warford J. Neuroprotective and anti-inflammatory effects of the flavonoid-enriched fraction AF4 in a mouse model of hypoxic-ischemic brain injury. *PLoS ONE.* 2012;7(12). Article ID e51324.
  58. Dong G, Luo J, Kumar V, Dong Z. Inhibitors of Histone Deacetylases Suppress Cisplatin-Induced, Clarendon Press, Oxford, UK; 2010.
  59. Radad K, Gille G, Moldzio R, Saito H, Rausch WD. Ginsenosides Rb-1 and Rg(1) effects on mesencephalic dopaminergic cells stressed with glutamate. *Brain Res.* 2004;1021:41–53.
  60. Benavente-Garcia O, Castillo J, Lorente J, Ortuno A, Del Rio JA. Antioxidant activity of phenolics extracted from *Olea europaea* L. leaves. *Food Chemistry.* 2000;68:457–462.
  61. Watanabe T, Lalwani ND, Reddy JK. Specific changes in the protein composition of rat liver in response to the peroxisome proliferators ciprofibrate, Wy-14,643, and di-(2-ethylhexyl) phthalate. *Biochem. J.* 1985;227:767-775.
  62. Bell FP, Patt CS, Brundage B, Gillies PJ, Phillips WA. Studies on lipid biosynthesis and cholesterol content of liver and serum lipoproteins in rats fed various phthalate esters. *Lipids.* 1978;13:66-74.
  63. Yanagita T, Enomoto N, Kuzuhara S. Effects of Phthalate Esters on Liver Lysosomal Acid Lipase and Acid Esterase *in vitro.* *Agricultural and Biological Chemistry.* 1986;50(6):1653-1654.
  64. Bell FP. The effect of local anesthetics on arterial lipid metabolism. *Atherosclerosis.* 1981;38:81-88.
  65. Bell FP. Effects of phthalate esters on lipid metabolism in various tissues, cells and organelles in mammals. *Environmental Health Perspectives.* 1982;45:41-50.
  66. De Groot DM, Bierman EP, Bruijnzeel PL, Carpentier P, Kulig BM, Lallement G, Melchers BP, Philippens IH, van Huygevoort AH. Beneficial effects of TCP on Soman intoxication in guinea pigs: Seizures, brain damage, and learning behavior. *J. Appl. Toxicol.* 2001;21:S57-S65.

67. Kornbrust DJ, Barfknecht TR, Ingram P, Shelburne JD. Effect of di(2-ethylhexyl) phthalate on DNA repair and lipid peroxidation in rat hepatocytes and on metabolic cooperation in Chinese hamster V-79 cells. *J. Toxicol. Environ. Health.* 1984;13(1):99-116.
68. Bouhlel I, Kilani S, Skandrani I, Ben Amar R, Nefatti A, Laporte F, Hininger-Favier I, Ghedira K, Chekir-Ghedira L. Acacia salicina extracts protect against DNA damage and mutagenesis in bacteria and human lymphoblast cell K562 cultures. *Nutr. Res.* 2008;28(3):190-7.
69. Martinez-Arguelles DB, Papadopoulos V. Identification of hot spots of DNA methylation in the adult male adrenal in response to in utero exposure to the ubiquitous endocrine disruptor plasticizer di-(2-ethylhexyl) phthalate. *Endocrinology.* 2015;156(1):124-33.
70. Sharma A, Shetty M, Parida A, Adiga S, Kamath S, Sowjanya. Effect of ethanolic extract of *Acacia auriculiformis* leaves on learning and memory in rats. *Pharmacognosy Res.* 2014;6(3):246–250.

© 2017 Seif et al.; This is an Open Access article distributed under the terms of the Creative Commons Attribution License (<http://creativecommons.org/licenses/by/4.0>), which permits unrestricted use, distribution, and reproduction in any medium, provided the original work is properly cited.

*Peer-review history:*

*The peer review history for this paper can be accessed here:*  
<http://sciencedomain.org/review-history/21758>