



Case Study of a Zoonotic Infection Caused by *Streptococcus suis* Reported for the First Time in Goa Region, India

**Shradha R. Gaonkar^{a,b,++*}, Rajeshwar V. Naik^{c,#},
Sushanta Kalekar^{d,†} and Alka Sagar^{e,†}**

^a Department of Microbiology, Royal Hospital, 403601, Goa, India.

^b Maharaja Agrasen Himalayan Garhwal University, India.

^c Royal Hospital Director, 403601, Goa Medical College, Goa, India.

^d Department of Microbiology, Govt. College Khandola, Goa University, 403107, India.

^e Department of Microbiology, Meerut Institute of Engineering and Technology (MIET), India.

Authors' contributions

This work was carried out in collaboration among all authors. All authors read and approved the final manuscript.

Article Information

DOI: 10.9734/MRJI/2023/v33i81397

Open Peer Review History:

This journal follows the Advanced Open Peer Review policy. Identity of the Reviewers, Editor(s) and additional Reviewers, peer review comments, different versions of the manuscript, comments of the editors, etc are available here:

<https://www.sdiarticle5.com/review-history/106822>

Received: 18/07/2023

Accepted: 22/09/2023

Published: 26/09/2023

Case Study

ABSTRACT

This is a case study on epidemiological factor clinical spectrum and drug susceptibility of a rare zoonotic infection caused by *Streptococcus sui* in a 60 year female patient. Presented with fever and altered sensorium. Blood culture analysis revealed the causative agent to be *Streptococcus*

⁺⁺ Clinical Microbiologist and Msc. Microbiology PhD Scholar;

[#] Medical Director;

[†] Assistant Professor;

*Corresponding author: E-mail: shraddhagaonkk@gmail.com;

sui. Antibiotic sensitivity screening of the culture was also performed. So while recording the case history it was noted that the patient was in close contact with pigs on regular basis. The patient was treated with ceftriaxone antibiotic and responded favorably to the therapy. We represent the first human case of *Streptococcus sui* from Goa.

Keywords: *Streptococcus suis*; meningitis; spondylodiscitis.

1. INTRODUCTION

Streptococcus suis is an important pathogen which causes Streptococcosis in pigs and affects the swine industry. It is an encapsulated Gram-positive, facultative anaerobic bacterium, with a coccoid or ovoid morphology and may occur as single cells, in pairs or in chains. It was first reported in 1954 and can be classified into 35 serotypes based on differentiation of capsular antigens. It is a neglected zoonotic pathogen and in recent times the growing incidence of this pathogen has been observed chiefly in Asia. The largest number of cases have been reported from South East Asia, Thailand and Vietnam and sporadic reports from Singapore, Philippines and Laos [1,2]. Thus far, there have not been any significant number of cases reported from India.

Although it primarily causes infection in pigs and they are the natural reservoir of the pathogen, a late increasing number of human cases have been reported from different parts of the world and hence this particular pathogen has now been categorized as an emerging zoonotic pathogen. *Streptococcus suis* infection in humans mostly occurs in areas where pig rearing is a common occupation [3]. The highest risk is amongst patients in the age group 47-55 yrs [4,1,5,6,7].

Meningitis and sepsis are the most common clinical manifestations of *S. suis* infection and hearing loss is a frequent complication. Some other common clinical manifestations consist of endocarditis, arthritis, endophthalmitis and skin lesions [8,9].

In India, 70% of the pig population is reared under traditional small holder, low-input demand driven production system, except for a limited number of semi-commercial pig farms in Kerala, Punjab and Goa. Pork consumption is popular among select populations in India. Pig farming is extensively practiced on a domestic scale in the South Goa district and consumption of pork and related products is common in the state of Goa [10].

2. CASE REPORT

A 60-year-old female with an underlying condition of diabetes was admitted to a local hospital in South Goa and presented the following symptoms of chills with fever, decrease oral intake, headaches and giddiness for one day. The medical history was specific except that the patient reported close contact with pigs on a regular basis. At the time of admission body temperature was noticed, Bp 110/70 mm of Hg and pulse rate 104/min pulse, Random sugar 370gm/dl and SpO₂ 99%. Physical examination observed as cardiac arrhythmia, stiffness of neck, giddiness and drowsiness.

3. METHODS

Blood was drawn for routine investigation purposes and the results obtained were as follows: Procalcitonin 53.48 ng/ml, Hemoglobin 12.8 g/dl, Total count 20000/cu-mm and platelet count 1.30lakhs/ cu-mm.

Blood cultures were processed by the BD BACTEC FX 40 system. Growth of small α hemolytic colonies was observed on 5% sheep blood agar plate. On gram staining the culture presented as gram positive cocci in chains. It was also seen to be catalase negative.

The causative bacteria was identified as *Streptococcus suis* by Vitek 2 compact system gram positive identification card (BIOMERIEUX). The identification was further confirmed by Molecular tools according to which the bacteria was reported to be *Streptococcus sui*.

On carrying out antibiotic sensitivity tests by the disc diffusion method the bacteria was seen to be sensitive to Cefotaxim, Meropenem, Linzolid, Vancomycin and Ceftriaxone.

The patient was treated with Ceftriaxone 2 mg x 8 hourly and gradually responded. Patients responded to Ceftriaxone, with prompt improvement in sensorium and other clinical parameters gradually improving over the next 10days.

4. RESULTS AND DISCUSSION



Fig. 1. Growth of *Streptococcus suis* on blood agar



Fig. 2. Sensitivity plate

Report of Microbial Amplification:

1. DNA was isolated from the culture provided by the scientist. Its quality was evaluated on 1.0% Agarose Gel, a single band of high-molecular weight DNA has been observed.
2. Fragment of 16S rDNA gene was amplified by 27F and 1492R primers. A single discrete PCR amplicon band of 1500 bp was observed when resolved on Agarose gel.

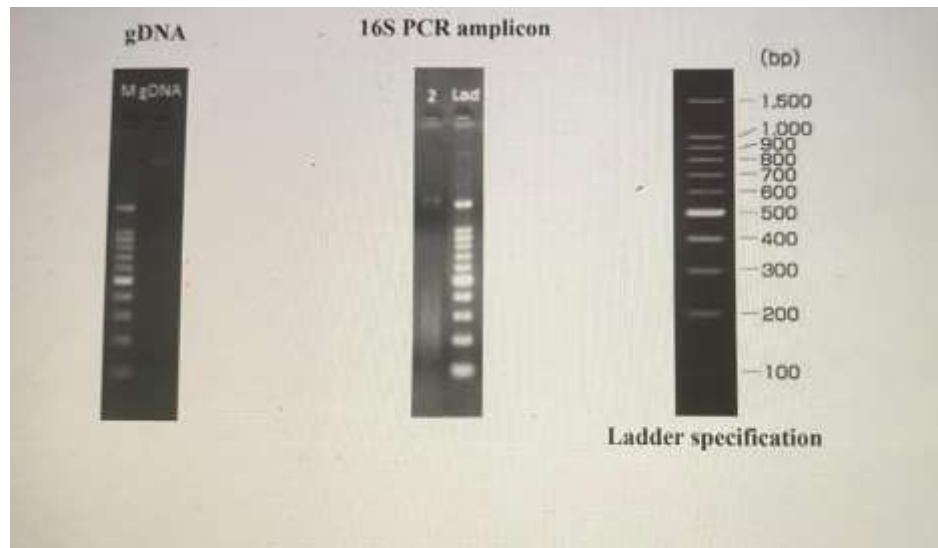


Fig. 3. gDNA and 16S Amplicon QC data

Sample which was labelled as *streptococcus suis* has shown the amplification Band with 16S Universal primers as observed in the above image.

To the best of our knowledge, this is the first report of human infection with *S. suis* in Goa. Human *S. suis* infection is usually acquired through occupational or household exposure to pigs or contaminated pork and pork products [11,2]. The proportion of *S. suis* meningitis patients with a history of pig exposure was 41% in Thailand [12] and 33% in Vietnam [6]. The reported cases of *S. suis* infections in humans have been increasing in recent times, which may be because of improved diagnostic techniques or changes in the epidemiological pattern of the pathogen.

The risk of contracting the disease also increases with age and some studies have shown an association with alcoholism and diabetes mellitus [13,14].

The patient described herein was in the high risk group for infection as she had been rearing pigs for several years. Her medical history includes diabetes mellitus and mild structural heart disease and being 60 years of age she is also in the high risk age group.

Although most reports of *S. suis* are sporadic like our case, however an outbreak of *S. suis* infection did occur in Sichuan Province, China between July and August 2005 [15]. The clinical course of patients in that outbreak was more

fulminant than in previous reports, and 38 of the 215 affected patients died.

Accurate identification of the pathogen is essential for determining the correct antimicrobial therapy and also for public health reasons. *S. suis* strains display a high frequency of resistance to tetracyclines and macrolides [16,17] however in our case the isolate was sensitive to all the antibiotics used in the sensitivity studies.

Some patients with *S. suis* meningitis described in previous reports have experienced relapse after 2 weeks of treatment with penicillin or ceftriaxone. Such cases of relapse occurred within 1 week of antibiotic cessation and responded to prolonged treatment for 4-6 weeks [4,5] Clinicians should be aware that the treatment recommendations may not be successful for all patients and may therefore need to be monitored and accordingly altered.

5. CONCLUSION

Streptococcus suis isolate was obtained by performing blood culture. Confirmation of the case was done rapidly using molecular tools. General awareness about clinical symptoms should be increased which will improve proper diagnosis within a short time frame. This is the first report of *S. suis* infection in human in Goa acquired through a zoonotic route. *S. suis* is not a notifiable pathogen in India and therefore scrutiny is only through such voluntary reports. Hence, it is very important that the pathogen

should be correctly identified and the epidemiological route should be traced to avoid public health issues. Awareness should also be created about this emerging zoonotic pathogen amongst clinicians, laboratory technicians, health care workers and above all the people involved in the pig rearing and pork processing industry such that major outbreaks can be averted.

CONSENT

As per international standard or university standard, patient(s) written consent has been collected and preserved by the author(s).

ETHICAL APPROVAL

As per international standard or university standard written ethical approval has been collected and preserved by the author(s).

COMPETING INTERESTS

Authors have declared that no competing interests exist.

REFERENCES

1. Hughes JM. Streptococcus suis: An Emerging Human Pathogen. *Streptococcus suis: An Emerging Human Pathogen*, Issue Cover. 2009;48(5):6. Available: <https://doi.org/10.1086/596763>
2. Suankratay C, Intalapaporn P, Nunthapisud P, Arunyingmongkol K, Wilde H. Streptococcus suis meningitis in Thailand. *Southeast Asian J Trop Med Public Health*. 2004;35:868–876. Available: <https://pubmed.ncbi.nlm.nih.gov/15916083>
3. Gottschalk M, Segura M, Xu J. Streptococcus suis infections in humans: the Chinese experience and the situation in North America. *Anim Health Res Rev*. 2007;8:29–45. Available: <https://pubmed.ncbi.nlm.nih.gov/17692141>
4. Arends JP. Meningitis caused by Streptococcus suis in humans, *Rev Infect Dis*, 1988. Meningitis caused by Streptococcus suis in humans, *Rev Infect Dis*, 1988, vol. 10(*Rev Infect Dis*. 1988;10:131-7). Available: <https://scholar.google.com/scholar>
5. Lun ZR. Streptococcus suis: an emerging zoonotic pathogen, (*Lancet Infect Dis*) 2007;7. Available: <http://www.ncbi.nlm.nih.gov/pubmed/3353625>
6. Mai NT. Streptococcus suis meningitis in adults in Vietnam. 2008;46(*Clin Infect Dis*). Available: <http://www.ncbi.nlm.nih.gov/pubmed/19413493>
7. Wangkaew S. Streptococcus suis infection: A series of 41 cases from Chiang Mai University Hospital. (*J Infect*. 2006;52:455-60. Available: <https://scholar.google.com/scholar>
8. Yu H. Human Streptococcus suis outbreak, Sichuan, China. 2006;12(*Emerg Infect Dis*). Available: <http://dx.doi.org/10.3201/eid1206.051194>
9. Wertheim HF, Nghia HD, Taylor W, Schultsz C. Streptococcus suis: an emerging human pathogen. *Clin Infect Dis*. 2009;48:617–625. Available: <https://pubmed.ncbi.nlm.nih.gov/19191650>
10. Meuwissen MP, Van Der Lans IA, Huirne RB. Consumer preferences for pork supply chain attributes. *NJAS-Wageningen Journal of Life Sciences*. 2007;54(3):293-312.
11. Huang YT, Teng LJ, Ho SW, Hsueh PR. Streptococcus suis infection. *J Microbiol Immunol Infect*. 2005;38:306–313. Available: <https://pubmed.ncbi.nlm.nih.gov/16211137>
12. Suankratay C, Intalapaporn P, Nunthapisud P, Arunyingmongkol K, Wilde H. Streptococcus suis meningitis in Thailand. *Southeast Asian J Trop Med Public Health*. 2004;35:868–876. Available: <https://pubmed.ncbi.nlm.nih.gov/15916083>
13. Suganya Yongkiettrakul, Krissana Maneerat, Buppa Arechanajan, Yuwares Malila Potjane Srimanote, Marcello Gottschalk et al. Antimicrobial susceptibility of Streptococcus suis isolated from diseased pigs, asymptomatic pigs, and human patients in Thailand. *BMC Vet Res*. 2019;15(5). Available: <https://doi:10.1186/s12917-018-1732-5>.
14. Walsh B, Williams AE, Satsangi J. Streptococcus suis type 2: pathogenesis and clinical disease, *Rev Med Microbiol*. 1992;3:65-71. Available: <https://scholar.google.com/scholar>
15. World Health Organization. Outbreak associated with Streptococcus suis in pigs, China. *Wkly Epidemiol Rec*. 2005;80:269–270.

- Available:<https://pubmed.ncbi.nlm.nih.gov/16116899>
16. Milan R. Obradovic, Mariela Segura, Joaquim Segalés, Marcelo Gottschalk.et al. Review of the speculative role of co-infections in Streptococcus suis-associated diseases in pigs. Vet Res. 2021;52:49. Available:<https://doi.org/10.1186/s13567-021-00918-w>
17. Anonymous. Regulation (EC) No 178/2002. European Commission, Brussels. Anonymous, 2006. Statistics Netherlands 2006. Accessed 3 August 2006. Boehlje MD, Lins DA. 1998. Risks and risk management in an industrialised agriculture. Agricultural Finance Review. 2002;58: 1-16.

© 2023 Gaonkar et al.; This is an Open Access article distributed under the terms of the Creative Commons Attribution License (<http://creativecommons.org/licenses/by/4.0>), which permits unrestricted use, distribution, and reproduction in any medium, provided the original work is properly cited.

Peer-review history:
The peer review history for this paper can be accessed here:
<https://www.sdiarticle5.com/review-history/106822>