



A Clinico-pathological Study of Skin Tumours

P. Rekha¹ and Vindu Srivastava^{1*}

¹*Department of Pathology, Sree Balaji Medical College & Hospital (Affiliated to Bharath Institute of Higher Education and Research), Chennai, Tamil Nadu, India.*

Authors' contributions

This work was carried out in collaboration among all authors. All authors read and approved the final manuscript.

Article Information

DOI: 10.9734/JPRI/2021/v33i22A31386

Editor(s):

(1) Dr. Syed A. A. Rizvi, Nova Southeastern University, USA.

Reviewers:

(1) Ferry Fadzul Rahman, Universitas Muhammadiyah Kalimantan Timur, Indonesia.

(2) Jayendra R. Gohil, Government Medical College, Bhavnagar, MKB University, India.

Complete Peer review History: <http://www.sdiarticle4.com/review-history/66775>

Original Research Article

Received 25 January 2021

Accepted 31 March 2021

Published 09 April 2021

ABSTRACT

Skin cancers are relatively uncommon malignancies worldwide, but the incidence of skin cancers has progressively increased over the last few decades. The distinction between benign and malignant neoplasm are more difficult to define when they appear in skin than when found elsewhere and histopathological examination is frequently required to establish a definitive diagnosis. The present study was the incidence of various benign and malignant tumours of skin and its adnexa. Histopathological examination remains the gold standard in diagnosing most skin tumours. Thus diagnosis of any skin tumor can be done by correlating clinical features and histological features, which in turn can be supported by histochemistry, immunohistochemistry and electron microscopy. Most of the skin tumours were Nodular lesions (34.3%), followed by papular lesions (28.4%) and by ulcerated lesions (9.8%). Malignant tumours commonly presented as ulcerated lesions. Head and neck region was the most common site of occurrence followed by extremities and trunk. Keratinocytic (31.4%) tumours were the commonest group among all skin tumours.

Keywords: Autosomal dominant; electron microscopy; skin cancer; histochemistry.

1. INTRODUCTION

Skin is a heterogeneous organ in which cellular and molecular interactions govern several crucial responses to our environment [1]. The skin is uniquely adapted to protect the body from various external stimuli. It helps in regulating the body temperature and also helps in the synthesis of keratin, lipids, pigment, vitamin D and several enzymes. It has sensory functions like touch, pain and temperature and excretes salts and metabolites via sweat. It secretes sebum from sebaceous glands. It is prone for several inflammatory and neoplastic diseases. The incidence of skin cancer is increasing exponentially around the world [1]. Three main types of skin cancer are basal cell carcinoma (BCC), squamous cell carcinoma (SCC), and malignant melanoma. BCC and SCC, in combination, are referred to as non-melanoma skin cancers (NMSC). The cutaneous tumours comprise an extremely diverse and sizeable collection of pathologic entities and can be categorised into hamartomas, reactive hyperplasias and benign tumours reflecting their biologic behaviours [2].

Neoplasms of skin comprise a wide spectrum of benign and malignant tumours that exhibit morphological differentiation towards one or more of structures found in normal skin. Benign tumours like seborrheic keratosis, skin tags barely attract the attention of the patient or the treating clinician are of cosmetic importance. The premalignant conditions are better regarded as tumours *argery* in situ. The incidence of skin cancers has been increasing over the past decades. Currently between 2 and 3 million non-melanoma skin cancers and 132,000 melanoma skin cancers occur globally each year. One in every three cancers diagnosed is a skin cancer and according to Skin Cancer Foundation Statistics one in every five American s will develop skin cancer in their lifetime. Squamous cell carcinoma is considered to be the predominant non melanocytic skin cancer in the Indian population which is of epidemiological importance as it sets us apart from the global trend [3,4].

Several factors like genetic, environment, racial, enzyme defects, radiations, geographic factors, exposure to sun rays have been implicated in the etiopathogenesis of skin tumours [4]. Some of the skin tumours are autosomal dominantly inherited. These may not manifest until puberty. Examples are Trichoepithelioma, Cylindroma, Steatocystoma multiplex, Basal cell nevus and

Neurofibroma [2]. A number of environmental causes have been attributed like coal tar, cresolite oil, mineral oil, crude paraffin, arsenic, and sunlight, X rays. UVB rays (290–320 nm) are the most damaging part of sunrays [4,5].

The effect of sunlight is cumulative and produces other changes before malignancy occurs. Exposure to ionizing radiations may occur as an accidental occupational hazard. Longer wavelength radiant energy and gray rays may be carcinogenic. Basal cell carcinoma is the most common cancer by ionizing radiation [6-9].

2. MATERIALS AND METHODS

This study was conducted in the Department of pathology, Sree balaji medical college and hospital. We had analysed all clinically suspected cases of skin tumours received in our department from April 2015 to September 2016. A total of 102 histologically diagnosed skin tumour cases were included for studying the clinicopathological aspects of the same. Clinical features like age, sex, presenting complaints and site of lesion were provided by dermatology department & skin biopsy of the patient was sent to pathology department for histopathological diagnosis. The specimens were received in 10% neutral buffered formalin. Haematoxylin and eosin stained sections of skin biopsy were prepared to assess the histopathological diagnosis.

2.1 Staining Method (Haematoxylin and Eosin (H & E))

The slides were deparaffinised with xylene bath for 5 minutes. Then transferred to second xylene bath for 5 minutes. Then immersed in the bath of graded alcohol of 90%, 70% and 50% each for 3 minutes. Rinsed in running water for 1 minute and then briefly in distilled water. Stained with Harris's haematoxylin for 5 -10 minutes and rinsed in tap water. Differentiated in 1% acid alcohol by dipping 3-4 minutes and washed in tap water briefly. Blueing was done with Lithium carbonate, sections were appeared blue. Rinsed in tap water for 10-20 minutes. Stained with acidified 1% aqueous eosin for 30 seconds. Washed in running tap water for 1 minute. Dehydrated by passing through 3 baths of absolute alcohol. Passed through Xylene for 15 – 20 seconds. Finally, Mounted in DPX(Diestrene dibutylphthalate Xylene).

3. RESULTS AND DISCUSSION

The present study includes 102 cases of clinically and histologically diagnosed skin

tumours both benign and malignant. The specimens were received from department of Dermatology, Sree Balaji Medical College and Hospital. Among the 102 cases studied 84 were benign and 18 were malignant by histopathological examination.

It could be observed from Table 1 that, 49 lesions were seen on the face, 26 lesions on the extremities, 15 lesions on trunk and 12 lesions presented on the scalp. Nodular lesions and ulcerative lesions were single whereas macular and papular lesions were multiple. Benign lesions occurred in the form of nodules, papules or macules. Most ulcerative lesions were malignant. Of the 102 skin lesions 35 lesions

presented as nodule, 29 as papule, 10 as plaque, 3 as macule, 3 as wart and 22 lesions as ulcer.

The tumours were grouped into benign, and malignant categories based on the Histopathological diagnosis. 82.4% tumours were benign and 17.6% tumours were malignant in nature.

It could be inferred from the Table 3 that 42.2% of patients were in the age group between 21 and 40 years, 36.3% were in the age group between 40 and 61 years, 11.% of patients belonged to category with age less than 20 years and 9.8% were in the age group more than 61 years.

Table 1. Site of occurrence and morphology of lesions

Site	Nodule	Papule	Plaque	Wart	Macule	Ulcer	Total
Scalp	7	1	1	1	1	1	12
Face	12	23	3	1	1	9	49
Trunk	5	2	1	1	1	5	15
Extremities	11	3	5	-	-	7	26
Total	35	29	10	3	3	22	102

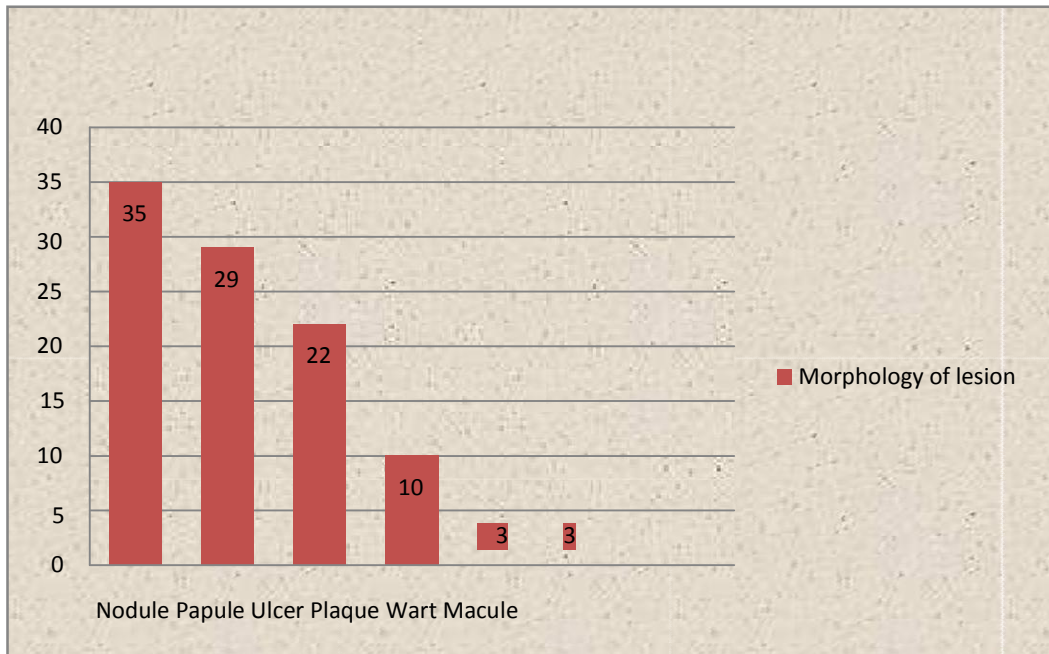


Chart 1. Morphology of lesion

Table 2. Nature of tumour

Nature	Number	Percentage
Benign	84	82.4%
Malignant	18	17.6%
Total	102	100%

Table 3. Age distribution of tumours

Age group	Number	percentage %
0-20	12	11.7%
21-40	43	42.2%
40-61	37	36.3%
>61	10	9.8%
Total	102	100%

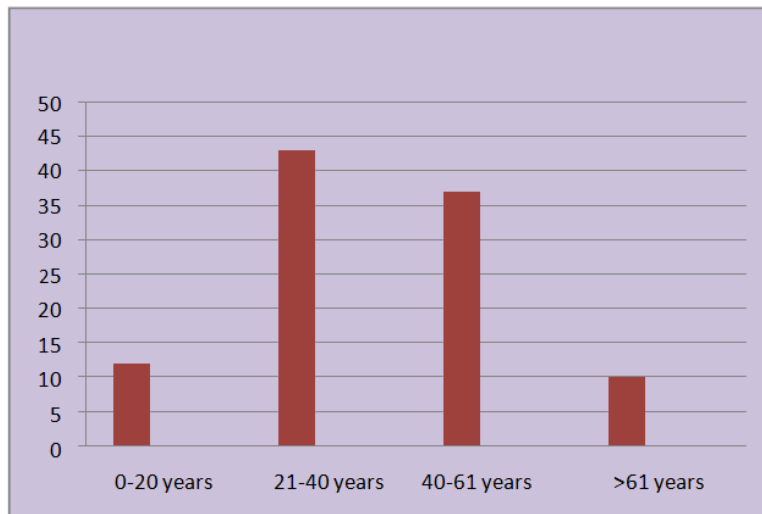


Chart 2. Age distribution

Table 4. Sex distribution

Sex	Number	Percentage
Male	51	50%
Female	51	50%
Total	102	100%

Out of 102 cases studied there were 51(50%) male patients and 51(51%) female patients.

Based on the WHO classification the sample size was categorised into groups as given in Table 5. It could be inferred that 31.4 % of the total sample were keratinocytic, 26.4% were appendageal, 7.8% were melanocytic, 0% hematolymphoid, 27.4% were soft tissue and 7% were of neural origin.

Keratinocytic tumours constitute 32% of total neoplastic lesions Of which 18 were benign and 14 were malignant. These tumours showed male preponderance and increased incidence in the age group between 40 and 61 years. Face is the commonest site of occurrence. Ulcerative lesions were malignant in nature [10].

Seven cases of seborrhoeic keratosis were seen in our study with acanthotic type being the

commonest variant. Three cases were seen in males and four cases in females. These lesions were seen in the head and neck region in the form of papules. Histologically the lesions showed epidermis with hyperkeratosis, acanthosis, papillomatosis and invaginations forming numerous horn cysts. The tumours were symmetric at the level of epidermis. The tumours were composed of basaloid cells. Four Cases of Squamous cell carcinoma were observed in our study. One case of squamous cell carcinoma was located in the anterior abdominal wall which is a rare site [11-15]. Two cases were observed in males and two cases in females. Histologically other the lesions showed epidermal proliferation with full thickness cellular atypia, hyperchromatic nuclei and absence of intercellular bridges, keratin pearl formation and zonal necrosis. Two cases were moderately differentiated whereas two cases were poorly differentiated [16].

Table 5. Sample analysis among various groups

Type of neoplasm	Total no of cases	Percentage
Keratinocytic	32	31.4%
Appendageal	27	26.4%
Melanocytic	8	7.8%
Hematolymphoid	0	0%
Soft tissue	28	27.4%
Neural	7	6.8%
TOTAL	102	100%

Table 6. Keratinocytic tumours

Malignant tumours	Number of cases	% of total
Basal cell carcinoma	8	25%
Squamous cell carcinoma	4	12.5%
Verrucous carcinoma	2	6.25%
Benign tumours		
Seborrheic keratosis	7	18.75%
Keratoacanthoma	6	9.37%
Squamous papilloma	5	9.37%
Total	32	100%

Two cases of Sebaceous Adenoma were encountered in our study. Both the tumours were seen in female patients. Histopathology showed incompletely differentiated sebaceous lobules with two types of cells. Periphery of the lobules from undifferentiated basaloid cells and mature sebaceous cells constitute the second type.

There were eight melanocytic tumours which constitute 7.8% of total neoplasms. Of all the melanocytic lesions 25% lesions were Common acquired melanotic nevi, 37.5% were Blue nevi and 37.5 % cases were Malignant Melanoma. Two cases of melanocytic nevi were observed in the study. One case of intradermal nevus observed in our study, showed nevus cells that appeared spindle shaped, arranged in bundles, embedded in collagenous fibres forming neuroid tubes situated within the dermis. One case of junctional nevi was observed in our study. Histology showed nests of nevus cells confined to the epidermis, with nests mainly located to the tips of rete ridges [17].

Three cases of blue nevi were observed in our study Two lesions were seen in males and one lesion was observed in female. Two lesions were common Blue Nevus and the other lesion was Cellular Blue Nevus. Microscopically, Common Blue nevi were characterized by dermal proliferation of elongated, dendritic melanocytes. Junctional activity was absent. Common Blue

Nevus resembles Nevus of Ota and Nevus of Ito, due to the presence of bipolar melanocytes. It was distinguished from them by the presence of sclerosis and dermal melanophages. Cellular Blue Nevus showed two types of melanocytes, the dendritic melanocytes and plump oval melanocytes with abundant cytoplasm. Few mitotic figures were also noted [18].

There were three cases of Malignant melanoma observed in the study. Two were nodular lesions and one was an ulcerated lesion. Microscopically all were characterized by prominent melanin pigmentation, junctional activity, invasion into surrounding tissue, marked cytologic atypia, nuclear grooves and inclusions, eosinophilic nucleoli and abundant mitosis. Clark system was used for assessing level of invasion [19].

Fibrous soft tissue tumours were 14 in number, with a female preponderance. These tumours were commonly found in extremities as nodules in the age group between 21 and 60 years.

Clinical diagnosis was compared with histopathological diagnosis taking Histopathological examination as the gold standard. Based on the clinical diagnosis 92 cases were benign and 10 cases were malignant. However histopathology proved 84 cases to be benign and 18 cases to be malignant in nature.

Table 7. Melanocytic tumours

Melanocytic lesions	Number	Percentage
Common acquired melanocytic nevi	2	25%
Blue nevus	3	37.5%
Malignant melanoma	3	37.5%
Total	8	100%

Table 8. Soft tissue fibrous tumours

Soft tissue fibrous - tumours	Number	Percentage
Cutaneous fibrous histiocytoma	4	28.6%
Fibroma	5	35.7%
Keloid	5	35.7%
Total	14	100%

Table 9. Comparative study between clinical diagnosis and histopathological diagnosis

Type of neoplasm	Total	Clinically benign	Clinically malignant	Hpe benign	Hpe malignant
Keratinocytic	32	24	8	18	14
Appendageal	27	26	1	26	1
Melanocytic	8	7	1	5	3
Soft tissue	28	28	0	28	0
Neural	7	7	0	7	0
TOTAL	102	92	10	84	18

Out of 32 keratinocytic tumours 24 were clinically diagnosed as benign and 8 tumours as malignant however histopathological examination showed 18 tumours to be benign and 14 tumours to be malignant in nature. Out of 8 melanocytic tumours 1 was clinically malignant however 3 lesions turned out to be malignant with histopathological examination.

Study of skin tumours was undertaken to observe the age and sex incidence, clinical presentation and histopathological examination in early and definite diagnosis and for prompt management of the cases. The study was carried out from April 2015 to September 2016. In the present study 102 skin biopsies were received in the department of Pathology, Sree Balaji Medical college, Chennai. The skin tumours in our study were more common in the age group between 20 - 41years (42.2%). The youngest patient was 12 years old and the oldest patient was 79 years old in our study. Narhire et Al and Sheenam et al observed male predominance. No significant sex gender difference was observed while considering all the 102 skin tumours. Keratinocytic and melanocytic tumours showed male predominance whereas appendageal, soft tissue and neural tumours showed female predominance in our study [20-23].

There were 8 cases of melanocytic lesions in our study. Benign lesions outnumbered malignant lesions. However Hussain et al.

observed more malignant lesions in their study [24]. Crasta J et al. reported 53.84% cases in the age group of 61-80 year with a M:F ratio of 1.2:1. Youl PH et al reported 52.41% of the total cases in >50 years age group and M:F ratio of 1.4:1 [25]. However our study showed that 62.5% cases were in the age group between 20-41years with a male: female ratio of 1.5:1. Our study revealed head and neck involvement in 63.64% cases, lower extremity in 22.73% and trunk in 13.64% cases. Crasta J et al reported head and neck involvement in 70% cases, trunk in 20% and lower extremity in 10% cases. Youl PH et al reported a higher percentage of lesions on the trunk (46.14%). The present study included 3 cases of malignant melanoma. Histologically, all lesions showed junctional activity at dermoepidermal junction. Both epithelioid and spindle cells were seen. One case belonged to stage two while the other cases were in stage three of Clarks staging system [25,26].

We had analyzed 102 cases of skin tumors in our study of which 84 were benign 82.4% and 18 were malignant 17.6% by histopathological examination. Most tumors were in the age group between 20 -41 years (42.2%) in our study. No sex predilection was seen while considering all the skin tumours (M:F-1:1), however keratinocytic and melanocytic tumours showed male predominance while appendageal, soft tissue and vascular tumours and neural tumours showed female predominance. Most of the skin

tumours were Nodular lesions (34.3%), followed by papular lesions (28.4%) and by ulcerated lesions (9.8%). Malignant tumours commonly presented as ulcerated lesions. Head and neck

region was the most common site of occurrence followed by extremities and trunk. Keratinocytic (31.4%) tumours were the commonest group among all skin tumours.

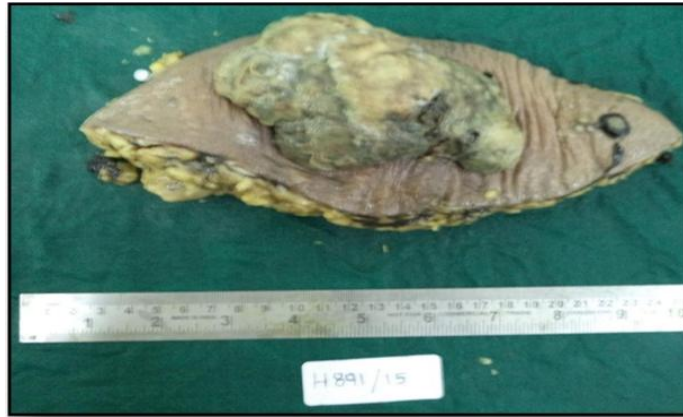

Fig. 1. GROSS: Showing ulceroproliferative lesion overlying skin with a pigmented satellite nodule

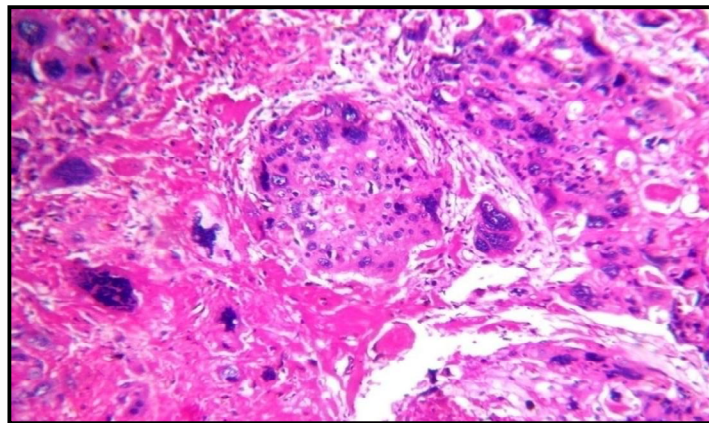


Fig. 2. HPF (400X) :H&E: dysplastic epithelium with malignant k eratin pearl

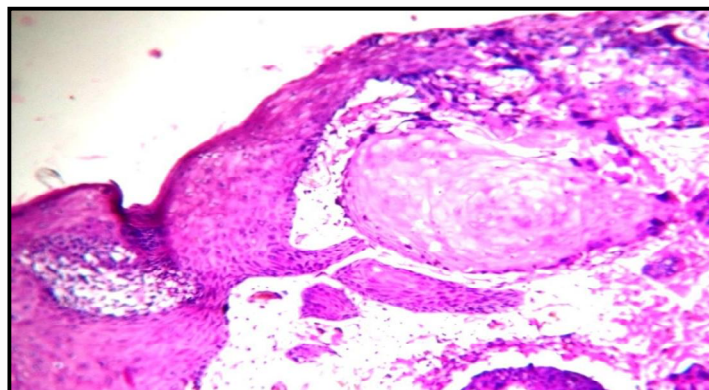


Fig. 3. HPF (400X): H&E: Tumour giant cells with numerous atypical mitotic figures

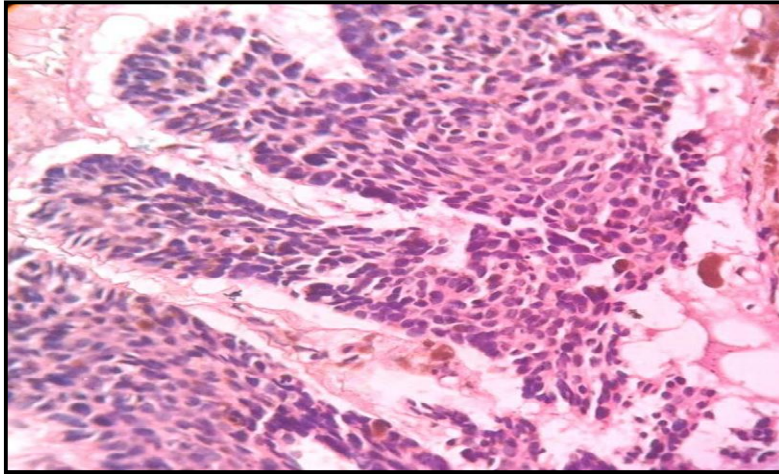


Fig. 4. HPF (400X): H&E: Nests, cords and islands of basiloïd cells showing characteristic peripheral palisading

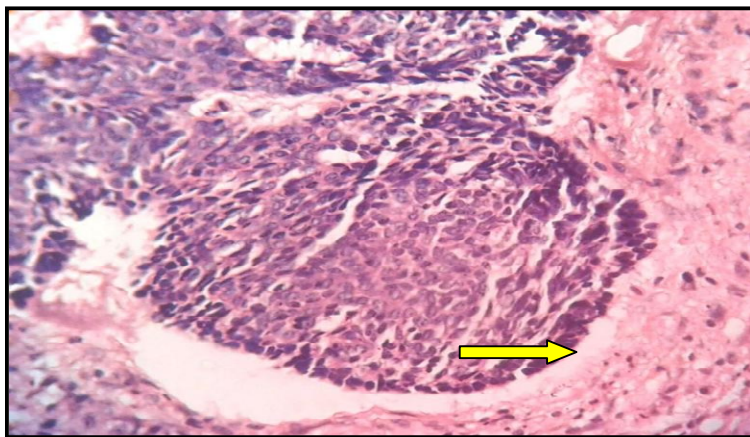


Fig. 5. HPF (400X) :H&E: Showing characteristic retraction artefact

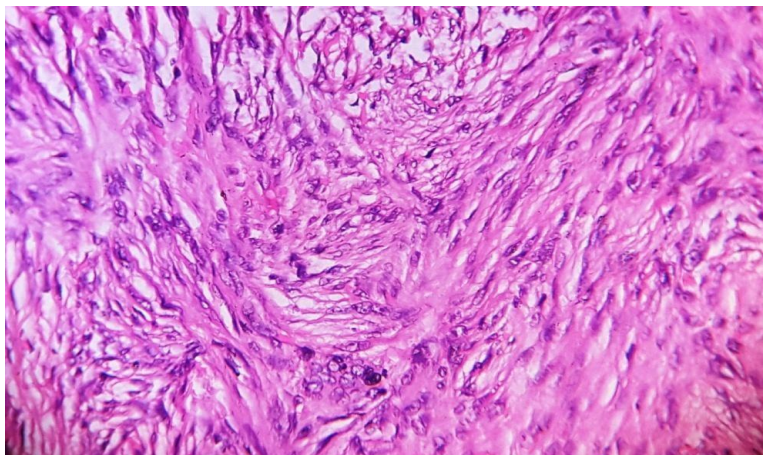


Fig. 6. HPF (400X): Spindle shaped cells with elongated nuclei with eosinophilic cytoplasm arranged in fascicles & Storiform pattern-dermatofibroma

4. CONCLUSION

Benign appendageal tumours (96.29%) outnumbered malignant appendageal tumours. (3.71%) Pilomatrixoma was the commonest benign appendageal tumour. Malignant melanoma constituted 37.5% melanocytic lesions. Neurofibroma (100%) was the commonest neural tumour encountered in our study. The diagnoses of malignant skin tumours were straightforward and problems were encountered in diagnosing adnexal tumours. Histopathological examination remains the gold standard in diagnosing most skin tumours. Thus diagnosis of any skin tumor can be done by correlating clinical features and histological features, which in turn can be supported by histochemistry, immunohistochemistry and electron microscopy.

CONSENT

As per international standard or university standard, patients' written consent has been collected and preserved by the author(s).

ETHICAL APPROVAL

The study was approved by the Institutional Ethics Committee

COMPETING INTERESTS

Authors have declared that no competing interests exist.

REFERENCES

1. Ackerman, Juan Rosai. Text Book of Surgical Pathology. 2011;10(1):132-136.
2. Bari V, Sulhyan K, Murakar P, Gosavi A. Skin tumours- Histopathological review of 125 cases. Ind Med Gaz. 2014;418-427.
3. Berman A, Winkellmann RK, Inflammatory Seborrhic Keratosis with mononuclear cell infiltration. J Cutaneous Pathol. 1978;5: 353-367.
4. Brenner M, Hearing VJ. The protective role of melanin against UV damage in human skin. Photochemistry and photobiology. 2008;84(3):539-49.
5. Bhawan J. Pilar sheath acanthoma. J Cutan Pathol. 1979;6:438-50.
6. Brodin B, Mehregan AH, Brownstein MH. Shapiero L. Pilosebaceous Tumors. Int J Dermatol. 1977;16:340-352.
7. Burg G, Kempf W, Cozzio A, Feit J, Willemze R, S Jaffe E, Dummer R, Berti E, Cerroni L, Chimenti S, Diaz-Perez JL, et LJ Cutan Pathol. 2005;32(10):647-74.
8. Byers HR, Bhawan. Pathologic parameters in the diagnosis and prognosis of primary cutaneous melanoma Hematol Oncol Clin North America. 1998;12(4):717-35.
9. Cannon JR. Schneider; recent developments in adnexal pathology in Moschella SM dermatol update, New York. Elseiver Publisher. 1982;236.
10. Hashimoto K, Fisher BK, Lever WF: Histogenesis of appendageal tumours .Arch Dermatol. 1969;6:100-359.
11. Hazel J Vernon, Elisa A. Oslan, Robin J. Vollmer. Autosomal dominant multiple cylindromas associated with solitary lung cylindromas. J Am Acad Dermatol. 1988; 2:397-400.
12. Headington JT. Mixed Tumors of Skin: Eccrine and Apocrine Types arch Dermatol. 1961;84:989-991.
13. Helwig EB, Hackney VC. Syringadenoma papilliferum. Arch Dermatol. 1955;71:361-77.
14. Hervella Vascular Tumors as a syndromic Indicators Eu J Cancer. 2004;27:33-44.
15. Hirsch P, Helwig EB. Chondroid Syringoma; Arch Dermatol. 1961;84: 835.
16. Hugo NE, Tulenkov F. Carcinoma of skin, in surgery of Tumors of skin 2nd Edn. Charles C. Thomas. 1966;165.
17. Hunt SI Vascular tumors of Skin, a selective review Semin diagnostic Pathol 2014;21(3):166-218.
18. Hussein MR. Melanocytic dysplastic nevi occupy the middle ground between Benign melanocytic. Nevi J Clinical Pathol. 2005; 58(5):111 -123.
19. Johnson WC. Pathology of cutaneous vascular tumors. Int Dermatol. 1976;15(4): 239- 70.
20. Joost J, Van den oord perivascular spaces in eccrine Spiradenoma; A clue to histological Diagnosis; AmJ Dermatopath. 1995;17(3):266-270.
21. Julien LG, Bover PW, A clinical review of 209 pilomatricomas. J Am Acad Dermatol. 1998;39:191-195.
22. Ken Hashimotos, Tumors of Skin Appendages in Fitzpatrick Dermatology in Genera Medicine, Fitzpatrick TB 5 th edn Mc Grawhill. 1999;5:890-914.
23. Kerl H. What is the boundary that separates a thick Solar Keratoses and a

- Squamous cell carcinoma. Am J Dermatopathol. 1984;6:305-311.
24. Komu J, Wateanbe S. Desmosome like structures in the cytoplasm of normal Keratinocytes. Arch Dermatol. 1975;3:245-402.
25. Levi F, Br J Cancer. Trends of Skin Cancer in Carton of Vaud. 1976-92; 72(4):1047-53.
26. Mac Donald DM, Wilson Jones E, Marks R. Sclerosing epithelial hamartoma. Clin Exp Dermatol.1977;2:153-67.

© 2021 Rekha and Srivastava; This is an Open Access article distributed under the terms of the Creative Commons Attribution License (<http://creativecommons.org/licenses/by/4.0>), which permits unrestricted use, distribution, and reproduction in any medium, provided the original work is properly cited.

Peer-review history:
The peer review history for this paper can be accessed here:
<http://www.sdiarticle4.com/review-history/66775>