



Assessment of the Woundy Healing Activity of the Aqueous Extract of Leaves of *Diospyros hoyleana* (F.) White (Ebenaceae)

**Simone Veronique Fannang^{a*}, Antoine Vayaraï Manaoda^b,
François Eya'ane Meva^b, Gisele Etame Loe^a,
Benoit Deschamps Mbida Mvomo^a, Jacques Yinyang^b
and Jean pierre Ngené^a**

^a *Laboratory of Organic Chemistry and Pharmaceutical Sciences, Faculty of Medicine and Pharmaceutical Sciences, The University of Douala, P. O. Box 2701, Cameroon.*

^b *Laboratory of Analytic Chemistry and Toxicology, Faculty of Medicine and Pharmaceutical Sciences, The University of Douala, P.O. Box 2701, Cameroon.*

Authors' contributions

This work was carried out in collaboration among all authors. All authors read and approved the final manuscript.

Article Information

DOI: 10.9734/JAMMR/2022/v34i1631405

Open Peer Review History:

This journal follows the Advanced Open Peer Review policy. Identity of the Reviewers, Editor(s) and additional Reviewers, peer review comments, different versions of the manuscript, comments of the editors, etc are available here: <https://www.sdiarticle5.com/review-history/87220>

Received 06 March 2022

Accepted 13 May 2022

Published 21 May 2022

Original Research Article

ABSTRACT

Wounds are an extremely common reason for consultation in emergency departments. They mostly result from traffic accidents but also of different traumatism. Their healing is possible thanks to a natural, spontaneous and coordinated process set up by the body. This process can be accelerated by the use of synthetic, biosynthetic or natural healing agents. Indeed, many medicinal plants are endowed with healing properties such as *Diospyros hoyleana* F. White, whose leaves help in the management of wounds. The present study consists in carrying out a phytochemical screening, evaluating the acute toxicity (oral and cutaneous) and determining the healing activity of the aqueous extract of *Diospyros hoyleana* leaves in comparison with that of BIAFINE®.

A phytochemical screening was carried out in order to highlight the presence of secondary metabolites responsible for the healing activity. Acute oral and cutaneous toxicity tests were carried out on different batches of rats. Subsequently, the evaluation of the healing activity by

*Corresponding author: E-mail: verofanns@yahoo.fr;

induction of traumatic lesions on batches of rats was made. The evolution of wounds of the different batches was compared on the one hand by calibrated photography and on the other hand by histological analysis.

At the end of this study, the results show that the aqueous extract of *Diospyros hoyleana* leaves has a healing activity with a healing profile at doses of 100 and 200 mg/kg similar to that of BIAFINE.

The aqueous extract of *Diospyros hoyleana* leaves has healing activity with a healing profile similar to that of trolamine at doses of 100 mg/kg and 200 mg/kg. Flavonoids or tannins could be responsible for this activity.

Keywords: *Diospyros hoyleana*; wound healing; rats; refined.

1. INTRODUCTION

A wound is an interruption in the continuity of a body tissue, a break in the skin barrier [1]. Wounds are seemingly banal pathologies that can pose complex therapeutic problems and thus constitute an extremely frequent reason for consultation in emergency departments [2]. This life event can occur in several contexts: surgeries, burns, radiation, cuts, tears and scrapes [3].

The healing of a cutaneous wound is a natural, spontaneous and coordinated process called cicatrization, which consists of tissue regeneration in the event of an injury. It involves cell multiplication, active cell migration and the production of the extracellular matrix. The speed of healing of a wound as well as the quality of the scar depends on the general state of the organism. This speed can be increased by the use of healing agents.

A wound healer accelerates healing by acting on one or more stages of it. Despite the existence of a multitude of healing products whose effectiveness is established, the fact remains that patients are increasingly using the resources of traditional medicine as an alternative to conventional treatment [4]. Many plants have been shown to possess therapeutic potential as wound healing promoters, for example, *Aloe vera*, *Tetrapleura tetraptera* and *Baphia nitida* [5, 6, 7].

Diospyros hoyleana from the Ebenaceae family is a plant used in traditional medicine. The use of remedies made from the leaves of *Diospyros hoyleana* in the treatment of wounds is common. However, this therapy and the toxicity of this plant have not yet been subjected to scientific evaluation criteria as has been the case for other plants.

The study aims to establish on the one hand the acute toxicological profile of *Diospyros hoyleana* leaves and on the other hand to measure this healing activity by comparison with that of BIAFINE (Trolamine) while identifying the families of secondary metabolites responsible for this activity.

2. METHODOLOGY

2.1 Plant Material

The plant material used for the work carried out was the leaves of *Diospyros hoyleana* F.White harvested in the Littoral Region, Department of Mounjo more precisely in Dibombari in a forest environment on humid and sandy soil. This plant was identified at the National Herbarium of Cameroon in the city of Yaoundé compared to sample No. 1745/ HNC by G.A. Zenker collected in 1898.

2.2 Preparation of the Aqueous Extracts

The aqueous extract of this study was obtained by maceration.

500 g of powdered drug were weighed, this powder was directly macerated in 2.5 L of distilled water for a period of 48 hours to obtain the aqueous extract. This operation was repeated three times to maximize the extraction. At the end of this operation, the filter obtained was brought to a water bath at a temperature of 60° c.

The total extract obtained was weighed to calculate the yield and then stored in the refrigerator at 4°C for subsequent experimental tests.

The acute oral toxicity study was conducted according to the modified guideline 423 of the Organization for Economic Co-operation and Development (OECD).

Table 1. Leaves extraction yields and extract aspect

Extract type	Powder mass (g)	Extract mass (g)	Yield (%)	Aspect
Aqueous	500	64	12.8	Sticky, oily, dark brown paste

The acute dermal toxicity study was conducted according to guideline 402 of the Organization for Economic Co-operation and Development (OECD).

2.3 Phytochemical Screening

2.3.1 Phenol test

2 ml of extract were placed in a test tube and 1 ml of 5% ferric chloride was added. The appearance of a thick blackish-blue color indicates the presence of phenols.

2.3.2 Shinoda test

The dry extract was dissolved into 3 ml of methanol, and a few shavings of magnesium were added, followed by 5 drops of hydrochloric acid. The appearance of a purple or red-orange color indicates the presence of flavonoids.

2.3.3 Liebermann Burchard test

A small amount of dry extract was dissolved in a few drops of chloroform. A few drops of acetic anhydride were added, followed by sulfuric acid. A purple color that turns green indicates the presence of a sterol. An initial brick-red coloration that turns purple indicates the presence of a triterpene.

2.3.4 Dragendorff test

The Dragendorff's reagent was prepared by mixing a concentrated solution of potassium iodide (8g of KI with 200 ml of distilled water) with an equal volume of a bismuth (III) nitrate solution (0.85g of Bi(NO₃)₃ in 100 ml of distilled water and 10 ml of acetic acid) and adding 100 ml of distilled water to 10 ml of this mixture, as well as 100 ml of acetic acid.

A small quantity of the extract was dissolved in methanol. The presence of alkaloids was materialized by the appearance of a precipitate when adding the Dragendorff's reagent or spraying a TLC plate. The color of the precipitate varied between yellow, orange, red and brown, depending on the nature of the alkaloid.

2.3.5 Bornstrager test

By adding 1 ml of 25% ammonia to an equal volume of methanolic extract. The appearance of a red coloration indicates the presence of anthraquinones.

2.3.6 Tannin test

The reagent used was 5% ferric chloride (FeCl₃). In a test tube, 2 ml of extract was introduced, then 1 ml of FeCl₃ solution. The appearance of a bluish to black color indicated the presence of tannins.

2.3.7 Saponin test

A small amount of dry extract was dissolved in 1 ml of distilled water. The aqueous solution obtained was subjected to energetic stirring for 3 seconds. The presence of saponins results in the formation of a thick foam which persists for about 30 minutes.

2.4 Assessment of the Wound Healing Activity of the Leaves Aqueous Extract of *Diospyros hoyleana* (F.) White (Ebenaceae)

Within the framework of this experiment, the induction of general anesthesia of the rats was carried out according to the protocol of anesthesia of the rodent n° ANE-02 of December 6, 2000. The wound healing activity was assessed macroscopically and microscopically.

3. RESULTS

3.1 Leaf Extraction Yields and Extract Aspect

Table 1 shows the physical characteristics and the extraction yield of the extract. It appears from this table that a 12.8 % yield was obtained from a 64 g extract mass. The extract was sticky, oily, pasty and dark brown.

3.2 Phytochemical Screening

The phytochemical screening of the aqueous extract of *Diospyros hoyleana* F.White leaves revealed the presence of secondary metabolites as shown in Table 2.

Table 2. Result of phytochemical screening

Identification test	Aqueous extract
Alkaloids	-
Sterols	-
Flavonoids	+
Saponins	+
Phenols	+
Tannins	+
Terpenes	-
Coumarins	-
Anthraquinones	+

+ : Presence ; - : Absence

3.3 Assessment of Acute Oral Toxicity

3.3.1 Determination of lethal dose 50

The acute oral toxicity of the aqueous extract of *Diospyros hoyleana* leaves was studied after oral administration of a single dose of the extract at 50,300, 2000 and 5000 mg/kg in rats. After 14

days of observation, no death was observed in the treated animals, which did not allow the determination of the LD50.

3.3.2 Behavioral studies

Oral administration of a single dose of 50, 300, 2000 and 5000 mg/kg of the aqueous extract of *Diospyros hoyleana* leaves did not cause more or less significant changes in rats. No signs of toxicity (Table 3) such as a decrease in sensitivity to pain and noise and a decrease in locomotion were observed.

3.3.3 Effects of the aqueous extract of *Diospyros hoyleana* on the rats biomass during acute toxicity

It appears from Fig. 1 that there is an increase in rat biomass for all the treatments as a function of time.

Table 3. Acute oral toxicity

Criteria	Control	50mg/kg	300mg/kg	2000mg/kg	5000mg/kg
Grooming	N	N	N	N	N
Coat	N	N	N	N	N
Trembling	N	N	N	N	N
Motility	N	N	N	N	N
Reaction to noise	N	N	N	N	N
Salts aspect	N	N	N	N	N
Number of deaths	0	0	0	0	0

N= Normal

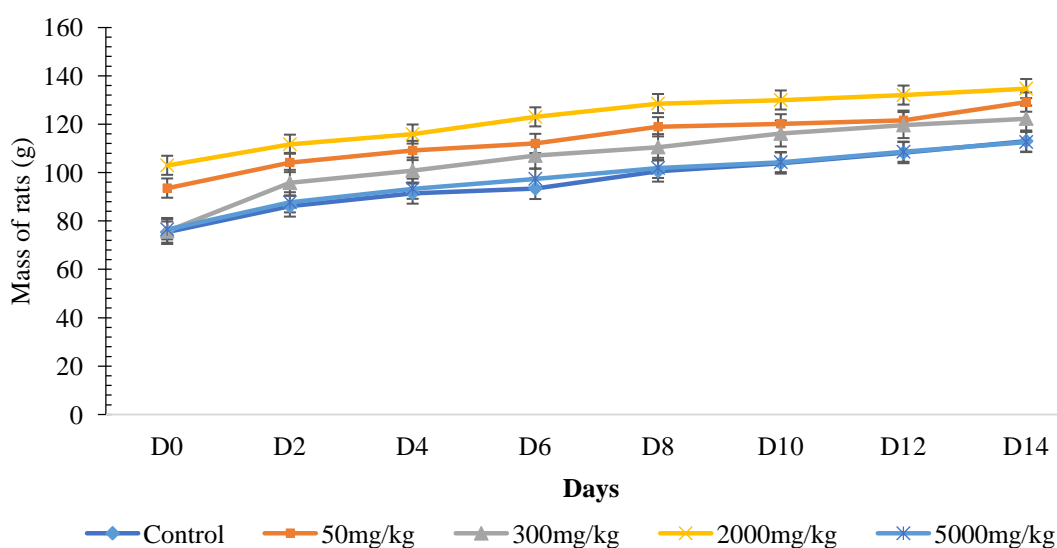


Fig. 1. Evolution of the mass of rats during acute oral sensitivity

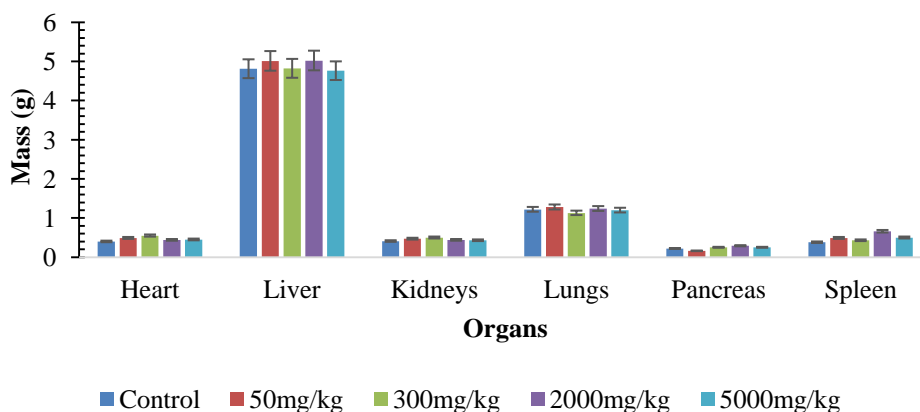


Fig. 2. Biomass of the rat organs as a function of treatments

Table 4. Effects of the aqueous extract of *Diospyros hoyleana* leaves on biochemical parameters during acute toxicity tests depending on the dose

Groups	UREE (mmol)	Creatinine (mmol)	ALAT (UI/l)	ASAT (UI/l)
Control	2.56 ± 0.30	25.20 ± 7.70	20.00 ± 4.35	63.33 ± 7.638
50 mg/kg	2.53 ± 0.56	25.33 ± 10.07	22.33 ± 7.50	61.67 ± 14.19
300 mg/kg	2.73 ± 0.32	23.33 ± 10.12	18.67 ± 3.51	58.33 ± 18.93
2000mg/kg	3.46 ± 0.45*	26.33 ± 3.21	22.33 ± 3.78	67.33 ± 8.021
5000mg/kg	2.86 ± 0.05	28.33 ± 12.01	22.00 ± 6.24	59.33 ± 10.50

*: low significant difference (p-value<0.05)

3.3.4 Effects of aqueous extract of *Diospyros hoyleana* on organ mass of rats during acute oral toxicity

After 14 days of observation, the rats were sacrificed and certain organs weighed. The weights of the organs are represented in the table coupled with the comparative diagram of the masses of the organs of the rats Fig. 2. There is no significant difference (p-value < 0.05) between the organs of the control and those of the other treatments.

3.3.5 Evaluation of biochemical parameters

The effect of the administration of the aqueous extract on the biochemical parameters of the animals is presented in Table 4.

A significant difference (p-value < 0.05) was observed between the production of UREE of the control and the 2000 mg/kg dose.

3.4 Assessment of Acute Dermal Toxicity

3.4.1 Determination of lethal dose 50

The acute dermal toxicity of the aqueous extract of *Diospyros hoyleana* leaves was studied after

oral administration of a single dose of the extract at 200, 1000 and 2000 mg/kg in rats. After 14 days of observation, no death was observed in the treated animals, which did not allow the determination of the LD50.

3.4.2 Behavioral studies

Dermal administration of a single dose of 200, 1000 and 2000 mg/kg of the aqueous extract of *Diospyros hoyleana* leaves did not cause more or less significant changes in rats. No signs of toxicity such as irritability were observed (Table 5).

3.4.3 Effects of the aqueous extract of *Diospyros hoyleana* on the mass of rats during acute dermal toxicity

Animals biomass generally increased over time for all the treatments.

3.4.4 Effects of aqueous extract of *Diospyros hoyleana* on organ mass of rats during acute dermal toxicity

No statistically significant difference (p-value < 0.05) is noted between the organs of the control treatment and those of the other treatments.

The diagram coupled with the comparative table acute toxicity study makes it possible to illustrate the masses of the organs of the rats after the the masses of the organs weighed in Fig. 3.

Table 5. Observation of clinical parameters during acute cutaneous toxicity

Criteria	Control	200mg/kg	1000mg/kg	2000mg/kg
Grooming	N	N	N	N
Coat	N	N	N	N
Trembling	N	N	N	N
Irritability	0	0	0	0
Reaction to noise	N	N	N	N
Aspect of salts	N	N	N	N
Number of death	0	0	0	0

N= Normal; 0=Absence

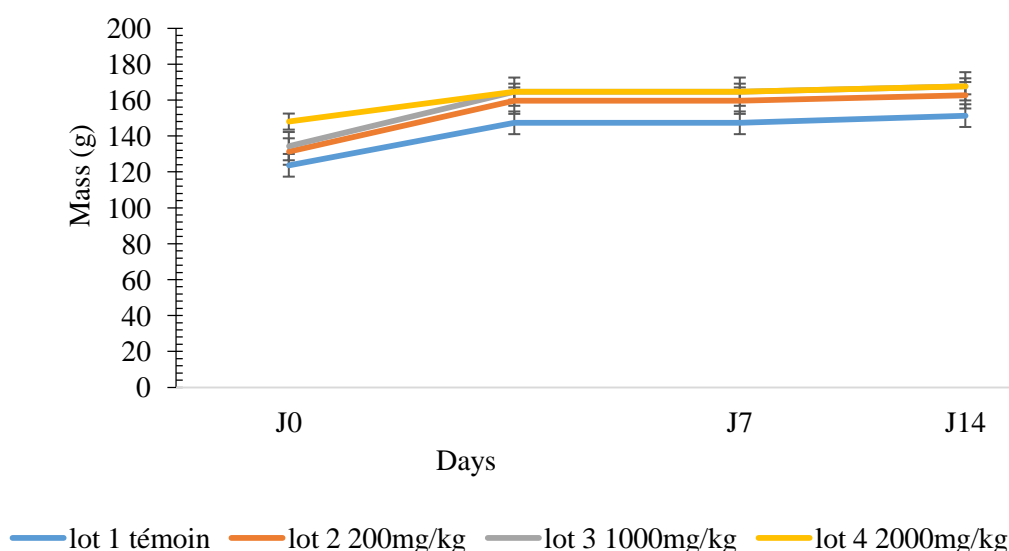


Fig. 3. Evolution of the mass of rats after acute skin toxicity study

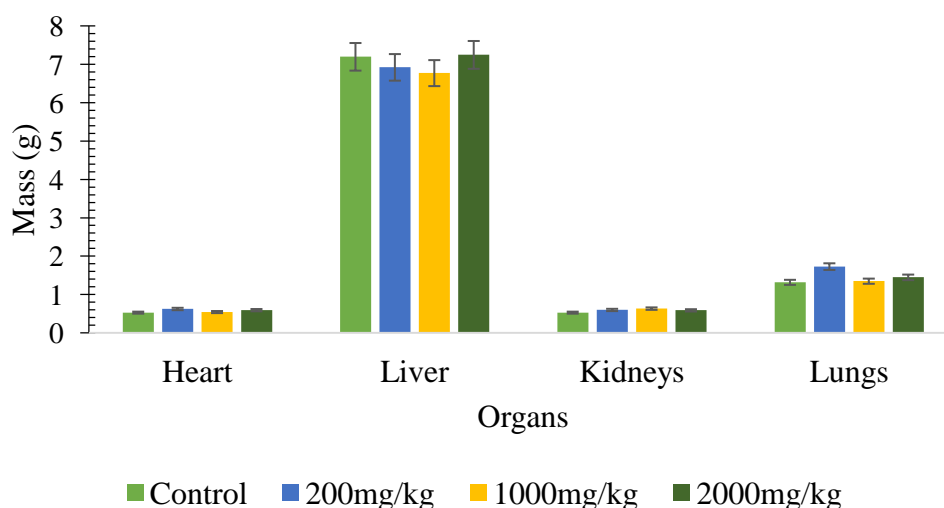


Fig. 4. Diagram of the masses of the organs after acute cutaneous toxicity

3.5 Results of the Wound Healing Activity Tests

3.5.1 Simple clinical observation

3.5.1.1 Evolution of wound healing

Table 6. Clinical observation of wounds

Days	Batches	Comments
D0-D2	All	No crust formation in all rats. The shapes of the lesions are perfectly distinguished.
D4	All	Beginning of the appearance of crusts in some rats, the shapes of the lesions are largely distinguished.
D6-D8	All	Presence of a consistent crust in all the rats, with progressive disappearance of the shapes of the lesions.
D10	1,2,3,4	Onset of decrease in wound size in some rats
	1, 2, 4	Beginning of disappearance of crusts in some rats.
D12-D14	All	Significant decrease in wound size in some rats across all treatments.
	All	Disappearance of crusts in all rats. Lesions virtually disappeared in some rats
D16	1, 2, 4	Disappearance of lesions in all rats.
D18-D20	All	Disappearance of lesions in all rats.

3.6 The Results of the Clinical Observation are Described According to the Treatments

Hypothesis 1: Reject hypothesis 0.

3.6.1 Graphic evolution of the images of the different batches

The measurements taken by the calibrated photography technique have been transcribed in Fig. 5.

The hypothesis test used is a test based on the analysis of variance with 1 ANOVA 1 parameter (the parameter taken into account is the healing time). Two hypotheses were put forward in order to compare the healing kinetics of the different batches.

3.6.2 Analysis of the evolution of the wounds of the rats of all the batches over the days

During the first 6 days have the same speed of healing;

Hypothesis 0: the scar profiles of the batches analyzed are equivalent for the period considered.

From the 8th day: an acceleration of healing was observed in the rats of batches 1, 2 and 4.

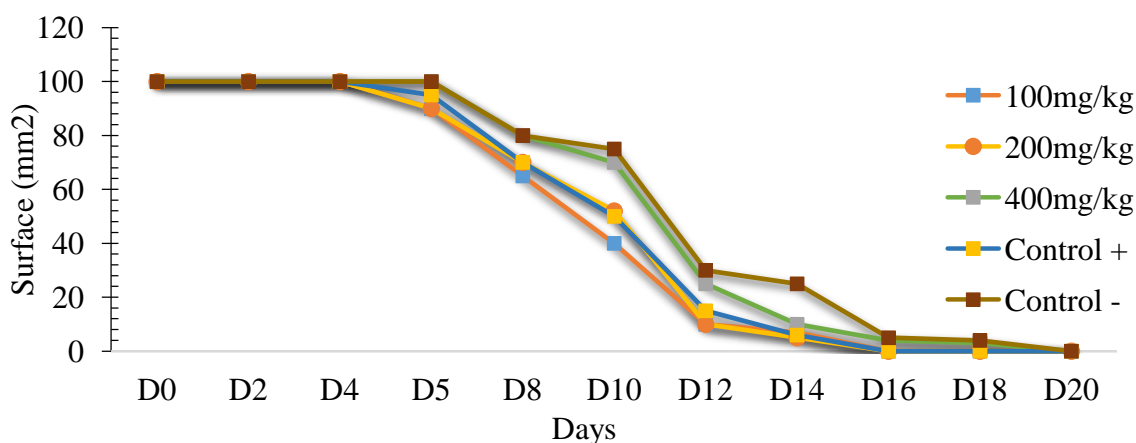


Fig. 5. Wound healing kinetics as a function of treatments

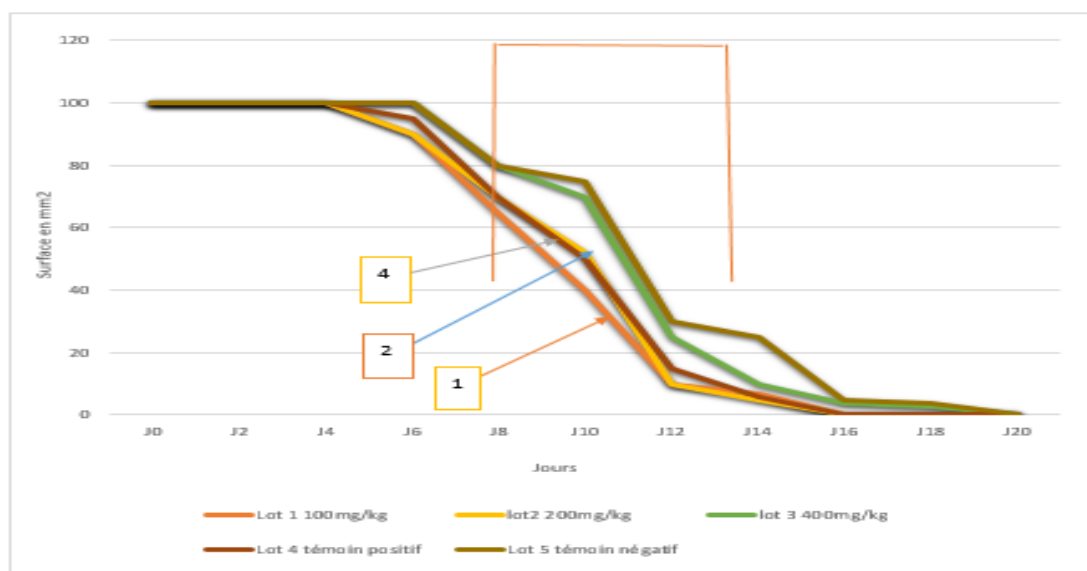


Fig. 6. Wound healing kinetics as a function of treatments and time

From the 10th day: an acceleration of the healing in the rats of batches 3 and 5 was observed in turn while the wounds of the rats of batches 1, 2 and 4 continue to decrease.

The ANOVA hypothesis test performed on all batches showed:

That there was no significant difference between the mean wound sizes during the first 6 days.

On the other hand, on the 8th day, we note: A significant difference between batches 1, 2 and 4 compared to the negative control (batch 5).

3.6.3 Analysis of the evolution of wounds in rats of batches 1, 2 and 4 over the days

Between the 8th and the 12th day the diameters of the wounds of the rats of batch 1 are lower than those of batches 2 and 4.

The ANOVA hypothesis test showed no significant difference for the time periods considered.

Treatments 100mg/kg and 200 mg/kg show the same scarring profile as that of batch 4 (BIAFINE®) from which hypothesis 0 is retained.

3.6.4 Analysis of the evolution of wounds in rats of batches 3 (400 mg/kg) and 4 (positive control)

During the first 6 days no difference between the evolution of the diameters of the wounds of the rats of the two batches;

Between the 8th and 18th day the diameters of the wounds of the rats of batch 4 are lower than those of the rats of batch 3.

The perceptible difference is confirmed by the ANOVA hypothesis test which notes a significant difference from the 8th day.

3.6.5 Analysis on batches 1, 2 and 5

Between the 8th and 10th day the lesions of batches 1 and 2 are relatively lower than those of batch 5 (control).

The perceptible difference is confirmed by the ANOVA hypothesis test which showed a significant difference for the time periods considered. The healing kinetics of batches 1 and 2 are therefore greater than that of batch 5 (negative control).

Hypothesis 1 is thus advanced.

3.6.6 Analysis of the evolution of wounds in rats of batches 3 (400 mg/kg) and 5 (negative control)

The wound healing rates between the two batches seem identical. However, the diameters of the wounds in the rats of batch 3 are those of the wounds of the rats of batch 5 between the 12th and the 16th day;

Despite the perceptible difference from the 12th to the 16th, the ANOVA hypothesis test did not show any significant difference for the time periods considered.

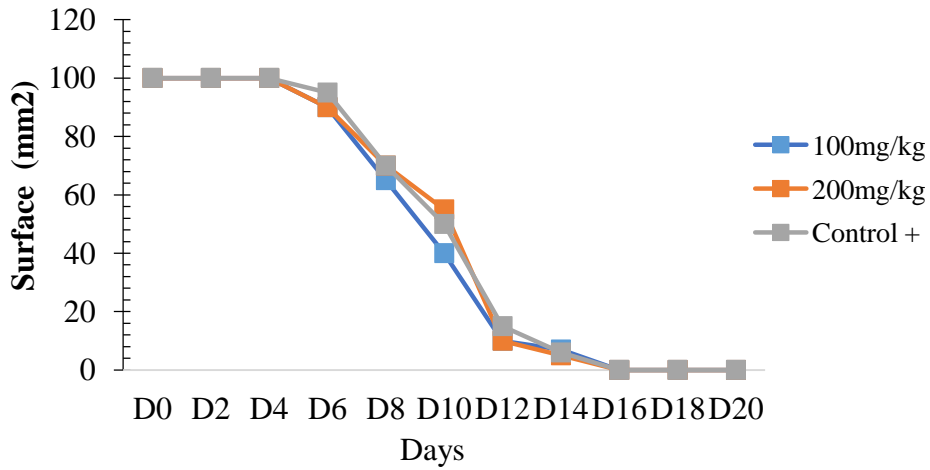


Fig. 7. Wound healing kinetics of treatments

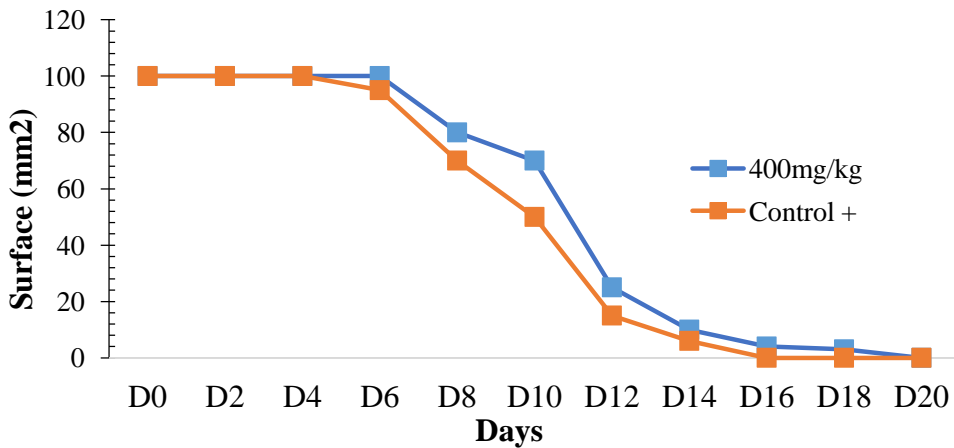


Fig. 8. Wound healing kinetics of batches 3 and 4

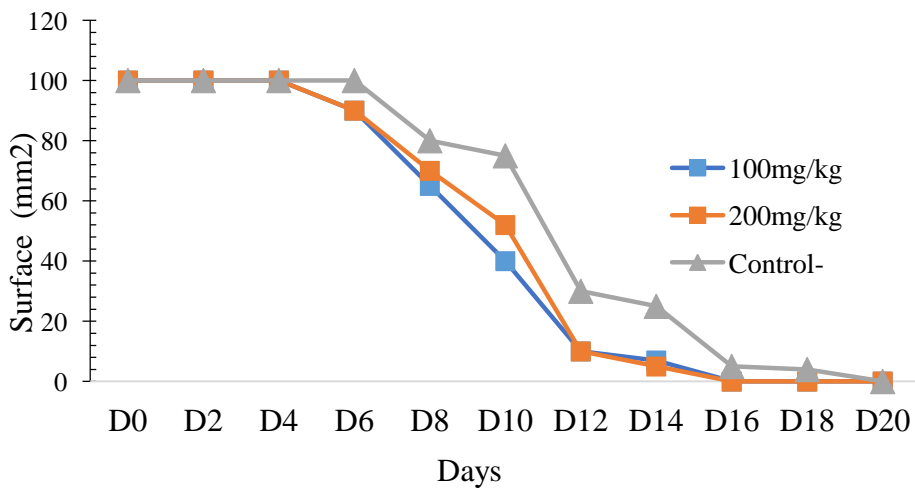


Fig. 9. Wound healing kinetics of batches 1, 2 and 5

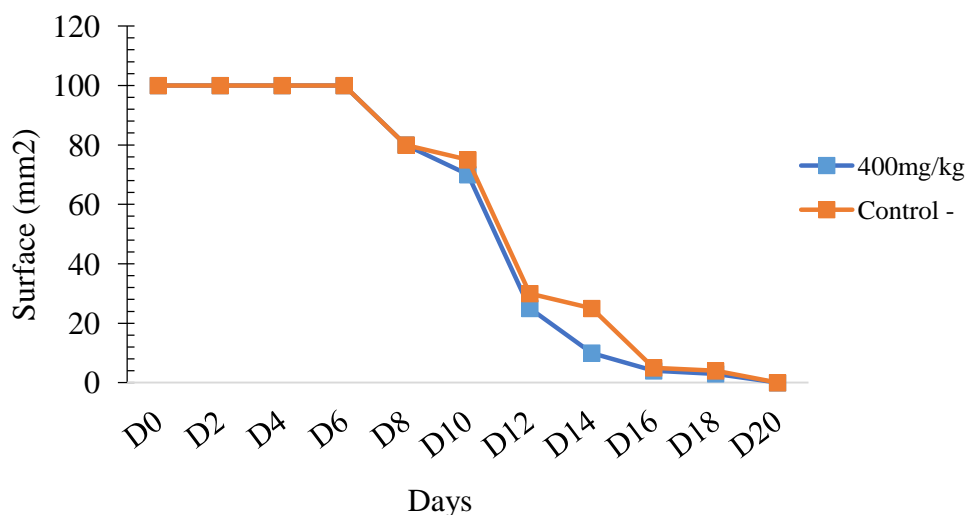


Fig. 10. Wound healing kinetics of batches 3 and 5.

4. DISCUSSION

During this study, the extraction rate of the aqueous extract of *Diospyros hoyleana* leaves was calculated in relation to the mass of the initial powder and represents 12.8%. Although this yield is low, this plant can nevertheless be used in the production of improved traditional medicines (MTA) in view of its multiple uses in traditional medicine.

Phytochemical screening of the aqueous extract of *Diospyros hoyleana* leaves revealed the presence of major secondary metabolites such as flavonoids, tannins, phenols, quinones and saponins. These results are in agreement with a few exceptions with those carried out by Burkill who revealed the presence of quinone alkaloids, saponins and tannins, but noted an absence of sterols, terpenes and flavonoids. The presence of these metabolites corroborates the multiple uses of this plant in traditional medicine more specifically, in headaches (flavonoids and saponins), in miscarriages (flavonoids, quinones and tannins) and in wound healing (flavonoids and tannins) [8].

The aqueous extract of *Diospyros hoyleana* leaves administered orally at doses of 50 mg/kg, 300 mg/kg, 2000 mg/kg and 5000 mg/kg did not cause any death throughout the study. The LD50 could therefore not be determined. The aqueous extract of *Diospyros hoyleana* leaves would have a toxicity index equivalent to 5, according to the toxicity scale of a chemical substance depending

on the LD50 and the route of administration [9]. However, no signs of toxicity were observed during the 4 hours following administration of the extract, in particular reduced sensitivity to the stimulus (pain and noise), reduced mobility or softening of the faeces.

According to the literature, reduction in body weight and internal organs are considered sensitive indices of toxicity after exposure to a toxic substance [10]. No significant variation in body weight and mass of internal organs was observed for the four treated batches compared to the control batch.

The administration of the aqueous extract of *Diospyros hoyleana* leaves did not cause any significant change in serum ALAT and ASAT activity in the 4 groups having received the doses of 50 mg/kg, 300 mg/kg, 2000 mg/kg and 5000 mg/kg of extract compared to the control batch. These results are therefore in favor of a non-hepatotoxic activity of the aqueous extract. This corresponds to the work done by Dally L and Coulibaly in 2007 [11].

The values of the nephretic parameters (urea and creatinine) of the batches having received the aqueous extract are normal. The aqueous extract leaves would therefore not be nephrotoxic.

The aqueous extract of *Diospyros hoyleana* leaves administered by the dermal way at doses of 200 mg/kg, 1000mg/kg and 2000 mg/kg did

not cause any deaths throughout the study. The LD50 by the dermal route did not could be determined. However, no signs of toxicity were observed during the 4 hours following administration of the extract, in particular signs of irritability.

Regarding to the evaluation of the wound healing, the observations showed that the wounds treated by the aqueous extract of leaves of *Diospyros hoyleana* are covered with crust before those of the negative control group. This presence of crust, which is a process of blood coagulation, is potentiated by the presence of polyphenols (tannins and flavonoids) in the aqueous extract [12].

The closure of the wounds of batches 1 (100 mg/kg), 2 (200 mg/kg) and 4 (BIAFINE®) is observed after 16 days against 21 days in the negative control batch and the batch at 400 mg/kg.

The intercomparison of the batches having received the aqueous extract of *Diospyros hoyleana* leaves shows that batch 1 (100 mg/kg) has a healing activity greater than that of batch 2 (200 mg/kg) which in turn has an activity greater than that of batch 3 (400 mg/kg). The healing efficacy of the aqueous extract of *Diospyros hoyleana* leaves would therefore increase towards low doses.

The comparison of batches 1 (100 mg/kg) and 2 (200 mg/kg) with the positive control (BIAFINE®) did not show any significant difference. Batches 1 and 2 would therefore have a scarring profile similar to that of batch 4 (BIAFINE®).

The comparison of batches 1 (100 mg/kg) and 2 (200 mg/kg) with the negative control batch 5 showed a perceptible difference on the evolution curves of the wounds. This difference is confirmed by the ANOVA test. Batches 1 (100 mg/kg) and 2 (200 mg/kg) have a healing activity greater than natural healing (batch 5: negative control).

Comparison of batch 3 (400 mg/kg) to the negative control (distilled water) showed no significant difference. Lot 3 (400 mg/kg) would therefore have a scar profile similar to natural scarring.

Histological observation revealed a strong presence of inflammatory cells in batches 1 and 2 compared to batches 3, 4 and 5. This is in

agreement with numerous works which have demonstrated that the plants traditionally used as healing possess immune system activating properties; this activation would be due to the presence of polyphenols, responsible for the healing of external wounds [13].

Thus, the presence of polyphenolic compounds (flavonoids, tannins) in the aqueous extract of *Diospyros hoyleana* leaves would justify its healing activity.

5. CONCLUSION

This work was centered on the ethnopharmacological study of the aqueous extract of *Diospyros hoyleana* leaves on rats (Wistar).

After obtaining the aqueous extract, the calculation of the yield was carried out followed by an identification by phytochemical screening of the different families of compounds present in this extract. The yield and phytochemical screening results obtained were compared to previous work and a major difference was noted. The study of the acute toxicity of aqueous extract of leaves of *Diospyros hoyleana*, after oral and cutaneous administration of a single dose, showed no sign of toxicity, neither on the behavior, nor on the evolution of the total weight, nor on the weight of the organs and also on the blood, liver and kidney parameters, carried out during acute oral toxicity with an LD 50 greater than 5000 mg/kg.

Regarding to the evaluation of the healing activity, a rapid appearance of consistent granulations was noted in the batches treated with the aqueous extract and BIAFINE® compared to the negative control batch. The wounds treated with the aqueous extract (at a dose of 100 mg/kg and 200mg/kg) and trolamine (BIAFINE®) close after 16 days against 21 days in the negative control batch and the batch at 400 mg/kg. The histological sections carried out on granulation tissues showed an abundant presence of polymorphonuclear in the 100 mg/kg and 200 mg/kg batches and trolamine against a moderate presence in the 400 mg/kg and negative control batches. These results show that the aqueous extract of *Diospyros hoyleana* leaves has healing activity with a healing profile similar to that of trolamine at doses of 100 mg/kg and 200 mg/kg. The flavonoids and tannins present in this aqueous extract would justify this activity.

CONSENT

It is not applicable.

ETHICAL APPROVAL

It is not applicable.

DISCLAIMER

The products used for this research are commonly and predominantly use products in our area of research and country. There is absolutely no conflict of interest between the authors and producers of the products because we do not intend to use these products as an avenue for any litigation but for the advancement of knowledge. Also, the research was not funded by the producing company rather it was funded by personal efforts of the authors.

COMPETING INTERESTS

Authors have declared that no competing interests exist.

REFERENCES

1. Li W, Dasgeb B, Phillips T, Li Y, Chen M, Garner W. et al. Wound-healing perspectives. *Dermatol Clin.* 2005;23(2):181-192.
2. Smith KL, Dean SJ. Tissue repair of the epidermis and dermis. *J Hand Ther.* 1998;95-104.
3. Diallo D, Sogn C, Samaké FB, Paulsen BS, Michaelsen TE, Keita A. Wound healing plants in Mali, the Bamako region. An ethnobotanical survey and complement fixation of water extracts from selected plants. *Phar Bio.* 2002;40:117-128.
4. Korotimi Dada Amadou K. Healing properties of the leaves of *Opilia celtidifolia* (Guill. et Perr.) Endl. Ex-Walp. (Opiliaceae)[Thesis]. Pharmacy: Bamako. 2009/2010;109.
5. Choi SW, Son BW, Son YS, Park YI, Lee SK, Chung MH. The wound-healing effect of a glycoprotein fraction isolated from Aloe vera. *Br J Dermatol.* 2001;145:535-545.
6. Tsala DE, Habtemariam S, Foyet HS, Bella NMT, Jital AA, Dimo T. Topically applied *Tetrapleura tetraptera* stem-bark extract promotes healing of excision and incision wounds in rats. *J of Intercultural Ethno [on line].* 2014;30 Mai [29/01/ 2014]:3(2):64. Available:www.jicep.com.
7. Dally L, Coulibaly S, Angnimel LH, Bamba M. Formulation, galenic, toxicological control and biogalenic testing of a cream with healing activity based on fresh leaves of *Baphia nitida* (Papilionaceae) [Thesis]. Pharmacy: Abidjan. 2007;33-40.
8. Burkill HM, The useful of west tropical Africa: Ebenaceae. Royal Botanic Gardens,kew, Richmond, United Kingdom. 2004;6(2):237-246.
9. Delongueas J, Burnel D, Netter P, Grignon M, Roger R, Grignon G. Toxicity and pharmacokinetics of *Zirconium oxychloride* in rats. *Journal of Pharmacology.* 1983;14:437-447.
10. Suriyavadhana M, Tpakutharivu P. Evaluation of acute and sub-acute toxicity of ethanol extracts of *Entada pursaetha*, *Toddalia aculeata*, and *Ziziphus mauritiana*. *World J Life Sci. and Medical Research.* 2011 ;1(2):43-47.
11. Dally L, Coulibaly S, Angnimel LH, Bamba M. Formulation, galenic, toxicological control and biogalenic testing of a cream with healing activity based on fresh leaves of *Baphia nitida* (Papilionaceae) [Thesis]. Pharmacy: Abidjan. 2007;33-40.
12. Biaye M. Pharmacologicals actions of tanins. Doctorat Theses in Pharmacy, Cheik. Anta. Diop. Univ. of Dakar (Sénégal). 2002;15-16.
13. Yamada H, Kiyohara H. Complement-activating polysaccharides from medicinal herbs. In *Immunomodulatory agents from plants.* H. Wagner, Birkhäuser, Basel. 1999;161-202.

© 2022 Fannang et al.; This is an Open Access article distributed under the terms of the Creative Commons Attribution License (<http://creativecommons.org/licenses/by/4.0>), which permits unrestricted use, distribution, and reproduction in any medium, provided the original work is properly cited.

Peer-review history:

The peer review history for this paper can be accessed here:

<https://www.sdiarticle5.com/review-history/87220>