



Anaesthetic and Histological Effects of Lidocaine Hydrochloride on *Oreochromis niloticus* Juveniles

O. V. Modede^a and T. S. Awopetu^{b*}

^a Department of Fisheries and Aquaculture Technology, The Federal University of Technology, Akure, Nigeria.

^b Department of Aquaculture and Fisheries Management, University of Ibadan, Nigeria.

Authors' contributions

This work was carried out in collaboration between both authors. Both authors read and approved the final manuscript.

Article Information

DOI: 10.9734/AJFAR/2022/v19i6478

Open Peer Review History:

This journal follows the Advanced Open Peer Review policy. Identity of the Reviewers, Editor(s) and additional Reviewers, peer review comments, different versions of the manuscript, comments of the editors, etc are available here: <https://www.sdiarticle5.com/review-history/91927>

Original Research Article

Received 15 July 2022
Accepted 23 September 2022
Published 30 September 2022

ABSTRACT

This study investigated the toxicity of Lidocaine Hydrochloride-sodium Bicarbonate (LHB) on *Oreochromis niloticus* juveniles (20.75 g). The histological tissue examinations were used to assess the effects of the anaesthetic agent (LHB) on the fish after exposure. Varying concentrations of LHB in increments of 10mg/L ranging from 60mg/L to 100mg/L were used for the static bioassay. There was a decrease in induction and recovery time with an increasing concentration of LHB showing a significant positive correlation ($R^2= 0.9721$; $p<0.05$) and ($R^2=0.7338$; $p<0.05$) respectively. Anaesthetic values of LHB for *O. niloticus* at an induction time of less than 4 minutes and recovery time of less than 3 minutes were observed. No mortality occurred during the experiment. Histological examination of the gills, liver and kidney of *O. niloticus* after exposure showed different pathological changes. The gills and liver of the fish exposed to 100 mg/L concentration showed no sign of histological changes. However, the results obtained showed a severe histological effect on the kidney of juveniles *Oreochromis niloticus* at 100 mg/L of LHB.

Keywords: Anaesthesia; toxicity; histology; exposure; lidocaine hydrochloride-sodium bicarbonates.

1. INTRODUCTION

Anesthetics are a type of sedative that helps to prevent stress and physical harm [1].

Researchers are highly concerned about the suffering fish endure due to the handling and aquaculture industry's rapid global expansion [2]. Therefore, from a scientific perspective, the use

*Corresponding author: Email: awopetutope@yahoo.com;

of anesthetics is very necessary and has developed into a practice in the aquaculture business; as a result, it may be impossible to imagine exposing fish to different stressors without anesthetics (Velek et al. 2009). Aquaculture fish are subject to a variety of stressors, including chemical, biological, physical, and procedural stressors [3]. Fish raised in intensive culture systems are subjected to a variety of acute and chronic stresses, which have a negative impact on their ability to develop, reproduce, and have immune systems that are competent [4-7]. These particular stressors for fish in aquaculture include chemical factors like poor water quality, biological factors like illnesses, physical factors like temperature changes, and procedural factors like selection or sorting. The procedural stressors that are created by routine management procedures in fish farming are the most common and cause stress in fish, necessitating the use of anaesthetic. The condition known as anaesthesia prevents the senses, including the ability to feel pain, entirely or partially [8]. Addition of an anesthetic chemical to water, which is comparable to inhalation anesthesia in terrestrial animals, is the most often employed anesthetic approach in aquaculture. The anaesthetic is absorbed into the bloodstream by breathing, causing numbing of the senses and promoting blood circulation. The gills, kidney, digestive tract, and skin are used for the excretion of the remaining metabolites. To determine the effectiveness of various anesthetics, fish of various sizes were utilized. Both common anesthetics like MS-222, Benzocaine, Eugenol, Clove oil, 2-phenoxyethanol (PE), Lidocaine hydrochloride, sodium bicarbonate (LHB) and others, as well as unconventional substances like the alcoholic and aqueous tobacco extracts and crude marijuana leaf extract [9-13]. A proven anesthetic agent in aquaculture due to its significant efficacy and accessibility is lidocaine hydrochloride. Lidocaine hydrochloride's toxicity profile is also easily accessible [14]. In freebase form, it is easily soluble in acetone or alcohol but insoluble in water. It is typically utilized in the form of a salt called hydrochloride, which is freely soluble in water [15]. Nevertheless, buffering agents are necessary for lidocaine hydrochloride to neutralize the pH and so increase efficacy (Ferreira et al. 1984) and avoid metabolic acidemia, a state brought on by anesthesia-induced hypoxemia and anaerobic metabolism [16]. Sodium bicarbonate (NaHCO_3), the buffering agent, is a white powder that quickly dissolves in water to release carbon dioxide gas.

It also goes by the name "baking soda." Sodium bicarbonate is widely accessible, affordable, non-toxic, and secure for use by people [17]. The purpose of the current study is to ascertain the anesthetic effects of lidocaine hydrochloride buffered with sodium bicarbonate on juvenile *O. niloticus* through its effectiveness in terms of induction and recovery time, behavioral changes during exposure, and histological effects at various concentrations.

2. MATERIALS AND METHODS

2.1 Collection of Experimental Fish

A total of one hundred and twenty (120) *O. niloticus* juveniles with mean weight of 20.75 g were obtained from the Teaching and Research Fish Farm, Department of Fisheries and Aquaculture Technology, Federal University of Technology Akure, Nigeria. They were kept in a plastic tank for 24 hours to acclimatize them to the laboratory condition prior to the experiment.

2.2 Lidocaine Hydrochloride

Commercial lidocaine hydrochloride solution (2% solution) was obtained from Matador Dafon Pharmaceutical Limited, Akure, Nigeria. Its active ingredients are 2- [diethylamino]-*N*-2,6-dimethylphenyl acetamide hydrochloride and its concentrations were expressed in mg/l.

2.3 Water Quality Parameters

The selected water quality parameters such as temperature, pH, dissolved oxygen and conductivity were analyzed using Multi-purpose thermometer (Model: YSI 550) and Searchtech Instruments, Model PHS-3C, Model YSI 550 DO, and Model DDS-307, for pH, DO and conductivity respectively using standard methods [18].

2.4 Experimental Procedure

A preliminary experiment was conducted to determine whether Lidocaine hydrochloride would be effective or not as anaesthesia for fish. One gram per litre (1g/l of Sodium bicarbonate (NaHCO_3)) was added to each treatment and stirred to dissolve completely before adding Lidocaine hydrochloride solution to each treatment at the concentration of 60 mg/l, 70 mg/l, 80 mg/l, 90 mg/l and 100 mg/l respectively. NaHCO_3 was added to increase the efficacy of the anesthetic agent and to serve as a buffering effect because of the acidic nature of the anesthetic agent. Ten (10) fish were randomly

selected and placed in each plastic tank with 10 L of water containing the anaesthetic agent to determine the induction time. The four stages of anaesthesia indicated in Table 1 were achieved based on the dose and the length of exposure [19]. The induction time of anaesthetization and recovery were recorded during the experiments. The concentration of Lidocaine hydrochloride buffered with NaHCO_3 at which *O. niloticus* juveniles reached sedation in the least induction time and with the highest recovery time and 100% survival was chosen as the maximum level of Lidocaine hydrochloride to be used. After anaesthesia, the fish were removed and placed in the recovery tanks (anaesthetic-free tanks) and recovery time was recorded. The fish were maintained for 48 hours to observe possible mortality. Behavioural responses of the test organisms were observed during the exposure to the anaesthetic agent.

2.5 Histological Examination of Tissues

The samples of gills, liver and kidney of *O. niloticus* juveniles exposed to Lidocaine Hydrochloride-Sodium bicarbonate were examined at the Histopathology laboratory, Department of Veterinary Anatomy, University of Ibadan, immediately after the experiment. The samples were preserved in 10% formaldehyde prior to the microscopic examination. The preserved organs were dehydrated in graded level of alcohol (50%, 70%, 90% and 100%) after which they were cleared in mixture of alcohol and xylene (each of same volume) for 3 hours; then 100% xylene for 3 hours. The specimen was then impregnated in molten and placed in the oven for 6 hours after which they were embedded in petri-dishes with wax. The specimens were then mounted on wooden blocks and sectioned with the aid of a microtome of 7 microns sections before staining in haematoxylin stain. The specimens were sectioned into thin sections with the aid of microtome prior to staining in haematoxylin eosin stain. The stained specimens were observed under a light microscope at different magnifications (x400) and the photographs of slides were taken.

Linear regression and graph was used to analyze the data collected in order to determine the relationship between the concentration of LHB and the induction and recovery time. Water

quality parameters data collected were analyzed using One Way Analysis of Variance (ANOVA) to test the significant differences using Duncan Multiple Range Test (DMRT). Pearson correlation was calculated using SPSS Version 20. All tests, except the histopathological analysis, were carried out at 5% level of probability.

3. RESULTS AND DISCUSSION

3.1 Behavioral Activities

When fish were exposed to LHB, swimming activity generally decreased. Some fish were stationary while others swam erratically in a circular pattern. The fish remained in an oblique position with partial loss of equilibrium. After a while, the fish fell flat on their sides with rapid opercula movements and finally were insensitive to external stimuli with no opercula movements. The fish recovery signs started with opercula movements which is slow, steady and the movements in the head and tail region to maintain normal lateral position.

3.2 Induction and Recovery Time

Table 2 shows induction and recovery time of the test fish for each dose of LHB. The induction time decreased with increasing concentrations of LHB (Table 2). The recovery time also decreased with increasing concentrations of LHB with 100% survival rate after 24 hours.

Figs. 1 and 2 shows the relationship between the concentration of Lidocaine hydrochloride-sodium bicarbonate and induction time and recovery time. Both have a positive linear effect with significant correlation of $R^2 = 0.9721$ and $R^2 = 0.7338$ ($P < 0.05$) respectively.

As the concentrations of Lidocaine hydrochloride increased, the pH and the conductivity increased, the dissolved oxygen (DO) decreased while there were fluctuations in the temperature as presented in Table 3. The conductivity of the test solution increased rapidly after the anaesthetic agent was administered. The increase in pH and conductivity were because of the addition of the buffering agent to the anaesthetics while the decrease in dissolved oxygen can be as a result of the by-product of NaHCO_3 given off as CO_2 which increases the pH leading to rapid opercula movement of the fish during anaesthesia.

Table 1. The four stages of anaesthesia and the behavioural response of juveniles of *O. niloticus* exposed to different concentrations of lidocaine hydrochloride-sodium bicarbonate

| Stage | Condition | Behaviour/Response |
|-------|----------------------|---|
| I | Sedation | Motion and breathing reduced |
| II | Anaesthesia | Partial loss of equilibrium Reactive to touch stimuli |
| III | Surgical anaesthesia | Total loss of equilibrium No reaction to touch stimuli |
| IV | Death | Breathing and heart beats stop Overdose-death |

After Shawn et al. [19]

Table 2. The relationship between the induction and recovery time of *O. niloticus* juveniles exposed to different concentration of lidocaine hydrochloride-sodium bicarbonate

| Concentrations (mg/L) | Induction time (min) | Recovery time (min) |
|-----------------------|----------------------|---------------------|
| Control | - | - |
| 60 | 35.34±2.84 | 4.86±1.95 |
| 70 | 31.08±2.76 | 3.85±0.83 |
| 80 | 24.18±1.58 | 4.19±2.65 |
| 90 | 11.70±5.15 | 3.93±2.50 |
| 100 | 3.74±0.76 | 2.69±2.25 |

Table 3. Water parameters of different concentrations of lidocaine hydrochloride-sodium bicarbonate used during the experiment

| Concentration (mg/L) | Temperature (°C) | pH | DO (mg/l) | Conductivity (uS/cm) |
|----------------------|-------------------------|------------------------|-------------------------|--------------------------|
| Control | 30.25±0.07 ^a | 6.49±0.01 ^a | 5.25±0.21 ^c | 21.25±0.07 ^a |
| 60 | 30.30±0.00 ^a | 7.62±0.01 ^b | 3.45±0.35 ^b | 120.80±2.12 ^b |
| 70 | 30.40±0.57 ^a | 7.51±0.02 ^b | 3.20±0.14 ^{ab} | 124.70±0.28 ^c |
| 80 | 30.40±0.28 ^a | 7.57±0.07 ^b | 3.05±0.07 ^{ab} | 128.50±2.26 ^d |
| 90 | 30.30±0.14 ^a | 7.58±0.13 ^b | 3.50±0.28 ^b | 130.20±0.14 ^d |
| 100 | 30.25±0.07 ^a | 7.64±0.01 ^b | 2.85±0.2 ^a | 130.75±0.07 ^d |

Different superscript in each column indicate significant differences ($P < 0.05$)

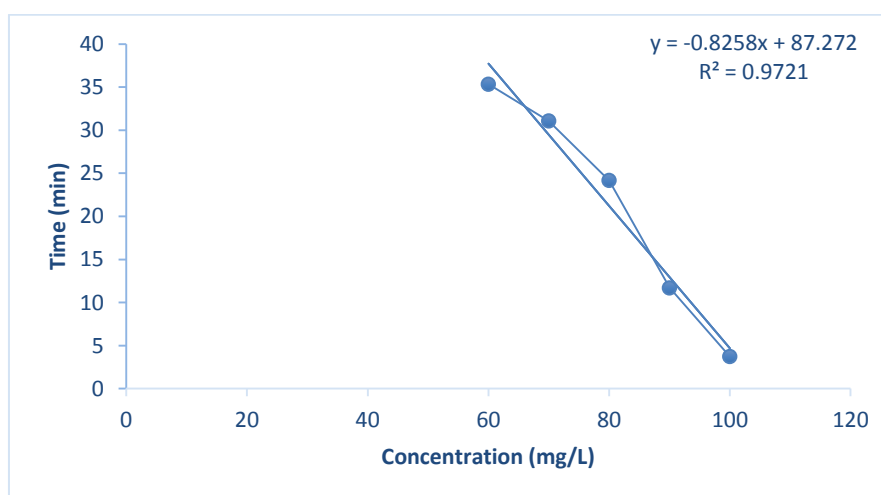


Fig. 1. Relationship between concentration and induction time of *O. niloticus* juveniles exposed to different concentration of lidocaine hydrochloride-sodium bicarbonate

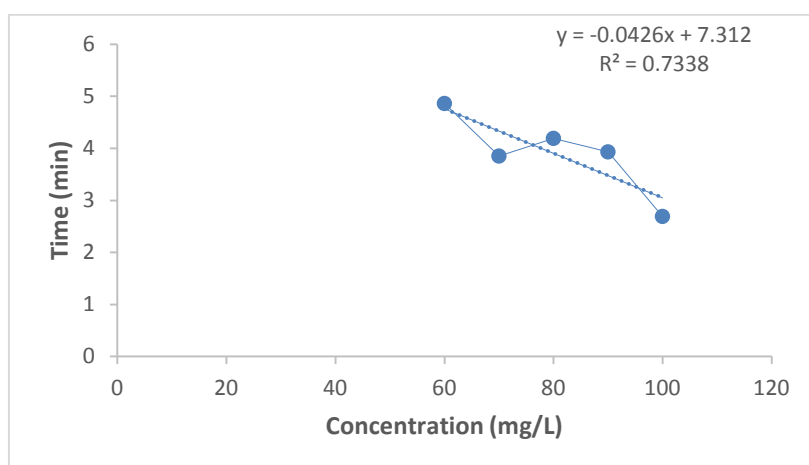


Fig. 2. Relationship between concentration and recovery time of *O. niloticus* juveniles exposed to different concentration of lidocaine hydrochloride-sodium bicarbonate

3.3 Histological Examination

Histological examination is shown in Plate 1 below. Experimental fish exposed to LHB showed no lesions in the gills of the control fish (A) and 100 mg/L concentration (E). Other concentrations (60, 70, 80 and 90 mg/L) of LHB showed severe, mild to moderate erosion of the gill mucous membrane (B-F). No lesions were observed in the kidney of the control and 90 mg/L concentration (G and K). There were moderate to severe congestion of the renal blood vessel of fish exposed to concentrations of 70 mg/L, 80 mg/L and 90 mg/L (H, I and J). Epithelial degeneration of the renal tubules was seen in 100 mg/L concentration (R). In the liver of experimental fish, no lesion was seen in the control (M). Concentrations of 80 mg/L and 100 mg/L (P and R) also show no lesion but concentration of 90 mg/L (Q) had prominent melanomacrophage centres. The liver of fish exposed to 60mg/L and 70mg/L showed moderate to severe haemorrhage in the liver parenchyma and portal and sinusoid congestion (N and O).

One technique for reducing fish stress and for making aquaculture processes easier is the use of anesthetics [20]. In the current work, *O. niloticus* induction and recovery times were calculated using LHB. Gilderhus [21] claims that when placed in a recovery tank, induction time often last less than 4 minutes and recovery time typically lasts between 10 and 15 minutes. According to this study, LHB dosages of 60, 70, 80, and 90 mg/L can be utilized for moderately rapid anesthesia (20 min and 40 min), while doses of 100 mg/L can induce anesthesia in fish

in less than 4 minutes. Chereen et al. [22], on the other hand, reported that 325 mg/L concentration of LHB produced Zebrafish (*Danio rerio*) in 365s (6.08 min). This is in agreement with Abbas et al. [10] who used the same LHB concentration and Park et al. [14] who used 1000 mg/L Lidocaine hydrochloride buffered with 1 g/L sodium bicarbonate to sedate soft-shelled turtles (*Pelodiscus sinensis*). Agokei and Adebisi [12] exposed *O. niloticus* to alcoholic extract and aqueous preparation of tobacco and reported effective dosages of 6-7ml/L (alcoholic extract of tobacco) and 4-4.5g/L (aqueous preparation of tobacco), with an induction time of 2.40.54 and 3.20.14 minutes, respectively. This finding is consistent with the hypothesis that the *O. niloticus* induction time reduces with increasing LHB concentration. When compared to the induction time (3.740.74minutes) of 100 mg/L of LHB employed in this investigation, the induction times of the alcoholic extract of tobacco and the aqueous preparation of tobacco were faster. According to Agokei and Adebisi [12], alcoholic extract and aqueous tobacco preparation had no impact on the pH (6-7) and temperature (281.0°C) of the water, however lidocaine hydrochloride increased the pH, temperature, and conductivity of the water (as shown in Table 2). The use of sodium bicarbonate increases water's pH and is useful for anesthesia, according to Altun et al. [23]. The healing time shortens when LHB concentration rises. When exposed to lidocaine hydrochloride, *O. niloticus* fingerlings recovered more slowly, according to Abbas et al. [10]. This is as a result of the inability of the fish to rapidly eliminate the chemical from its body. The buffering effect of NaHCO₃ makes Lidocaine hydrochloride effective

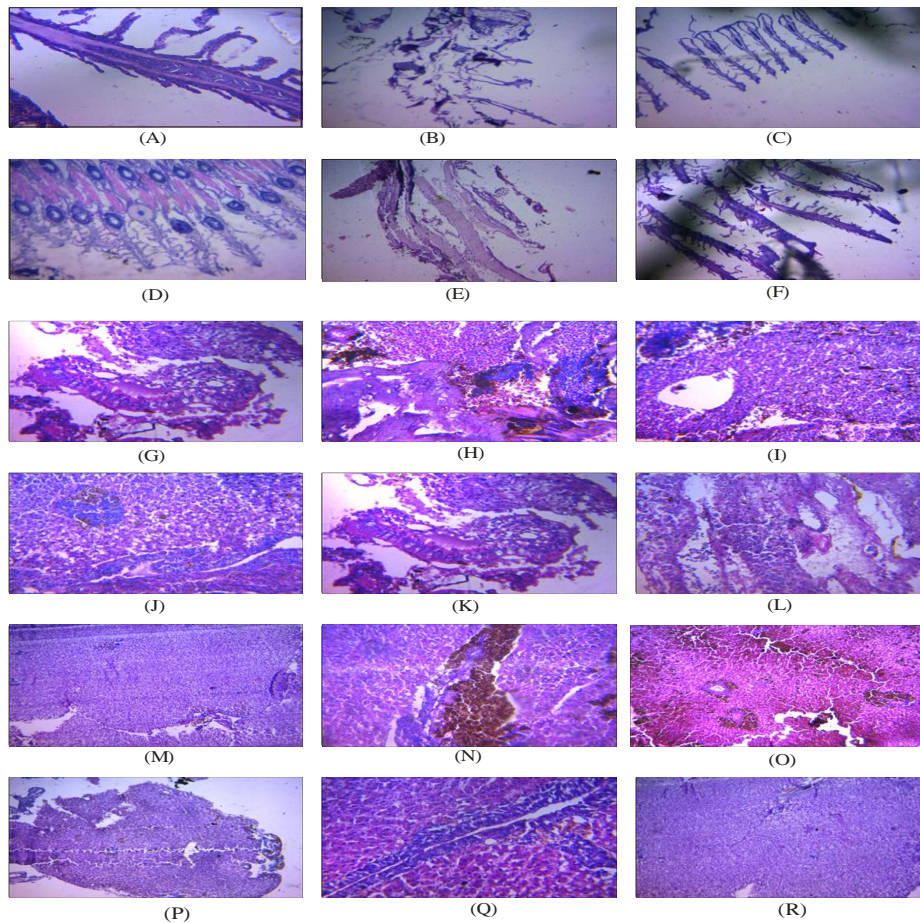


Plate 1. (A) Control shows no signs of lesions on the gill of *O. niloticus* (Mg. x400). (B) Gills of *O. niloticus* exposed to 60 mg/L of Lidocaine hydrochloride-sodium bicarbonate shows severe erosion of mucous membrane. (Mg x400) (C) Gills of *O. niloticus* exposed to 70 mg/L of Lidocaine HCL-sodium bicarbonate shows mild to moderate erosion of gill mucous membrane (Mg x 400). (D) Gills of *O. niloticus* exposed to 80 mg/L of Lidocaine HCL-sodium bicarbonate shows mild to moderate erosion of gill mucous membrane though the primary lamellae is normal (Mg x 400). (E) Gills of *O. niloticus* exposed to 90 mg/L of Lidocaine HCL- NaCO₃ shows mild erosion of gill mucous membrane (Mg x400). (F) Gills of *O. niloticus* exposed to 100 mg/L of Lidocaine HCL-NaCO₃ shows no signs of any lesions (Mg x400). (G) Kidney of *O. niloticus* in the control shows no signs (Mg x400). (H) Kidney of *O. niloticus* exposed to 60mg/L of HCL-NaCO₃ shows severe congestion of the renal blood vessels and some areas are haemorrhagic (Mg x400). (I) Kidney of *O. niloticus* exposed to 70mg/L of Lidocaine HCL- NaCO₃ shows severe congestion of the renal blood vessels (Mg x400). (J) Kidney of *O. niloticus* exposed to 80mg/L of Lidocaine HCL-NaCO₃ shows moderate congestion of the renal blood vessels (Mg x400). (K) Kidney of *O. niloticus* exposed to 90mg/L of Lidocaine hydrochloride-sodium bicarbonate shows no signs of any lesions (Mg x400). (L) Kidney of *O. niloticus* exposed to 100mg/L of Lidocaine hydrochloride-sodium bicarbonate shows severe epithelial degeneration of the renal tubules (Mg x400). (M) Liver of *O. niloticus* in the control shows no sign of lesions (Mg x400). (N) Liver of *O. niloticus* exposed to 60mg/L of Lidocaine HCL-NaCO₃ shows moderate to severe hemorrhage in the liver parenchyma (Mg x400). (O) Liver of *O. niloticus* exposed to 70mg/L of Lidocaine HCL NaCO₃ shows severe portal and sinusoidal congestions (Mg x400). (P). Liver of *O. niloticus* exposed to 80mg/L of Lidocaine HCL-NaCO₃ shows no signs of any lesions (Mgx400). (Q) Liver of *O. niloticus* exposed to 90mg/L of Lidocaine HCL-NaCO₃ shows no signs of lesions but the liver had prominent elanomacrophage centres (Mg x400). (R) Liver of *O. niloticus* exposed to 100mg/L of Lidocaine HCL-NaCO₃ shows no signs of lesions (Mg x400)

for rapid anaesthesia. This is consistent with Chereen et al. [22] experiment using Zebrafish to test the effectiveness of lidocaine hydrochloride buffered with sodium bicarbonate (*Danio rerio*). The recovery time of lidocaine hydrochloride slowed with a concentration increase from 325 mg/L to 350 mg/L, although there was mortality due to the stated limited margin of safety. In fish bodies, diffusion of sodium bicarbonate at low concentration caused a rapid recovery, according to Opiyo et al. [11]. This is explained by the fact that anesthesia is unaffected significantly by CO₂ produced at low concentrations. However, the effectiveness of a particular anesthetic depends on the species of fish. Medaka fish can be rendered unconscious by giving them up to 800 mg/L of lidocaine hydrochloride, according to Chereen et al. [22]. (*Oryzias dancena*). Histopathological alterations have been used as indicators of different chemical effects on different fish tissues, which reflect the health of the fish in the body of water [24]. The extent of damage caused by any chemical or pollutant has been found to be dependent on the concentration and exposure duration of such chemical [25]; which was noted by Nasiruddin et al. [26] that histopathological variations in different organs depend on the toxicity of the chemicals to which they are exposed to. The histopathological effect in *O. niloticus* juveniles exposed to varying concentrations of LHB showed varying degree gill erosion which ranges from severe, moderate to mild erosion of the gill mucous membrane. The severity increases with increasing time of exposure. The changes observed in the kidney exposed to lidocaine hydrochloride- sodium bicarbonate showed an inconsistent histopathological effect with increasing concentration. There was severe epithelial degeneration of the renal tubules in fish exposed to the highest concentration (100 mg/L). This agreed with El-Sherif and El-Feky [27] who examined the kidney of Nile tilapia fingerlings after 75 days of exposure to un-ionized ammonia (NH₃-N) which showed an increase in the thrombus formation and infiltration of melanomacrophage cells between the renal tubules. Additionally, there was significant glomerulosclerosis, hyaline droplet degeneration and swelling of the renal tubules, necrosis of the renal tubules, rupture of the melanomacrophage center, and disseminated melanomacrophage cells in the renal parenchyma [28]. The alterations in the liver agreed with the results obtained by Saber et al. [29] and El-Sherif and El-Feky [27]. Wajsbrot et al. [30] also reported that the histopathological effects of chronic

toxicity of ammonia on the gills and liver function induce tissue hypoxia which may lead to reduction in fish growth.

4. CONCLUSION

A cheap, non-toxic, commonly used chemical that is user-friendly, environmentally acceptable, and also easily accessible is lidocaine hydrochloride and sodium bicarbonate. They have each been employed separately to put various fish species, including reptiles, under anesthesia. Lidocaine hydrochloride's effectiveness has been demonstrated to be enhanced by the buffering effect of sodium bicarbonate (1g/L), which indicates rapid anesthetic agent elimination without adverse effects on organs as well as a decrease in the quantity or amount used for anesthesia when used separately.

COMPETING INTERESTS

Authors have declared that no competing interests exist.

REFERENCES

1. Ross LG, Ross B. Anaesthetic and sedative techniques for aquatic animals. John Wiley & Sons; 2009.
2. Ashley PJ. Fish welfare: Current issues in aquaculture. Applied Animal Behaviour Science. 2007;104(3-4):199-235.
3. Obirikorang KA, Ansong M, Gyampoh BA, Attu GAT. First report of aquaculture-mediated introduction of the Nile tilapia, *Oreochromis niloticus* (Linnaeus,1758) into lake Bosomtwe, Ghana. BioInvasions Record. 2020;9(4).
4. Barton BA, Shreck CB, Barton LD. Effects of chronic cortisol administration and daily acute stress on growth, physiological conditions and stress responses in juvenile rainbow trout. Disease Aquatic Organisms. 1987;2:173-185.
5. Maule AG, Tripp RA, Kaatarist AY, Shreck CB. Stress alters immune functions and disease resistance in chinook salma (*Oncorhynchus tshawytscha*). Journal of Endocrinology. 1989;120:135-142.
6. Shreck CB, Wilfreds C, Fitzpatrick MS. Effect of stress on fish reproduction, gamete quality and progeny. Aquaculture. 2001;197:3-24.
7. Iwama GK, Afonso LOB, Vijayan MM. Stress in fishes in: Evans DH, Claiborne

- JB (Eds) The physiology of fishes. CRC Press Taylor and Francis, Boca Raton. Florida. 2006;601.
8. Neiffer DL, Stamper MA. Fish sedation, anesthesia, analgesia and euthanasia: Considerations, methods and types of drugs. ILAR journal. 2009;50(4):343-360.
 9. Small BC. Anesthetic efficacy of metomidate and comparison of plasma cortisol responses to tricaine methanesulfonate, quinaldine and clove oil anesthetized channel catfish (*Ictalurus punctatus*). Aquaculture. 2003;218; 177-185.
 10. Abbas HHH, Abdel-Gawad AS, Akkr AA. Toxicity and efficacy of lidocaine as an anaesthetics for nile tilapia (*Oreochromis niloticus*). Parkistan Journal of Biological Sciences. 2006;9(12):2236-2242.
 11. Opiyo MA, Ogello EO, Charo-Karisa H. Effectiveness of sodium bicarbonate as an anaesthetic for different sizes of nile tilapia (*Oreochromis niloticus* L.,1758) Juveniles. Int. J. of Aquatic Science. 2013; 4(2):14-22.
 12. Agokei OE, Adebisi AA. Tobacco as an anesthetic for fish handling procedures. Journal of Medicinal Plants Research. 2010;4(14):1396-1399.
 13. Audu BS, Adamu KM, Ufodike EB. Behavioural response and opercular ventilation rate of nile tilapia (*Oreochromis niloticus*) fingerlings after anesthesia with crude leaf extract of marijuana (*Cannabis sativa*). Applied Science Research Journal. 2013;1(2):66-77.
 14. Park IS, Cho SH, Hur JW, Choi GC, Oh SY, Kim DS, Lee JS. Lidocaine hydrochloride-sodium bicarbonate as an anesthetic for soft-shelled turtle *Pelodiscus sinensis*. Fisheries Science. 2006;72(1): 115-118.
 15. Merck and Company. The Merck Index, 11th Ed. Rahway, New Jersey: Merck and Company. 1989;1606.
 16. Donald L Neiffer, Andrew Stamper M. Fish sedation, anesthesia, analgesia and euthanasia: Considerations, methods and types of drugs. ILAR Journal. 2009;50(4): 343-360.
 17. Pawar HB, Ingole BS, Sreepada RA. Efficacy of sodium bicarbonate as anaesthetic for yellow seahorse, *Hippocampus kuda* (Bleeker, 1852). International Journal of Research in Fisheries and Aquaculture. 2013;3(3): 103-107.
 18. APHA, AWWA, WPCF. (American Public Health Association and Water Pollution Control Federation). Standard methods for the examination of water and waste water.17th Edition. APHA, Washington D.C, USA. 1989;1391.
 19. Shawn D Coyle, Robert M Durborow, James H Tidwell. Anesthetics in aquaculture: Southern regional aquaculture centre. SRAC Publication. 2004;3900.
 20. Husen A, Sharma S. Efficacy of anesthetics for reducing stress in fish during aquaculture practices-a review. Journal of Science, Engineering and Technology. 2014;10(1):104-123.
 21. Gilderhus PA. Efficacy of benzocaine as an anesthetic for salmonid fishes. North American Journal of Fisheries Management. 1989;9:150-153.
 22. Chereen Collymore, Angela Tolwani, Christine Lieggi, Skye Rasmussen. Efficacy and safety of 5 anesthetics in adult zebrafish (*Danio rerio*). Journal of the American Association for Laboratory Animal Science. 2014;53(2):198-203.
 23. Altun T, Bilgin R, Danabaş D. Effects of sodium bicarbonate on anaesthesia of common carp (*Cyprinus carpio* L., 1758) juveniles. Turkish journal of fisheries and aquatic sciences. 2009;9(1).
 24. Pandey Devenda N, Pandey Neha, Shukla Sandeep K. Histopathological changes in the gill tissue of the fish, *Labio rohita* exposed to untreated and treated amlai paper mill effluent. Indian Streams Research Journal. 2014;4(6):1-4.
 25. Venkatesh Chaturvedi, Ashok Kumar. Toxicity of Sodium dodecyl sulphate in fishes and animals. A Review International Journal of Applied Biology and Pharmaceutical Technology. 2010;1(2): 630-634.
 26. Nasiruddin Munira, Mohammad Al, Azadi, Akllima Jahan. Histopathological changes in the gill, liver and intestine of *Heteropneustes fossilis* (Bloch) treated with three dry seed extracts. Journal of. Asiat. Soc. Bangladesh Sci. 2012;38(2): 217-226.
 27. El-sherif MS, El-feky, Amal M. Effect of ammonia on nile tilapia (*O. niloticus*) performance and some hematological and histological measures. 8th International Symposium on Tilapia in Aquaculture; 2008.

28. Carter KM, Woodley CM, Brown RS. A review of tricaine methanesulfonate for anesthesia of fish. *Reviews in fish biology and fisheries*. 2011;21(1):51-59.
29. Saber A El-Shafai, El-Gohary Fatma A, Fayza AN, Peter Van Der Steen N, Huub JG. Chronic ammonia toxicity to duckweed-fed tilapia (*O. niloticus*). *Aquaculture*. 2004;232:117-127.
30. Wajsbrodt N, Gasith A, Diamant A, Popper DM. Chronic toxicity of ammonia to juvenile gilthead sea bream *Sparus aurata* and related histopathological effects. *Journal Fish Biology*. 1993;43,321–328.

© 2022 Modede and Awopetu; This is an Open Access article distributed under the terms of the Creative Commons Attribution License (<http://creativecommons.org/licenses/by/4.0>), which permits unrestricted use, distribution, and reproduction in any medium, provided the original work is properly cited.

Peer-review history:

The peer review history for this paper can be accessed here:
<https://www.sdiarticle5.com/review-history/91927>