



Determining the Effectiveness of Different Reconstruction Method and Mandibular Implants for Fracture in the Mandible

Maryam Hassannia¹ and Sajad Ghorbanizadeh^{2*}

¹School of Dentistry, Lorestan University of Medical Science, Khorramabad, Iran.

²Department of Oral and Maxillofacial Radiology, School of Dentistry, Lorestan University of Medical Science, Khorramabad, Iran.

Authors' contributions

This work was carried out in collaboration between both authors. Both authors read and approved the final manuscript.

Article Information

DOI: 10.9734/JPRI/2021/v33i42B32443

Editor(s):

(1) Dr. S. Prabhu, Sri Venkateswara College of Engineering, India.

Reviewers:

(1) Moin Iftikhar Shapoo, Madhya Pradesh Medical Science University, India.

(2) Daya Shankar, India.

Complete Peer review History: <https://www.sdiarticle4.com/review-history/73051>

Received 17 June 2021

Accepted 24 August 2021

Published 02 September 2021

Review Article

ABSTRACT

Introduction: Every year, many people suffer from mandibular defects due to various reasons such as trauma or malignant tumors. Various techniques for reconstructing mandibular defects have always been considered by surgeons and maxillofacial specialists to select the best option and achieve the desired results for the patient. In this study, various articles and their techniques for reconstruction of mandibular defects were reviewed and their results were reported.

Materials and Methods: The present study is a systematic review study in which the keywords implants, mandibular, trauma, reconstruction of the desired articles in two databases pubmed and science direct from January 1, 2010 to August 31, 2018 And were selected and then examined.

Results: 33 articles met the inclusion criteria on which the final review was performed. 17 articles were clinical studies, 9 articles were case reports and 7 articles were reviews. In these 33 studies, various techniques were examined, including the use of free vascularized fibular flap, the use of computer software, and the prototyping technique.

Conclusion: Among the existing methods, the use of free vascularized fibular flap has been approved as a widely used and reliable method in various studies, and many researchers believe that this technique is the gold standard for the reconstruction of mandibular defects. The use of computer software was also used as a complementary technique to improve surgical outcomes.

Keywords: Reconstruction; implants; mandibular; trauma.

1. INTRODUCTION

Defects and injuries occurs in the maxilla and mandible for various reasons, including trauma, the presence of tumors, osteomyelitis, congenital defects such as hemifacial, microsomia and Pierre Robin sequence [1]. The mandible plays an important role in human life; Protecting the teeth, aiding the mastication process, swallowing, pronunciation and respiration are among the mandibular maps [2]. The mandible is a unique bone in the human body and is very important for several reasons [3]. This bone supports the airway and supports the base of the tongue. Mastication, swallowing and Speaking are done with the help of this bone. Mandible must also withstand a lot of force during the chewing operation [3]. Findings show that this bone receives an average of 4346 Newtons of molar occlusal force [3]. The jawbones are very important in a person's appearance and Esthetic , and many writers and researchers refer to this role of the jaw as "Andy Gump", which refers to a cartoon about smoking in which a person does not have a mandible [3]. In the reconstruction of the jaw, attention should be paid to the individual plans of this organ, and for this reason, the reconstruction of this bone has become very challenging. This bone is also located near the skull bone and its reconstruction complications can have irreversible consequences [3]. Thousands of people need surgery and mandibular reconstruction every year [4-7]. The first successful mandibular reconstruction was performed in 1976 by Panje et al. [3]. The researchers used groin tissue to reconstruct the mandible. The first hard part used to reconstruct the jaw was made of Vitallium, an alloy of cobalt, chromium and molibidium. This alloy was quickly replaced by stronger and more neutral alloys (5g). Currently, mostly titanium implants are used [2]. Now, maxillofacial reconstructive surgeries involve a wide range of interventions that sometimes lead to soft tissue augmentation and hard tissue restructuring. Reconstruction of oral and maxillofacial defects is recognized as a major challenge for maxillofacial surgeons [1, 8-10]. Defects in this area are more common in patients with squamous cell carcinomas [11]. The development of antibiotics in the control of infections, new imaging techniques as well as anesthesia in recent decades has led to major changes in maxillofacial reconstruction [1, 8, 9]. In this study, different methods of jaw bone regeneration have been studied.

2. MATERIALS AND METHODS

2.1 Search and Selection Strategy of Studies

In the present study, in order to find the desired studies in two databases, pubmed and science direct, a search was performed from January 1, 2010 to August 31, 2018 according to the following strategies:

- 1- Pubmed: ((implants [Title / Abstract]) AND mandibular [Title / Abstract]) AND trauma [Title / Abstract] 2010/01/01 to 2018/08/31.
- 2- Pubmed: (reconstruction [Title / Abstract]) AND mandibula [Title / Abstract] 2010/01/01 to 2018/08/31.
- 3- Pubmed: ((reconstruction [Title / Abstract]) AND mandibular [Title / Abstract]) AND trauma [Title / Abstract] 2010/01/01 to 2018/08/31.
- 4- Science direct: reconstruction [Title / Abstract]) AND mandibular [Title / Abstract]) AND trauma [Title / Abstract]
- 5 - Science direct: ((implants [Title / Abstract]) AND mandibular [Title / Abstract]) AND trauma [Title / Abstract]

Two independent judges matched the found articles with the following criteria and identified the selected articles:

- 1- Articles should include case report, review, clinical trial.
- 2- Published in English.
- 3- Base on human sample.
- 4- The advantages and disadvantages of the method have been used.

2.2 Collecting Data

Two independent judges extracted the information, which included the method used, the advantages and disadvantages of the method and the final result, and published it in tabular form.

2.3 Data Analysis

In the present study, the data of selected studies were divided into three groups: Clinical studies, Case report and review. In each group of the year of publication of the article, the type of intervention (method used to repair the damage), the advantages and disadvantages of the

method and the final result of the study were extracted and categorized, and since most studies cannot be quantitatively analyzed, The results were reported qualitatively.

2.4 Findings

In this study, in the initial search, 202 articles (128 studies in the PubMed database and 74 studies in the Science Direct database) were obtained. In the initial review, 157 studies (119 studies from the PubMed database and 37 studies from the ScienceDirect database) were selected. Were reviewed. Out of 157 studies, 33 articles met the inclusion criteria on which the final study was performed. 17 articles were clinical studies, 9 articles were case reports and 7 articles were reviews.

2.4 Clinical Studies

Pototschnig et al. [12] used free osteofasciocutaneous fibula flap to repair mandibular injury. They studied 104 patients treated with this method and found that using free osteofasciocutaneous fibula flap was the best way to regenerate various mandibular

lesions. They believed that using this method included benefits; Optimal blood circulation in the repaired part is smooth, uniform and flexible surface of the skin.

Muñoz et al. [13] examined the results of using a zygomatic mandibular implant. They examined 15 patients (9 males and 6 females) with a mean age of 40.2 years (12-68 years) who were treated using this implant. The researchers found that using this implant was a good treatment for mandibular lesions and stressed that it should be used as soon as possible after the lesion to achieve better prognosis.

Ayali and Bilginaylar [14] investigated the biomechanical effects of implant diameter. In this study, they examined three groups. In the first group, edentulous people with mandibular bone with atrophy, in the second group, 3.5 × 11.5 mm implant and in the third group, 11.5 × 4.5 implant were used. In the first and second groups, the highest amount of stress was observed in the condylar neck area and in the third group, the highest level of stress was observed in the symphyseal area.

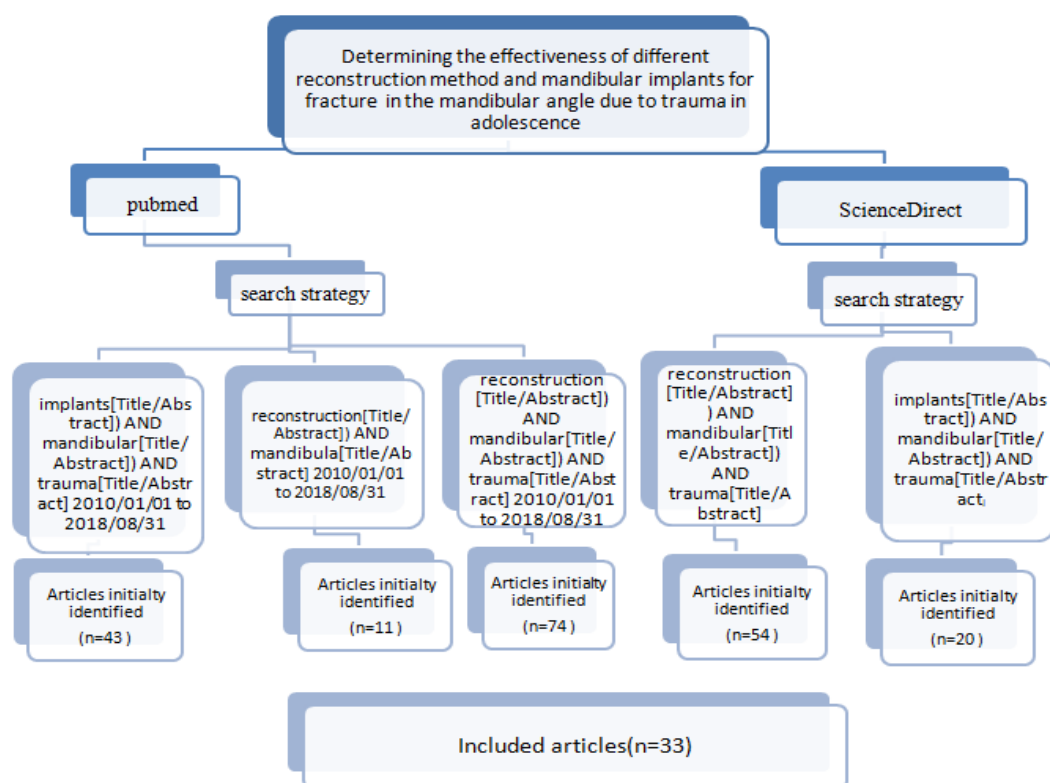


Fig. 1. Effectiveness of different reconstruction method and mandibular implants for fracture in the mandibular angle due to trauma in adolescence

Zou et al. [15] examined the results of using an implant-supported telescopic crown (TC). From January 2004 to December 2008, they selected individuals who had used this method to reconstruct mandibular lesions and evaluated clinical data including implant success and survival rate, physical and biological complications, and patient satisfaction. After reviewing 24 patients, they found that the use of TC could be a suitable method for people with insufficient bone volume.

Pingarrón-Martín et al. [16] studied the experience of mandibular reconstruction with transport-disc-distraction osteogenesis (TDDO). They concluded that TDDO is a viable alternative to conventional and invasive methods for reconstructing mandibular lesions, and stressed that patient education as well as the use of transport-disc-distraction device can be effective in achieving more desirable results.

Fang et al. [17] examined the long-term results of using Fibula Free Flap and Implant-Borne Dental in mandibular reconstruction. The researchers evaluated patients who used Fibula Free Flap and for mandibular reconstruction between 1988 and 2010 for clinical and radiographic data. The results of this study showed that the use of Fibula Free Flap and Implant-Borne Dental is a reliable method for the reconstruction of mandibular defects and oral function and its side effects are relatively low. The researchers further added that regular follow-up and oral hygiene can help in successful treatment.

Sabhlok et al. [18] investigated the use of coronoid process in the reconstruction of mandibular lesions and defect. The researchers selected and studied 12 patients who had used the technique to reconstruct the mandible. The results of this study showed that the use of coronoid process can provide a source for spontaneous reconstruction of bone defects.

Herford et al. [19] investigated the use of combination with rhBMP-2 sandwich technique in. The results of this study showed that adding rhBMP-2 to the sandwich osteotomy technique could have better results in the ossification process.

Amrani et al. [20] evaluated 12 patients who were treated for oral-maxillofacial defects by ramus / coronoid process grafts. The results showed that this method was successful when the ad integrum was reconstructed and there

were no defective implants in place. In general, it was found that the use of both the coronoid process of the mandible and the mandibular ramus can be used as a suitable source for ossification.

Gray et al. [21] examined the application of new auxiliary methods made possible by the use of computer software. Virtual Surgical Planning (VSP) and computer-aided design / computer-aided manufacturing (CAD / CAM) are some of the methods that Gray et al. Evaluated. In a retrospective study between 2012 and 2016, they selected 13 patients who had been screened with VSP and CAD / CAM before surgery. These methods helped the surgeon locate the incision points as well as prepare models. The results of this study showed that the use of VSP and CAD / CAM before surgery makes the results of the operation more accurate and, of course, safer, and in complex cases such as pediatric surgery helps to reduce the duration of surgery.

Tian et al. [22] examined the effect of a complete digital evaluation to visualize iliac bone graft surgery at the location of the implant in the mandibular bone. In fact, the researchers designed a virtual surgery with different types of digital instruments and compared the results with real surgery results. The results of the study showed that the use of digital surgery increases the predictive power of the treatment team from surgery so they can choose a more consistent and accurate method for surgery. The researchers believed that designing a digital process to visualize surgery could lead to more successful surgery and could be used as a treatment protocol to repair oral-maxillofacial defects.

Xu et al. [23] compared the results of different therapies for the treatment of maxillary ankylosis. They selected 18 patients with maxillofacial aneurysms between 2008 and 2013 and divided them into groups of 10 and 8 patients. In the first group, autogenous coronoid process graft (ACPG) and in the second group, lateral arthroplasty (LAP) were used for treatment. The results showed that compared to ACPG, LAP significantly improved facial pattern and inter-incisal opening (MIO). The researchers believed that LAP was an effective and practical treatment for maxillary oncology.

Yagihara et al. [24] used a poly (L-lactide) mesh combined with autogenous particulate cancellous bone and marrow to regenerate mandibular

lesions. In this study, 62 patients were studied in 8 hospitals. The results of the study showed that this method is an effective and stable method due to its favorable morphology, proper functional restoration and low side effects.

Xie and Sun [25] reviewed the results of using a non-vascularized iliac bone graft to reconstruct mandibular defects. They evaluated treatment outcomes and subsequent complications in 34 patients treated with this method. In the end, they concluded that this method is one of the most important methods of treating mandibular defects.

Nthumba [26] was one of the researchers who examined the results of using osteomuscular dorsal scapular flap in the reconstruction of jaw defects. He examined 8 patients with various mandibular defects treated with this method and concluded that this method could be a good choice for mandibular reconstruction, especially in cases where vascular injuries prevent Tissue transfer is free and also in cases where the source of free tissue supply is limited. This method can also be used as a secondary option in cases where free tissue transfer does not have the desired result.

Rana et al. [27] believed that the simplicity of the procedure, maintaining the beauty and healthy function of the face with the least complications in the tissue donor area are the minimum requirements for a good reconstruction. The researchers conducted a study to evaluate the results of bone grafts from different areas. They selected 178 patients with mandibular defects and evaluated their postoperative outcomes. The results of this study showed that autogenous bone grafts are a suitable method for mandibular reconstruction and free vascularized fibular flap should be considered as the first choice in reconstruction of maxillary defects.

Matsuo et al. [28] investigated the use of particulate cancellous bone and marrow (PCBM), platelet-rich plasma (PRP). In a retrospective study, the researchers enrolled 18 patients who had their jaws reconstructed using PCBM and PRP, and analyzed their clinical data. Other cases, there was no significant difference between the two methods. They believed that both methods were safe and reliable and could be used in cases of mandibular defects due to benign tumors and trauma.

The results of 17 clinical studies in the field of reconstruction of mandibular defects show that

different methods have been studied and most of them have been introduced as reliable and safe methods. What is remarkable is that the use of free vascularized fibular flap as a desirable and common method has been confirmed by most studies. The coronoid process is also known as a method that has good results in combination with other methods. Studies in recent years have shown a tendency to use computer technology and software to help surgeons design 3D images, perform virtual surgeries, and predict outcome and visualize clinical conditions. It becomes. The results of these studies also show that computer technology and software can help the process of reconstruction of jaw defects and facilitate the working conditions for the surgeon. These results can be seen in Table 1.

2.4.1 Case report studies

D'Amato et al. [29] reconstructed mandibular defects using the bone slat technique. They examined the clinical manifestations, quantity and quality of reconstructed bone, as well as the condition of blood vessels. In this study, a 52-year-old patient with a bone defect in the mandible was selected. The results showed that bone strengthening using this technique created the ideal volume of hard bone and soft tissue and provided suitable conditions for implant placement.

Bäumer et al. [30] studied the results of replacing anterior teeth in the mandible with implant-supported crowns. The results showed that the interdental soft tissue was significantly regenerated.

Deshraj and Ghanshyam [31] used flapless implant placement to reconstruct mandibular defects. The results showed that the use of this technique reduced trauma, reduced recovery time, less pain, reduced infection rate, and also improved patient satisfaction and inflammation due to the presence of sufficient arteries. These researchers consider the quality and quantity of hard and soft tissue as the limitation of this surgical method.

Cho-Lee et al. [32] used free vascularized fibular flap to reconstruct mandibular defects in a patient. After examining the clinical evidence and measuring bone indices, the researchers found that the vertical height of the bone remained stable without any complications, and stated that this method is an reliable method for maxillofacial surgery for implant placement.

Table 1. Clinical studies about mandibular reconstruction methods

| Row | Reconstruction method | Advantages of the method | Disadvantages of the method | Final result | Study (References) |
|-----|--|--|-----------------------------|--|--------------------|
| 1 | Free osteofasciocutaneous fibula flap | The wide cortical bone and the relative constant anatomy, the long pedicle, flat, uniform and sufficient large and pliable skin island, as well as the good blood circulation also by massive modelling of the skin and bone part. | Not reported | The utilisation of the free osteofasciocutaneous fibula flap is the best possible therapy for these difficult composite reconstructions. | [12] |
| 2 | zygomatic mandibular implant | The zygomatic implant is an excellent immediate loading option for mandibular dental rehabilitation among patients with mandibular defects. | Not reported | immediate occlusal loading of transmandibular zygomatic implants has a very good potential for success | [13] |
| 3 | three 3D FEA models were simulated; Model 1 (M1) is edentulous atrophic mandible, Model 2 (M2), 3.5x11.5 mm implants were inserted into lateral incisors area of same edentulous atrophic mandible, Model 3 (M3), 4.3x11.5 mm implants were inserted into lateral incisors area of same edentulous atrophic mandible | In M1 and M2 highest stress levels were observed in condylar neck, whereas highest stress values in M3 were calculated in symphyseal are | Not reported | To reduce the risk of bone fracture and to preserve biomechanical behavior of the atrophic mandible from frontal traumatic loads, implants should be inserted monocortically into spongy bone of lateral incisors area | [14] |
| 4 | dental implant-supported telescopic crown (TC) | More than 90% of patients were satisfied with the restoration of their oral function using TCs, The implant success rate was 100% after 5 years, and the prosthodontic maintenance and complication rate was 0.22 times per year, no statistically significant difference in the MBL between maxillary | Not reported | this treatment may be a viable option for patients with insufficient jawbone volume | [15] |

| Row | Reconstruction method | Advantages of the method | Disadvantages of the method | Final result | Study (References) |
|-----|--|--|-----------------------------|--|--------------------|
| 5 | transport-disc-distraction osteogenesis (TDDO) | and mandibular implants It shows the potential to restore a better anatomical bone regeneration, also providing soft tissues and reducing donor-site morbidity | Not reported | TDDO is an alternative to conventional and more invasive procedures, when we face severe segmental mandibular defects reconstruction | [16] |
| 6 | Fibula free flap procedures and implant-borne prostheses | fibula free flap and peri-implant complication rates proved to be low | Not reported | Fibula free flap procedures and implant-borne prostheses proved to be reliable approaches for rehabilitation of mandibular defects and oral function | [17] |
| 7 | autogenous coronoid process bone grafts | use of coronoid process of the mandible as a source for autogenous bone graft as it can provide sufficient bone in quantity and quality for selected maxillofacial reconstructions | Not reported | use of coronoid process of the mandible as a source for autogenous bone graft as it can provide sufficient bone in quantity and quality for selected maxillofacial reconstructions | [18] |
| 8 | incorporating recombinant human bone morphogenetic protein-2 (rhBMP-2) to the established sandwich osteotomy technique | All patients exhibited a significant increase in bone height. The amount distracted was 6.75 mm (range, 5-11 mm). The amount of relapse was 8.5% (range, 0%-18%). Dental implants were placed in the reconstructed ridges in all patients. There were no instances of permanent paresthesia. Two patients had exposure of a portion of the hardware, which healed uneventfully. The sandwich osteotomy technique has proven to be an effective method for augmenting deficient alveolar ridges. The addition of rhBMP-2 may aid in | Not reported | success rate by promoting osteogenesis at the osteotomy site, especially in multiple-operated patients where other traditional techniques have failed to gain the desired ridge height | [19] |

| Row | Reconstruction method | Advantages of the method | Disadvantages of the method | Final result | Study (References) |
|-----|--|---|-----------------------------|--|--------------------|
| 9 | autogenous extended mandibular ramus and coronoid process bone grafts | its The procedure was considered a success when the patient's deformities were reconstructed ad integrum and when there were no failures of the dental implants placed in the augmented areas as of the longest follow-up. All patients were successfully reconstructed. There was 1 infection at a donor site that resolved with local care and oral antibiotics. All but 1 of the maxillary and mandibular alveolar augmentations underwent endosteal implant placement approximately 4 to 6 months following grafting. The nasal reconstruction restored normal function and symmetry | Not reported | Using both the coronoid process of the mandible and the mandibular ramus as a source for autogenous bone graft can provide sufficient bone in quantity and quality for selected maxillofacial reconstructions. | [20] |
| 10 | Virtual Surgical Planning (VSP) and computer-aided design/computer-aided manufacturing (CAD/CAM) | In all cases we found presurgical planning was helpful to improve accuracy and significantly decrease intra-operative time. In cases where distraction was used, the planned and actual vectors were found to be accurate with excellent clinical outcomes. There were no complications except for one patient who experienced a wound infection post-operatively | Not reported | Preoperative planning using CAD/CAM and VSP allows for safe and precise craniofacial reconstruction in complex pediatric cases with a reduction of operative time | [21] |

| Row | Reconstruction method | Advantages of the method | Disadvantages of the method | Final result | Study (References) |
|-----|---|---|--|--|--------------------|
| 11 | Fully Digital Workflow (implant rehabilitation was accomplished with the assistance of computer-assisted design and manufacture, laser treatment, and selective laser melting techniques)From Visualized Iliac Bone Grafting | which did not alter the ultimate reconstruction. All patients experienced high satisfaction with their outcomes and excellent subjective aesthetic results were achieved These predictable, accurate, and effective digital techniques improved the consistency of pretreatment design and follow-up treatment. The treatment sequence achieved high predictability and reproducibility owing to the use of digital techniques | Not reported | a digital workflow can be predictable, accurate, and effective, which suggests that it could be a valid digital protocol for developing a treatment sequence for patients with jaw defects caused by trauma, congenital anomalies, or mandibular tumor resection | [22] |
| 12 | Group A patients (n=10) were treated with an autogenous coronoid process graft (ACPG) for reconstruction of the mandibular condyle, while group B patients (n=8) were treated by lateral arthroplasty (LAP); a temporalis myofascial flap (TMF) was used as interpositional material in both groups | Two patients in group A (20%) had reankylosis; no reankylosis was observed in group B patients. Compared with the ACPG, LAP improved the facial pattern and MIO significantly (P<0.05) | Two patients were treated with an autogenous coronoid process graft (ACPG) (20%) had reankylosis | LAP is a feasible and effective surgical method for the treatment of unilateral traumatic TMJ ankylosis when the displaced residual condyle is bigger than one third of the condylar head | [23] |
| 13 | poly(L-lactide) mesh combined with autogenous particulate cancellous bone and marrow | There were no signs of any other adverse effects, | one case where a section of the tray broke off late in the follow-up period | his method is stable and effective due to favourable morphological and functional recovery and low invasiveness. It may thus be a useful alternative procedure for mandibular reconstruction | [24] |
| 14 | non-vascularized iliac bone graft | overall success rate was 79.41%. 3(8.82%) of the bone grafts healed after infection, 4(11.76%) bone grafts lost because of infection | 4(11.76%) bone grafts lost because of infection | The autogenous non-vascularized iliac bone graft is one of the most important way for the reconstruction of mandibular defects. The methods of internal fixation includes titanium mini pate and bridging titanium plate | [25] |
| 15 | osteomuscular dorsal scapular flap | The pedicled osteomuscular dorsal scapular flap is an | Not reported | it may serve as the primary choice in patients with vascular pathology that precludes free | [26] |

| Row | Reconstruction method | Advantages of the method | Disadvantages of the method | Final result | Study (References) |
|-----|--|--|--|--|--------------------|
| 16 | autogenous bone grafts | <p>excellent choice for mandibular reconstruction</p> <p>The success rate found in this study was around 90%. Most patients were satisfied with their cosmesis and mouth opening at the recipient sites was in the normal range during last follow-up visits. Donor sites were primarily closed in all cases and there was no hypertrophic sca</p> | <p>7.6% of the cases showed poor results regarding facial contours and mouth opening</p> | <p>tissue transfer, as well as in resource-limited environments, as a secondary choice after a failed free flap reconstruction</p> <p>autogenous bone grafts are a reliable treatment modality for the reconstruction of mandibular bone defects with predictable aesthetic and functional outcomes. As the free vascularized fibular flap has the least resorption and failure rate, it should be the first choice for most cases of mandibular</p> | [27] |
| 17 | particulate cancellous bone and marrow (PCBM), platelet-rich plasma (PRP) compared with tray | <p>We could not detect any statistically significant differences in clinical data between the 2 groups, except for the timing of reconstruction. There were postoperative complications such as wound dehiscence and tray exposure, as well as infection of the reconstructed bone. The overall complication rate of the recipient sites in the intraoral group was 30% (3 of 10), whereas in the extraoral group, it was 0%. However, satisfactory bone formation was seen in all cases in the intraoral group (100% [10 of 10]) but only 87.5% (7 of 8) in the extraoral group</p> | <p>Not reported</p> | <p>using a tray with PCBM and PRP is a safe and reliable method for cases of benign tumor and trauma, even if immediate reconstruction is performed by an intraoral approach</p> | [28] |

Trento et al. [33] used osteogenic distraction technique to reconstruct jaw defects. The researchers believe that this method eliminates the need for bone removal and has better control over increasing bone volume and soft tissue at the same time. The results of this study showed that the use of this method is satisfactory.

Sales et al. [34] reconstructed jaw defects by iliac crest bone graft with planning through rapid prototyping. These researchers believed that this method has many benefits, including; Accurate plate compatibility with bone, shorter surgery time, reduced exposure time under general anesthesia, reduced blood loss, and shorter exposure time to intradermal tissues were noted. In this study, it was found that the duration of surgery was significantly reduced (approximately 50 minutes) and an excellent 2.4 mm reconstruction adaptation, consistent with the findings in the reference kits.

Junli Ma et al. [35] used virtual surgery and three-dimensional (3D) printing technique for fracture reconstruction in the mandible. The results of using this technique in one patient showed that the recovery process proceeded without any problems and the patient was satisfied with the condition of his jaw. The researchers believed that this technology enabled the surgeon to visualize the reconstruction process before surgery, to use it as a guide during surgery, and to perform more precise surgery in less time.

Gravvanis et al. [36] used free osseous flap fibula to reconstruct mandibular defects and free chimeric ALT / functioning vastus lateralis muscle to regenerate muscle in a person injured by a bullet. The results of this surgery showed that the muscles around the mouth were well regenerated and the patient had a normal smile socially and emotionally. The researchers report that a combination of osseous flap fibula with a chimeric functional ALT / Vastus Lateralis flap can be used in severe and complex injuries that also involve cosmetic issues.

Hatamleh et al. [37] used a computer design plus a titanium implant integrated with a selective laser to reconstruct mandibular defects in a 26-year-old man who had a deformity of the left mandible due to trauma. This patient showed satisfactory results of the combination of these two methods and it was found that computer design can assist in clinical interventions in the reconstruction process and increase their effectiveness [37].

Review of 9 case reports was another part of the present study. In these 9 articles, 9 different techniques in mandibular reconstruction in each patient have been studied and the results have been reported. Patients ranged in age from 26 to 52 years. These studies also used sharp computer design, the results of which were satisfactory, and the researchers of these studies emphasized that the computer can be of great help to the surgeon. The use of Free Flaps was also introduced as a reliable method and its effectiveness in reconstructing mandibular defects was confirmed. Prototyping was also a regenerative technique for which researchers cited many benefits. They believed that using prototyping reduced surgery time, reduced patient blood loss, reduced anesthesia time, and reduced healing time, and that plaque formed with bone. It is more compatible. Osteogenic distraction was another technique used. The results of using this method in the patient showed that the need for bone removal is eliminated and there is better control over the increase in bone volume and soft tissue. Bone slat was also one of the techniques used to create the ideal volume for implant placement. These results are shown in Table 2.

2.4.2 Review studies

Divi et al. [38] in a review study discussed new tools and methods of mandibular reconstruction and their evolution process. In this article, they state that the use of Computer-aided design (CAD) can help the surgeon a lot and increase their control over the surgical process and increase the surgeon's creativity.

Chim et al. [39] have examined the methods of mandibular reconstruction and their leveling in a review study. In this study, they found that vascularized bone flaps are the best option for reconstructing mandibular defects and are a gold standard.

Khatib et al. [40] used computer in the surgery of mandibular defects due to gunshot wounds. They found that with the help of surgical visualization software and the help of a surgeon, accurate dimensions can be designed with the highest chance of performing the best reconstruction both functionally and aesthetically.

Shnayder et al. [41] reviewed new studies in mandibular reconstruction. In this study, they stated that a method cannot be recommended for all patients, but should be selected according to the patient's condition, functional and aesthetic goals, as well as the type of defect of a method.

Table 2. Case report studies about mandibular reconstruction methods

| Row | Reconstruction method | Advantages of the method | Disadvantages of the method | Final result | Study (references) |
|-----|---|--|--|---|--------------------|
| 1 | bone slat technique | The surgical technique was found to be easy in terms of technique and surgical trauma | Not reported | bone augmentation achieved with this technique created the ideal bone volume of hard and soft tissue, in quantity and quality, for placement of implants | [29] |
| 2 | two neighboring mandibular central incisors were replaced by two implants after soft and hard tissue augmentation with the cortical bone plate method | The interdental soft tissue was reconstructed with remarkable success | Not reported | The interdental soft tissue was reconstructed with remarkable success | [30] |
| 3 | Flapless implant placement | decreased trauma, short recovery time, less pain, reduced rate of infection, improved patient compliance, and decreased bone loss and inflammation due to improved vascularity | The limitations of these surgical procedures depend on the quantity and quality of the soft and hard tissues | The lack of visualization requires greater surgical skill and preoperative planning than conventional procedures. When used carefully and in the proper situations, this surgical protocol allows patients to benefit from improved implant treatment | [31] |
| 4 | free vascularized fibula flap | The increase of vertical bone height was stable and enabled placement of dental implants without any complications. In conclusion, we consider that vertical distraction osteogenesis of free vascularized flaps is a reliable technique that optimizes implant positioning for ideal prosthetic rehabilitation, after mandibular reconstruction following tumor surgery | Not reported | vertical distraction osteogenesis of free vascularized flaps is a reliable technique that optimizes implant positioning for ideal prosthetic rehabilitation | [32] |
| 5 | osteogenic distraction technique | this technique eliminates the need of harvesting bone and enables a better control of the increasing bone volume as well as soft tissue | | it can be concluded that distraction osteogenesis is an available technique for larger vertical bone defects | [33] |

| Row | Reconstruction method | Advantages of the method | Disadvantages of the method | Final result | Study (references) |
|-----|---|--|-----------------------------|---|--------------------|
| 6 | iliac crest bone graft with planning through rapid prototyping | <p>simultaneously. The reported cases were performed as expected based on literature results achieving satisfactory outcomes.</p> <p>a precise adaptation of the plaque to the bone, a shorter surgical time, decrease in the exposure time to general anesthesia, reduce blood loss, and a shorter exposure time of the intradermal tissues.</p> <p>significant reduction in surgical time (approximately 50 minutes), besides an excellent adaptation of the reconstruction 2.4 mm system, which corroborates with the bibliographic findings.</p> <p>no postoperative complications and there was a satisfactory bone neoformation in the bone defect site,</p> <p>visualized on multislice computed tomography 3 dimension</p> | Not reported | Biomodels should be required in complex cases because they help to decrease surgical time and to increase the predictability of the procedure | [34] |
| 7 | virtual surgery and three-dimensional (3D) printing technique | <p>Virtual surgical planning combined with 3D printing technology enables surgeon to visualize the reduction process preoperatively and guide intraoperative reduction, making the reduction less time consuming and more precise. 3D-printed titanium mesh tray can provide more satisfactory esthetic outcomes in treating complex comminuted mandibular fractures</p> | Not reported | The healing process was uneventful, and the patient was satisfied with the mandible contour | [35] |
| 8 | A single stage reconstruction with two free flaps was planned; a free fibula osseous flap to reconstruct the mandibular defect, and a free chimeric | The one skin paddle of the chimeric flap reconstructed the buccomandibular/suborbital zones of the cheek, and the other the lining of the mouth. The functional muscle provided reanimation of the corner of the mouth by coapting | Not reported | combined use of a fibula osseous flap with a chimeric functional ALT/Vastus Lateralis flap suggests that the chimeric flap principle may be | [36] |

| Row | Reconstruction method | Advantages of the method | Disadvantages of the method | Final result | Study (references) |
|-----|---|--|-----------------------------|---|--------------------|
| 9 | ALT/functioning vastus lateralis muscle Computer-Aided Design/Computer-Aided Manufacture + Selective-Laser Sintered Titanium Implant | the muscle's motor nerve to the ipsilateral marginal mandibular nerve. A good facial contour and reanimation of the mouth with oral continence was achieved, and the patient presented with good social and emotional smile This patient confirms the advantages of 3D computer-aided design/computer-aided manufacture technologies in optimizing clinical outcomes for cranio-maxillofacial reconstruction, especially when conducting two simultaneous clinical procedures | Not reported | used in complex aesthetic and functional challenges of severe facial trauma confirms the advantages of 3D computer-aided design/computer-aided manufacture technologies in optimizing clinical outcomes for cranio-maxillofacial reconstruction, especially when conducting two simultaneous clinical procedures | [37] |

Table 3. Review studies about mandibular reconstruction methods

| Row | Reconstruction method / Objective | Advantages of the method | Disadvantages of the method | Study (references) |
|-----|--|--|-----------------------------|--------------------|
| 1 | highlight many of these relatively newer tools and discuss their evolving role in mandibular reconstruction. | The use of CAD has allowed for earlier dental rehabilitation by more accurately modeling the expected position of the bone grafts, determining the position of implants, and guiding the design of the prosthesis. Additive manufacturing gives surgeons an unprecedented level of control in designing plates allowing for new creative designs. These new technologies will be important in the next stage of mandibular reconstruction as tissue engineering begins to play a more prominent role | Not reported | [38] |
| 2 | discuss classification and approach to reconstruction of mandibular defects | Vascularized bone flaps are the best option for a functional and aesthetic reconstruction, with the free fibula flap remaining the gold standard for mandible reconstruction. Reconstruction with alternative flaps such as | | [39] |

| Row | Reconstruction method / Objective | Advantages of the method | Disadvantages of the method | Study (references) |
|-----|---|--|--|--------------------|
| 3 | discuss about computer-aided surgery | scapula, iliac crest, and radial forearm flaps results in good outcomes in patients in whom fibula flaps are not available best chance of establishing proper facial width, projection, and contour to produce a functional and reasonably esthetic facial reconstruction | Not reported | [40] |
| 4 | This review examines the current literature on functional outcomes of lateral mandibular reconstruction and presents an algorithm on selecting an optimal reconstructive choice for patients with lateral mandibular defects resulting from oncologic ablative surgery or traum | Depending on the predominance of the soft-tissue or bony components of the defect, with consideration of the patient's characteristics and functional and aesthetic goals, the surgeon can wisely select from these reconstructive possibilities | Not reported | [41] |
| 5 | This systematic review sought scientific evidence regarding the best indication for the use of three-dimensional (3D) plates in the treatment of mandibular fractures | The success rate of 3D plates was high at this location compared to other methods of fixation. the use of 3D plates for the treatment of mandibular fractures is recommended | Not reported | [42] |
| 6 | perform a systematic literature review on mandibular reconstruction for segmental mandibular bone defects using non-vascularized bone grafts to answer the following question: Is there scientific evidence to support the use of this technique? | Although standardized randomized controlled clinical studies are needed to obtain better clinical evidence for treatment choices in general, the use of non-vascularized bone grafts for mandibular reconstruction showed an 87.6% success rate in this review | The restoration of bone defects due to malignant tumours treated with radiation therapy had lower success rates, and these appear to be a contraindication for the technique | [43] |
| 7 | test whether there is a significant difference in the clinical outcomes between locking and non-locking plate fixation in the management of mandibular fractures | The test for overall effect showed that the difference between the procedures did not significantly affect the incidence of postoperative complications (P = 0.21), with RR 0.79 (95% CI 0.54–1.14). | Not reported | [44] |

Oliveira et al. [42] in a systematic review study examined how to use three-dimensional plates in the reconstruction of mandibular defects. The results of this systematic review showed that the success rate of using 3D plates is high compared to other stabilization methods and the use of this method was recommended by these researchers.

Moura et al. [43] reviewed the scientific evidence to evaluate the results of using non-vascularized bone grafts to reconstruct mandibular defects. They wanted to answer the question, is there any scientific evidence to support this technique? The results of this study indicate that although more clinical studies are needed for better scientific citation, but according to the study, the success rate of non-vascularized bone grafting was 87.6%. It has also been pointed out that if the mandibular defects are due to malignant tumors and radiotherapy is usually used in these cases, the success rate of non-vascularized bone grafting is greatly reduced, so in these cases a method Not optional.

Chrcanovic [44] designed and conducted a review study to compare the clinical results of locking and non-locking fixation plates in mandibular fractures. Findings showed that postoperative clinical results were not significantly different between the two methods ($P = 0.21$), with RR 0.79 (95% CI 0.54–1.14).

In this study, 7 review articles were reviewed, two of which dealt with the use of computers in mandibular surgery. These two articles reviewed the functions of computer software in visualizing the operation and the result of reconstruction. Both articles emphasized that the use of a computer would help the surgeon to perform the operation more accurately, thus restoring jaw defects with better clinical as well as aesthetic results.

In two studies, the results of non-vascularized bone graft as well as vascularized bone flaps were reviewed. Both methods were introduced by these researchers as effective methods and Vascularized bone flaps were introduced as the gold standard for mandibular reconstruction. However, the researchers' recommendation in using these methods is that; In cases where the jaw defect is due to surgery for malignant tumors and the patient may be exposed to radiation or chemotherapy, the chances of success of these methods are reduced and these reconstruction methods should be used with more consideration.

The use of 3D plates for fixation in mandibular defect surgery was also reviewed by other researchers. The reviewed results of various studies in this field showed that 3D panels are more effective than other similar methods in fixing. Is high and was introduced as an effective method.

One study also found that locking and unlocking fixation plates in mandibular reconstruction did not differ significantly in surgical outcome, and neither was superior to the other.

The results of these seven review articles are that Vascularized bone flaps are an effective method of reconstructing mandibular defects, and the use of computer software can increase surgical success. They experience fewer side effects, have more beautiful faces, and thus have more satisfaction. These results are shown in Table 3.

3. CONCLUSION

The present study reviewed 33 different articles on the reconstruction of mandibular defects. The mandible is very important in the physical, mental and social health of human beings because in addition to helping respiration, swallowing, chewing has a great role in the beauty of the face and helps to establish social relations by helping speech. Defects in this organ can cause many complications for a person and affect his quality of life. For these reasons, maxillofacial surgeons and specialists in recent years have studied and applied various techniques to repair the defects of this organ, each of which has yielded results. Among the existing methods, the use of free vascularized fibular flap has been approved as a widely used and reliable method in various studies, and many researchers believe that this technique is the gold standard for the reconstruction of mandibular defects. In this method, blood vessels and nerves are delivered to the organ again [45]. The success rate of this method is estimated between 90 and 94% [46-48]. The choice of the part of the body whose tissue is separated and transferred to the jaw depends on various factors, including the type of replacement tissue and the damaged part of the jaw [46, 49-51]. The types of flaps used to reconstruct the jaw and face are: Fibula free flap, Radial forearm free flap, Scapular free flap and Iliac crest free flap.

Flaps are pieces of tissue that maintain their vascular connection to the underlying tissues,

making the flaps live tissue when they are transferred [52], but grafts, They do not have a healthy blood supply [52]. This property of flaps makes the result of their use more satisfactory.

Fibula free flap: This flap is especially used for mandibular reconstruction [46, 53-55] and can correct angular defects with it [11]. Disadvantages of using this flap are numbness of the feet and toes and causing complications in the donor area [11].

Radial forearm free flap: This flap is mainly used to repair lateral defects and is useful when the goal is to reconstruct the anterior part of the maxilla, areas without mandibular teeth [56] and when the soft tissue needs to be reconstructed [11]. The main disadvantage of using this flap is the defect in the donor part, such as movement disorders and lack of donor part [1].

Scapular free flap: This type of flap is an osteocutaneous flap that is recommended when there are complex defects that involve the skin of the face, mucosa, and bone [57]. This flap accepts dental implants well and has a success rate of 89% [58].

Iliac crest free flap: This flap is the best bone tissue for dental implants [53]. The success rate of using this flap in jaw reconstructions is estimated to be 96% in one study [59].

Non-vascularized bone was another technique that, although not as widely used as free vascularized fibular flap, has been used in some cases and has yielded satisfactory results.

Nonvascularized Bone grafts are used to repair small defects of the mandible and are not useful when the defect is in soft tissue [3]. The main limitation of this method is that it can not be used for patients undergoing radiation therapy. If this method is used in this group of patients, the probability of success is very low and high side effects are usually observed. It should also be noted that most people who need mandibular reconstruction are those who have squamous cell carcinoma and are usually undergoing radiation therapy [3].

The use of computer software was another method studied, which in many cases was used as a complementary technique and improved surgical results. Computer software with three-dimensional designs allows the surgeon to visualize a picture of the operation process and

its result before the operation, and use this visualization during the surgery and figure out more accurate surgery. For this reason, these techniques are used as an assistant for the surgeon to help him decide on the type and method of reconstruction, as well as to be more careful during surgery.

Prototyping was also used in a limited number of studies, which produced satisfactory results, but the number of these studies is not enough and needs to be addressed more than before.

DECLARATION

Amendments

Important protocol amendments post registration will be recorded and included in dissemination.

Support

No sources of support or funding were provided for this review. Authors are based on their self finance.

CONSENT

It is not applicable.

ETHICAL APPROVAL

It is not applicable

ACKNOWLEDGEMENT

The completion of this undertaking could not have been possible without the participation, guiding and assistance of my lovely husband Dr.majid zolfagharikhoshaneh, i would like to express my deep appreciation and indebtedness to him for his endless support.

As well one of our best former professor Dr Joseph Charles Herrero for his wise advice not limited to this work but during all of our professional practice above all, to the great almighty, the author of knowledge and wisdom for his countless love.

COMPETING INTERESTS

Authors have declared that no competing interests exist.

REFERENCES

1. Mehta RP, Deschler DG. Mandibular reconstruction in : an analysis of different techniques. *Current opinion in otolaryngology & head and neck surgery*. 2004;12(4):288-93.
2. Al-Ahmari A, Nasr EA, Moiduddin K, Anwar S, Kindi MA, Kamrani A. A comparative study on the customized design of mandibular reconstruction plates using finite element method. *Advances in Mechanical Engineering*. 2015;7(7):1687814015593890.
3. Benjamin W. Mandibular reconstruction: Special considerations in TMJ and condyle reconstruction; 2010. Available:<https://www.utmb.edu/otoref/Grnds/mandib-recon...08.../mandib-recon-2010-08.pdf>.
4. Oshida Y, Tuna EB, Aktören O, Gençay K. Dental implant systems. *International journal of molecular sciences*. 2010;11(4):1580-678.
5. Markwardt J, Weber T, Modler N, Sembdner P, Lesche R, Schulz MC, et al. One vs. two piece customized implants to reconstruct mandibular continuity defects: a preliminary study in pig cadavers. *Journal of Cranio-Maxillofacial Surgery*. 2014;42(6):790-5.
6. Bujtár P, Simonovics J, Váradi K, Sándor GK, Avery C. The biomechanical aspects of reconstruction for segmental defects of the mandible: a finite element study to assess the optimisation of plate and screw factors. *Journal of Cranio-Maxillofacial Surgery*. 2014;4.62-855:(6)2
7. Louis PJ, Gutta R, Said-Al-Naief N, Bartolucci AA. Reconstruction of the maxilla and mandible with particulate bone graft and titanium mesh for implant placement. *Journal of Oral and Maxillofacial Surgery*. 2008;66(2):235-45.
8. Schrag C, Chang YM, Tsai CY, Wei FC. Complete rehabilitation of the mandible following segmental resection. *Journal of surgical oncology*. 2006;94(6):538-45.
9. Mukerji R, Mukerji G, McGurk M. Mandibular fractures: Historical perspective. *British Journal of Oral and Maxillofacial Surgery*. 2006;44(3):222-8.
10. Esposito M, Grusovin MG, Coulthard P, Worthington HV. The efficacy of various bone augmentation procedures for dental implants: a Cochrane systematic review of randomized controlled clinical trials. *International Journal of Oral & Maxillofacial Implants*. 2006;21(5).
11. Ó'Fearraigh P. The Modern Methods in the Surgical Reconstruction and Rehabilitation of the Orofacial Region: A Review of the Literature. *TSMJ*. 2008;9:44-7.
12. Pototschnig H, Schaff J, Kovacs L, Biemer E, Papadopulos NA. The free osteofasciocutaneous fibula flap: clinical applications and surgical considerations. *Injury*. 2013;44(3):366-9.
13. Muñoz R, Gajos G, Bladimir J, Carvajal D, Luis A, Speranza GDV. Protocol for mandibular reconstruction with zygomatic implants (zygomatic mandibular implant). *Oral and maxillofacial surgery*. 2018;22(1):39-44.
14. Ayali A, Bilginaylar K. Evaluating the biomechanical effects of implant diameter in case of facial trauma to an edentulous atrophic mandible: a 3D finite element analysis. *Head & face medicine*. 2017;13(1):5.
15. Zou D, Wang F, Wu Y, Huang W, Zhang C, Zhang Z. Implant-Supported Telescopic Crown-Retained Overdentures for Oral Rehabilitation of Patients with Severe Bony Defects: A 5-Year Retrospective Study. *International Journal of Oral & Maxillofacial Implants*. 2015;30(4).
16. Pingarrón-Martín L, Otero TG, Gallo LA. Experience with mandibular reconstruction using transport-disc-distraction osteogenesis. *Cranio-maxillofacial trauma & reconstruction*. 2.22-117:(02)8:015
17. Fang W, Liu Y-p, Ma Q, Liu B-L, Zhao Y. Long-term results of mandibular reconstruction of continuity defects with fibula free flap and implant-borne dental rehabilitation. *International Journal of Oral & Maxillofacial Implants*. 2015.1)30;
18. Sabhlok S, Waknis PP, Gadre KS. Applications of coronoid process as a bone graft in maxillofacial surgery. *Journal of Craniofacial Surgery*. 2014;25(2):577-80.
19. Herford AS, Tandon R, Stevens TW, Stoffella E, Cicciu M. Immediate distraction osteogenesis: the sandwich technique in combination with rhBMP-2 for anterior maxillary and mandibular defects. *Journal of Craniofacial Surgery*. 2013;24(4):1383-7.

20. Amrani S, Anastassov GE, Montazem AH. Mandibular ramus/coronoid process grafts in maxillofacial reconstructive surgery. *Journal of Oral and Maxillofacial Surgery*. 2010;68(3):641-6.
21. Gray R, Gougoutas A, Nguyen V, Taylor J, Bastidas N. Use of three-dimensional, CAD/CAM-assisted, virtual surgical simulation and planning in the pediatric craniofacial population. *International journal of pediatric otorhinolaryngology*. 2017;97:163-9.
22. Tian T, Zhang T, Ma Q, Zhang Q, Cai X. Reconstruction of Mandible: A Fully Digital Workflow From Visualized Iliac Bone Grafting to Implant Restoration. *Journal of Oral and Maxillofacial Surgery*. 2017;75(7):1403. e1-. e10.
23. Xu F, Jiang L, Man C. A comparative study of different surgical methods in the treatment of traumatic temporomandibular joint ankylosis. *International journal of oral and maxillofacial surgery*. 2017;46(2):198-203.
24. Yagihara K, Okabe S, Ishii J, Amagasa T, Yamashiro M, Yamaguchi S, et al. Mandibular reconstruction using a poly (L-lactide) mesh combined with autogenous particulate cancellous bone and marrow: a prospective clinical study .*International journal of oral and maxillofacial surgery*. 2013;42(8):962-9.
25. Xie F, Sun J. Analysis of reconstruction using non-vascularized iliac bone graft for patients with mandibular defects. *Hua xi kou qiang yi xue za zhi= Huaxi kouqiang yixue zazhi= West China journal of stomatology*. 2012;30(4):411-3.
26. Nthumba PM. Use of the osteomuscular dorsal scapular flap in the reconstruction of mandibular defects. *Annals of plastic surgery*. 2013;70(1):53-6.
27. Rana M, Warraich R, Kokemüller H, Lemound J ,Essig H, Tavassol F, et al. Reconstruction of mandibular defects-clinical retrospective research over a 10-year period. *Head & neck oncology*. 2011;3(1):23.
28. Matsuo A, Chiba H, Toyoda J, Abukawa H, Fujikawa K, Tsuzuki M, et al. Mandibular reconstruction using a tray with particulate cancellous bone and marrow and platelet-rich plasma by an intraoral approach. *Journal of Oral and Maxillofacial Surgery*. 2011;69(6):1807-14.
29. D'Amato S, Tartaro G, Iтро A, Santagata M. Mandibular bone regeneration after bone slat technique. *Annali di stomatologia*. 2017;8(1):39.
30. Bäumer D, Zuhr O, Hürzeler M. Replacement of mandibular central incisors with implant-supported crowns: a case report. *The international journal of esthetic dentistry*. 2016;11(2):204-18.
31. Jain D, Gaur G. Flapless implant placement: a case report. *Journal of Oral Implantology*. 2014;40(3):321-4.
32. Cho-Lee G-Y, Naval-Gías L, Martos-Díaz PL, González-García R, Rodríguez-Campo FJ. Vertical distraction osteogenesis of a free vascularized fibula flap in a reconstructed hemimandible for mandibular reconstruction and optimization of the implant prosthetic rehabilitation. Report of a case. *Med Oral Patol Oral Cir Bucal*. 2011;16(1):e74-e8.
33. dos Santos Trento G, Reis JMdSN, Hochuli-Vieira E, Pereira-Filho VA. Mandibular Reconstruction by Osteogenic Distraction Due to Two Different Injuries. *Journal of Craniofacial Surgery*. 2018;29(2):e133-e5.
34. Sales PHdH, Cetira F, Luiz E, Oliveira Neto JQd, Silva JCd, Aguiar ASWd, et al. Rapid Prototyping as an Auxiliary in Mandibular Reconstructions. *Journal of Craniofacial Surgery*. 2017;28(8):e744-e5.
35. Ma J, Ma L, Wang Z, Zhu X, Wang W. The use of 3D-printed titanium mesh tray in treating complex comminuted mandibular fractures: a case report. *Medicine*. 2.(27)96:017
36. Gravvanis A, Apostolou K, Anterriotis D, Tsoutsos D. Single stage aesthetic and functional reconstruction of composite facial gunshot wound with a chimeric functioning muscle and fibular osseous flap. Case report and review of the literature. *Microsurgery*. 2017;37(6): 674-9.
37. Hatamleh MM, Bhamrah G, Ryba F, Mack G, Huppa C. Simultaneous computer-aided design/computer-aided manufacture bimaxillary orthognathic surgery and mandibular reconstruction using selective-laser sintered titanium implant. *Journal of Craniofacial Surgery*. 2016;27(7): 1810-4.

38. Divi V, Schoppy DW, Williams RA, Sirjani DB. Contemporary mandibular reconstruction. Current opinion in otolaryngology & head and neck surgery. 2016;24(5):433-9.
39. Chim H, Salgado CJ, Mardini S, Chen H-C, editors. Reconstruction of mandibular defects. Seminars in plastic surgery; 2010: © Thieme Medical Publishers.
40. Khatib B, Gelesko S, Amundson M, Cheng A, Patel A, Bui T, et al. Updates in management of craniomaxillofacial gunshot wounds and reconstruction of the mandible. Facial Plastic Surgery Clinics. 2017;25(4):563-76.
41. Shnayder Y, Lin D, Desai SC, Nussenbaum B, Sand JP, Wax MK. Reconstruction of the lateral mandibular defect: A review and treatment algorithm. JAMA facial plastic surgery. 2015;17(5):367-73.
42. de Oliveira J, Moura L, de Menezes J, Gabrielli M, Pereira Filho V, Hochuli-Vieira E. Three-dimensional strut plate for the treatment of mandibular fractures: a systematic review. International journal of oral and maxillofacial surgery. 2018;47(3):330-8.
43. Moura L, Carvalho PdA, Xavier C, Post L, Torriani M, Santagata M, et al. Autogenous non-vascularized bone graft in segmental mandibular reconstruction: a systematic review. International journal of oral and maxillofacial surgery. 2016;45(11):1388-94.
44. Chrcanovic B. Locking versus non-locking plate fixation in the management of mandibular fractures: a meta-analysis. International journal of oral and maxillofacial surgery. 2014;43(10):1243-50.
45. Mitchell DA. An introduction to oral and maxillofacial surgery: CRC Press; 2014.
46. Burkey BB, Coleman JJ. Current concepts in oromandibular reconstruction. Otolaryngologic clinics of North America. 1997;30(4):607-30.
47. Robb G. Free-Flap Mandibular Reconstruction: A 10-Year Follow-up Study. Archives of Facial Plastic Surgery. 2004;6(1):65-6.
48. Pohlenz P, Blessmann M, Blake F, Li L, Schmelzle R, Heiland M. Outcome and complications of 540 microvascular free flaps: the Hamburg experience. Clinical oral investigations. 2007;92(1):111;
49. Urken ML, Buchbinder D, Costantino PD, Sinha U, Okay D, Lawson W, et al. Oromandibular reconstruction using microvascular composite flaps: report of 210 cases. Archives of otolaryngology-head & neck surgery. 1998;124(1):46-55.
50. Frodel JJ, Funk GF, Capper DT, Fridrich KL, Blumer JR, Haller JR, et al. Osseointegrated implants: a comparative study of bone thickness in four vascularized bone flaps. Plastic and reconstructive surgery. 1993;92(3):449-55; discussion 56-8.
51. Hidalgo DA, Pusic AL, Wei F-C. Free-flap mandibular reconstruction: a 10-year follow-up study. Plastic and reconstructive surgery. 2002;110(2):438-49.
52. Chandu A, Bridgeman A, Smith AC, Flood S. Reconstructive techniques for the repair of oral and maxillofacial oncological procedures: What are they, how do they work and what do they look like? Australian dental journal. 2002;47(2):99-105.
53. Genden E, Haughey BH. Mandibular reconstruction by vascularized free tissue transfer. American journal of otolaryngology. 1996;27-219:(4)17;
54. Shaw RJ, Sutton AF, Cawood JI, Howell RA, Lowe D, Brown JS, et al. Oral rehabilitation after treatment for head and neck malignancy. Head & Neck: Journal for the Sciences and Specialties of the Head and Neck. 2005;27(6):459-70.
55. Brown J, Magennis P, Rogers S, Cawood J, Howell R, Vaughan E. Trends in head and neck microvascular reconstructive surgery in Liverpool (1992–2001). British Journal of Oral and Maxillofacial Surgery. 2006;44(5):364-70.
56. Villaret DB, Futran NA. The indications and outcomes in the use of osteocutaneous radial forearm free flap. Head & Neck: Journal for the Sciences and Specialties of the Head and Neck. 2003;25(6): 475-81.
57. Deschler DG, Hayden RE. The optimum method for reconstruction of complex lateral oromandibular- cutaneous defects. Head & Neck: Journal for the Sciences and Specialties of the Head and Neck. 2000;22(7):674-9.

58. Urken ML, Bridger AG, Zur KB, Genden EM. The scapular osteofasciocutaneous flap: a 12-year experience. Archives of otolaryngology-head & neck surgery. 2001;127(7):862-9.
59. Shenaq SM, Klebuc MJ. The iliac crest microsurgical free flap in mandibular reconstruction. Clinics in plastic surgery. 1994;21(1):37-44.

© 2021 Hassannia and Ghorbanizadeh; This is an Open Access article distributed under the terms of the Creative Commons Attribution License (<http://creativecommons.org/licenses/by/4.0>), which permits unrestricted use, distribution, and reproduction in any medium, provided the original work is properly cited.

Peer-review history:
The peer review history for this paper can be accessed here:
<https://www.sdiarticle4.com/review-history/73051>