



Free Gingival Graft in a Patient with Systemic Sclerosis: A Case Report

Layal Bou Semaan ^{a*}, Carole Chakar ^{a^o} and Gabriel Menassa ^a

^a *Periodontology Department, Faculty of Dental Medicine, Saint Joseph University of Beirut, Private Practitioner, Beirut, Lebanon.*

Authors' contributions

This work was carried out in collaboration among all authors. All authors read and approved the final manuscript.

Article Information

Open Peer Review History:

This journal follows the Advanced Open Peer Review policy. Identity of the Reviewers, Editor(s) and additional Reviewers, peer review comments, different versions of the manuscript, comments of the editors, etc are available here: <https://www.sdiarticle5.com/review-history/86007>

Received 02 February 2022

Accepted 10 April 2022

Published 15 April 2022

Case Study

ABSTRACT

Scleroderma is a rare chronic connective tissue disorder with unknown etiology characterized by an excessive deposition of collagen in multi-organ systems. It can result in vascular anomalies, excess fibrosis, and autoimmune phenomenon. Patients with this condition can develop complex oral and periodontal manifestations requiring extreme care. Periodontal complications such as increased bone loss and gingival recessions are common in subjects with scleroderma. The oral management of a patient with gingival recessions using a free gingival graft (FGG) technique is presented in this case report.

Keywords: *Gingival graft; systemic sclerosis; autoimmune chronic disease.*

1. INTRODUCTION

Sclerosis is defined as an autoimmune chronic disease of unknown etiology characterized by increased collagen synthesis and its deposition within the connective tissue and blood vessels.

Localized sclerosis involves only the skin and can be classified into plaque, bullous, linear, and deep, whereas systemic sclerosis (SSc) may affect any organ system and could be classified into three subtypes: limited cutaneous, diffuse cutaneous and overlap syndrome [1-3]. Based on

[≡]Resident;

^oProfessor;

[#]Head

*Corresponding author: Email: layal.bs@live.com;

the expanse of the fibrosis, systemic sclerosis could be classified as limited cutaneous (lcSSc) when the face, neck, region distally to the elbows and knees are involved or as diffuse cutaneous (dcSSc) when proximal limbs, trunk and internal organs are also affected [4].

2. SIGNS AND SYMPTOMS

A thickening and hardening of the skin are one of the major signs. It's due to a pathological accumulation of connective tissue components that leads to the loss of cutaneous elasticity followed by sclerosis. Kidneys, lungs, heart, and gastrointestinal system are affected in the systemic form either by fibrosis or by a diminished blood supply. A damage in the peristalsis of the esophagus and colon with a reduced tonus associated to a decreased secretion are mainly responsible of the gastrointestinal tract symptoms [5,6]. Raynaud's phenomenon (paroxysmal vasospasm), claw-like fingers, hyperpigmentation, telangiectasia, and subcutaneous calcification are common systemic manifestations that can be observed. A facial skin hardening with a classic mask-like face with a sharp nose and deep wrinkle are common. However, another form of systemic sclerosis characterized by an impairment of the organs and internal systems but absence of the skin hardening and Raynaud's phenomenon, is also observed [4,5].

Common oral manifestations reported are the followings:

- Limitation of mouth opening with multiple implications such as social concerns, difficulties with mastication, in maintaining oral hygiene and in dental and oral surgical procedures [7-9].
- Xerostomia occurring because of fibrosis of the salivary glands causes high caries rate and Candida infections in some patients. Removable prostheses could be also problematic due to a decreased salivary flow [10]. A high frequency of Sjögren's syndrome was also detected in sclerotic patients [11].
- Tongue rigidity with restricted mobility due to a reduced length of the frenulum and increased thickness [5].
- Dry eyes with keratoconjunctivitis sicca or xerophthalmia [12].
- Widening of the periodontal ligament [13,14].

- Telangiectasia [15].
- Bone resorption [16].
- Temporomandibular joint symptoms [2].
- Apical root resorption [17].
- Pulp and periodontal ligament calcifications [18].
- Pathological resorption of the condylar processes [19].

3. HEALING DISRUPTION IN PATIENTS WITH SCLERODERMA

Vascular anomalies, excess fibrosis and autoimmune phenomenon are three primary mechanisms that contribute to scleroderma [10,20]. Concerning vascular anomalies, the balance between vasodilator and vasoconstrictor molecules plays a major role in the stability of the vascular endothelium in a physiological situation. A perturbed vascular tone and disturbed interconnection between endothelial cells, vascular smooth cells and extracellular matrix is detected in systemic sclerosis. Increased activity of Von Willebrand factor may have a part in the evolution of the vascular lesion in scleroderma [21]. Additionally, T-cells release elevated levels of cytokines, such as interleukin, that induce fibroblast activity and bind to endothelial cells. Fibroblasts become active and secrete collagen and extracellular matrix products in an abnormal quantity whereas collagenase' activity is reduced [10]. Collagen IV, fibronectin, and proteoglycan are more produced by dermal fibroblasts of patients with systemic sclerosis compared to skin of healthy controls. These fibroblasts express alpha-smooth muscle actin (α -SMA) and differentiate into myofibroblasts that produce more collagen [22]. Even though the disease is not considered as autoimmune, immunosuppression remains the most recommended treatment to limit organs' fibrosis. The detection of specific autoantibodies can help in the diagnosis and the estimation of the prognosis of the SSc [20,23]. In early lesions, an activation of primarily T-cell lymphocytes with an imbalance in the T-helper cell phenotype, responsible for further tissue injury and fibrotic reaction, is observed in histologic sections [24]. Vascular disruption has been recognized as a key element of the SS disease process with the manifestation of Raynaud's phenomenon affecting both large and small vessels throughout the body. Reduced vasodilation or an increased vasoconstriction are also consequences of the adventitial fibrosis associated with a decreased blood flow [25].

Endothelial progenitor cells (EPC) promote neovascularization either by direct differentiation into mature endothelial cells causing vasculogenesis, or by activating the secretion of proangiogenic factors causing angiogenesis. In SS patients, circulating EPCs are present with an impaired neovascularization and the defects are likely due to an impaired function of EPCs irrespectively of their quantity [26]. Del Papa et al in 2006 stated that EPCs were modified before their release into the circulation and altered stem cells become hyporesponsive to proangiogenic signals [27].

4. PERIODONTAL MANIFESTATIONS IN PATIENTS WITH SCLERODERMA

Healing impairment could explain a higher periodontitis prevalence detected in patients with SSc [18,28-31]. Patients with SSc present with deep periodontal pockets with widening of the periodontal ligament and abnormalities in periodontal microcirculation [27]. Scardina et al in an observation of the periodontal microcirculatory defects using capillaroscopy in patients with systemic sclerosis, found that alterations are not only in the deep but also in the peripheral circulation of the periodontal mucosa associated with reduced number but greater diameter and tortuosity of the capillaries and this plays a major role in periodontal disease in SSc patients [32]. Therefore, tissue ischemia due to reduced vascularity increases susceptibility to periodontal disease leading to an increase in teeth mobility [12].

The restricted mouth opening is a common finding in SSc affecting the quality of lives of patients with scleroderma making it difficult to maintain daily oral hygiene and for the dentists to conduct the oral exam increasing the risk of periodontal disease [12,28].

The gingival crevicular fluid (GCF) at the gingival crevice is the first line of defense against bacterial attacks [33]. Patients with SSc have higher indices of periodontal inflammation and higher TNF α level in GCF than healthy individuals which play an important role in pathogenesis [34].

It was stated that 14% of patients with scleroderma present a concomitant Sjögren syndrome. This is mainly due to glandular fibrosis. Xerostomia and immunosuppressive

drugs make individuals with systemic sclerosis prone to oral infections, dental caries, candidiasis, and periodontal disease with tooth loss when compared to the general population [35].

5. CASE REPORT

A 32-year-old female suffering from systemic scleroderma was referred for consultation at the Department of Periodontology in Saint Joseph University of Beirut, Lebanon. The patient has a small posture, indurated fingers on palpation with areas of telangiectasia, skin involvement with a mask-like face appearance, deep wrinkles, and a sharp nose (Fig. 1). Oral examination revealed microstomia (Figs. 2 & 3) due to rigid perioral skin with a limited mouth opening of 35 mm (Fig. 4). Her chief complaint was severe difficulty of eating. The main purpose of her visit was to place implants. However, radiographs revealed moderate to severe bone loss in the mandible and maxilla complicating the placement of implants. Additionally, considerable degree of labial gingival recession was found on the upper canine and all the anterior mandibular teeth. Due to the extent of the recessions with the increasing mobility, a free gingival graft (FGG) was proposed to the patient to stabilize the case. After explaining to the patient about the probability of a poor outcome due to the poor vascularity of the area and the risk of infection or further scarring, she insisted on getting the treatment performed and accepted to sign an informed consent.

Clinically, RT2 recessions were detected on teeth #42,41 and 31 (Fig. 5) [36]. The main purpose of the treatment was not root coverage but to increase the keratinized tissue and to maintain remaining teeth stable. Prior to surgery, the patient was asked to rinse with chlorhexidine digluconate solution 0.12% for 1 minute. Under local anesthesia, the recipient site was prepared using horizontal incisions at the CEJ of teeth #42,41 and 31 followed by a de-epithelialization apically (Fig. 6). A FGG was obtained from an edentulous palatal area #14-16 followed by three interrupted sutures (Fig. 7). The FGG was inserted on the de-epithelialized recipient bed and stabilized with one deep layer of interrupted sutures to secure the graft on the bed and one more superficial layer of criss-cross and sling sutures to prevent it from moving (Figs. 8 & 9).

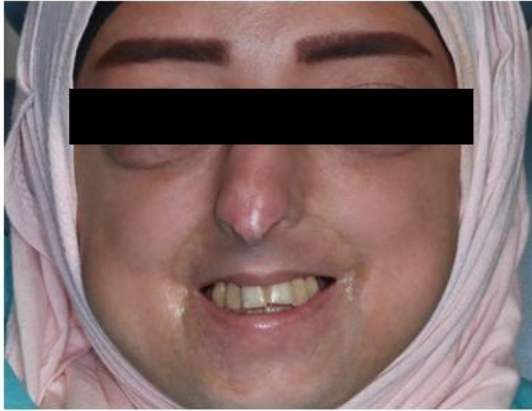

Fig. 1. Skin involvement with a mask-like face appearance, deep wrinkles, and a sharp nose

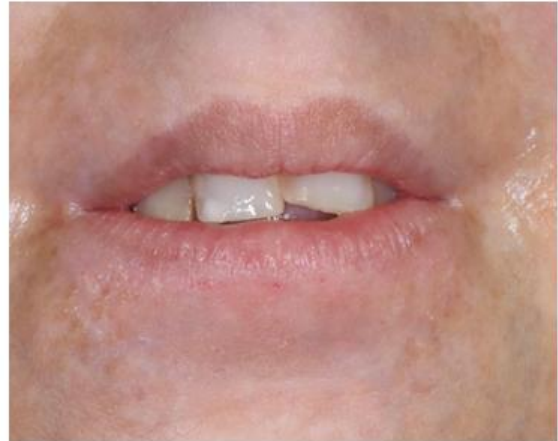

Fig. 2. Oral examination revealing microstomia

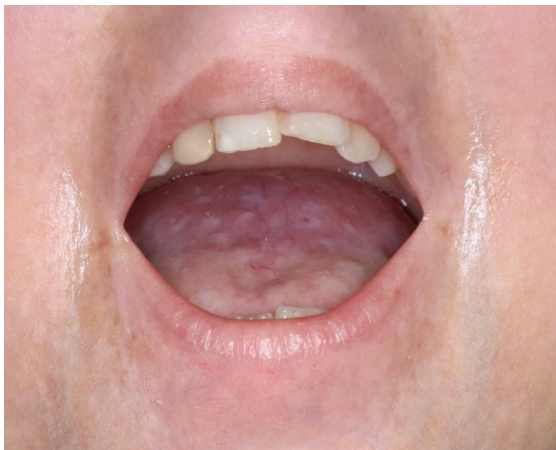

Fig. 3. Mouth opening revealing microstomia

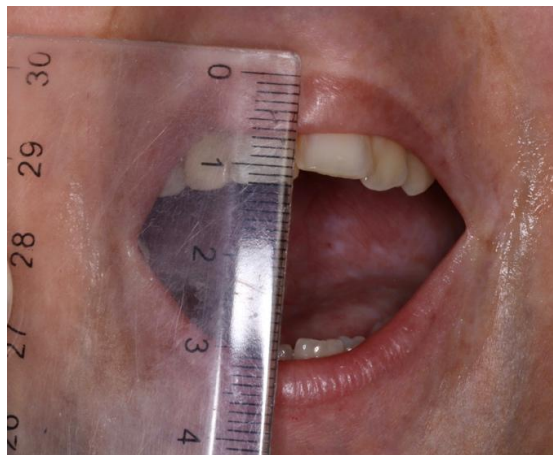

Fig. 4. Limited mouth opening of 35 mm

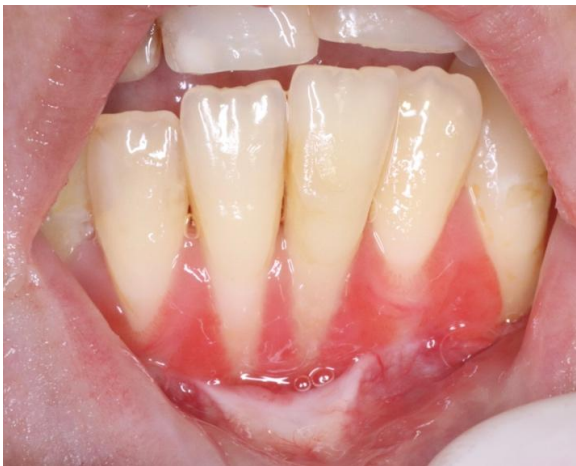

Fig. 5. RT2 recessions on teeth #42, 41 and 31

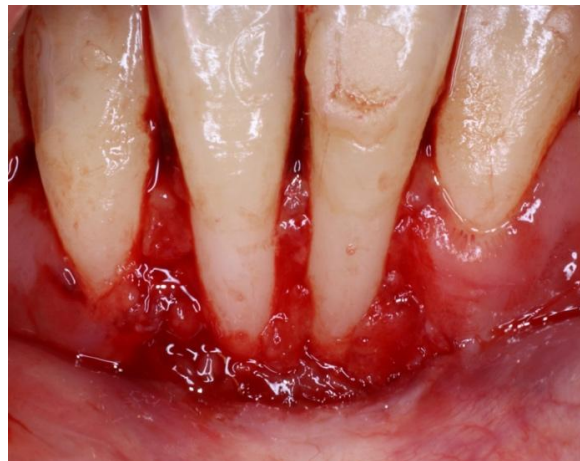

Fig. 6. Flap preparation with horizontal incisions and a de-epithelialization apically

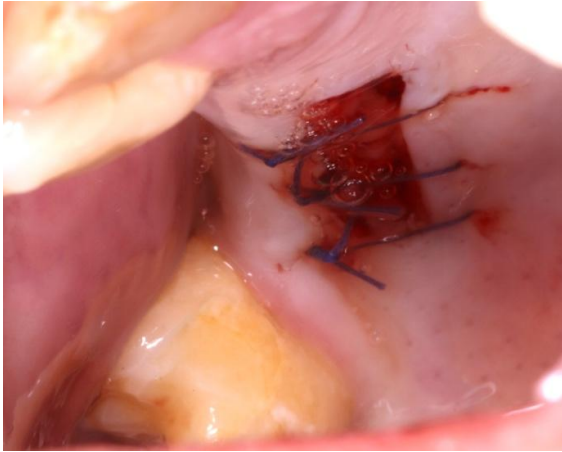


Fig. 7. Palatal site after the FGG harvesting

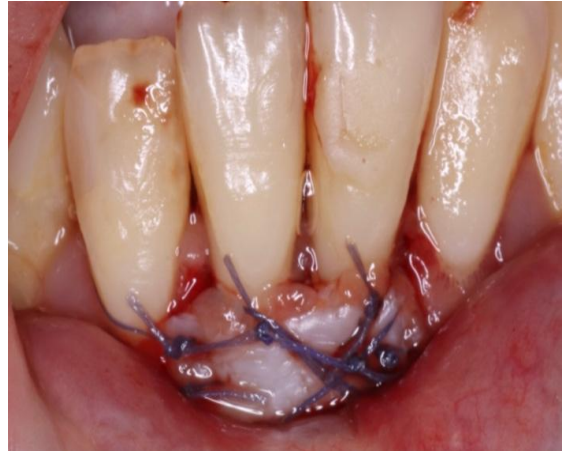

Fig. 8. Frontal view of the sutured FG

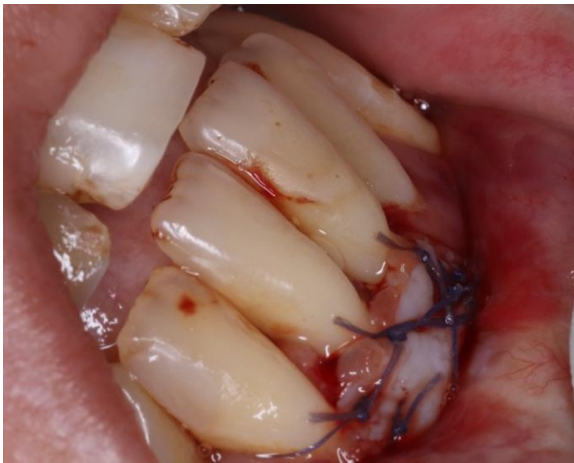

Fig. 9. Lateral view of the sutured FG

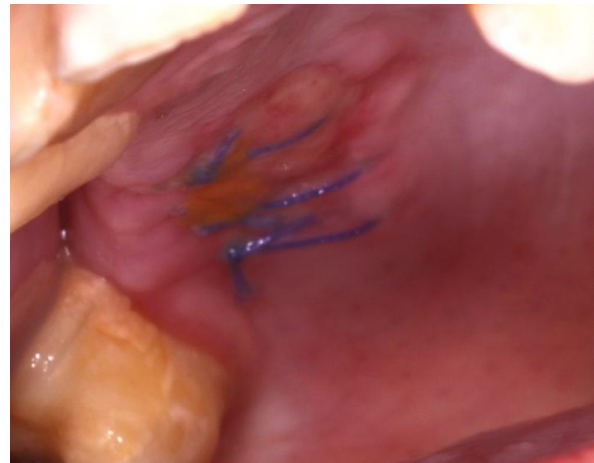

Fig. 10. Palatal site healing after 1 week

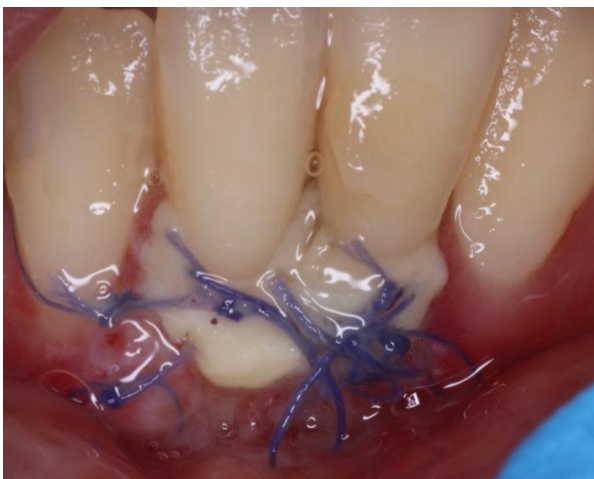

Fig. 11. Graft site healing after 1 week

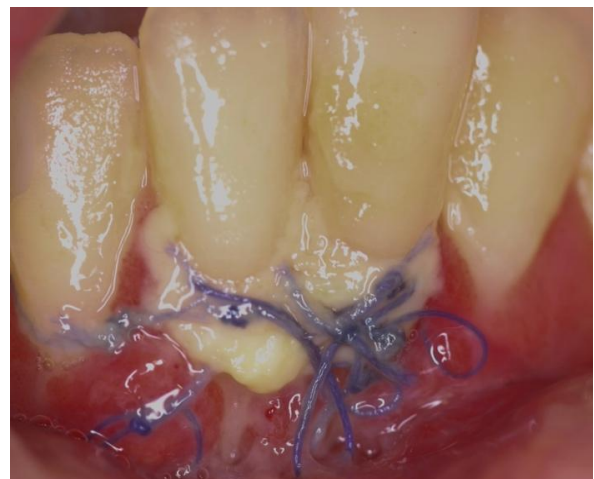

Fig. 12. Graft site healing after 2 weeks

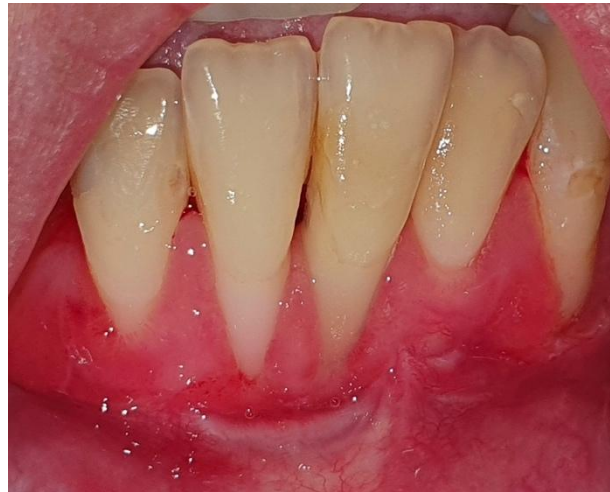

Fig. 13. Healing after 12 weeks

The patient was prescribed analgesics in case of pain and a chlorhexidine digluconate solution 0.12% mouthwash for 14 days. The patient was seen at 1, 2, 4, 6 and 12 weeks. Suture removal was completed after 6 weeks of healing to allow adequate connective tissue maturation and stability, especially in a scleroderma case, and a supragingival scaling with ultrasound was performed to control the plaque accumulation.

6. CLINICAL OUTCOMES

Healing was accompanied by slight inflammation at 1,2 and 3 weeks. Sutures were not removed due to the delayed healing and collagen formation in scleroderma patients. The patient didn't complain from any pain and the donor site was healed completely at 4 weeks.

After 12 weeks, an examination of the recipient site showed no root coverage but the formation of a firm band of keratinized tissue of 1mm of height with a significant decrease of teeth mobility.

7. CONCLUSION

Combination of the progressive systemic sclerosis and the RT2 recession represented some complicating factors in the treatment of this patient. Teeth that were mobile before the gingival graft operation were at risk of extraction. The main purpose of the treatment was to prolong the lifespan of the remaining dentition. The advantage of this technique in this case was to increase the width of keratinized tissue, preventing teeth extraction and a removable prosthesis placement that could be problematic

due to a decreased salivary flow. Yet, the procedure described in this case report should be applied with caution in a scleroderma patient due to the impaired healing and the weakened autoimmune system.

CONSENT AND ETHICAL APPROVAL

As per university standard guideline, participant consent and ethical approval have been collected and preserved by the authors.

COMPETING INTERESTS

Authors have declared that no competing interests exist.

REFERENCES

1. Careta MF, Romiti R. Localized scleroderma: clinical spectrum and therapeutic update. *An Bras Dermatol*. 2015;90(1):62-73.
2. Crincoli V, Fatone L, Fanelli M, Rotolo RP, Chialà A, Favia G, Lapadula G. Orofacial manifestations and temporomandibular disorders of systemic scleroderma: an observational study. *International Journal of Molecular Sciences*. 2016;17(7):1189.
3. Burchfield C, Vorrasi J. Maxillofacial Implications of Scleroderma and Systemic Sclerosis: A Case Report and Literature Review. *Journal of Oral and Maxillofacial Surgery*. 2019;77(6):1203-8.
4. Jung S, Martin T, Schmittbuhl M, Huck O. The spectrum of orofacial manifestations in systemic sclerosis: a challenging management. *Oral Diseases*. 2017;23(4): 424-39.

5. Puzio A, Przywara-Chowaniec B, Postek-Stefańska L, Mrowka-Kata K, Trzaska K. Systemic sclerosis and its oral health implications. *Advances in Clinical and Experimental Medicine: Official Organ Wroclaw Medical University*. 2019;28(4):547-54.
6. Dixit S, Kalkur C, Sattur AP, Bornstein MM, Melton F. Scleroderma and dentistry: Two case reports. *Journal of medical case reports*. 2016;10(1):1-6.
7. Baron M, Hudson M, Tatibouet S, Steele R, Lo E, Gravel S, Gyger G, Sayegh TE, Pope J, Fontaine A, Masseto A. The Canadian systemic sclerosis oral health study: Orofacial manifestations and oral health-related quality of life in systemic sclerosis compared with the general population. *Rheumatology*. 2014;53(8):1386-94.
8. Said MH, Foletti JM, Graillon N, Guyot L, Chossegros C. Orofacial manifestations of scleroderma. A literature review. *Revue De Stomatologie, De Chirurgie Maxillo-faciale Et De Chirurgie Orale*. 2016;117(5):322-6.
9. Silvestre-Rangil J, Martinez-Herrera M, Silvestre FJ. Dental management of patients with microstomia: a review of the literature and update on the treatment. *J. oral res. (Impresa)*. 2015:340-50.
10. Fischer DJ, Patton LL. Scleroderma: Oral manifestations and treatment challenges. *Special care in Dentistry*. 2000;20(6):240-4.
11. Kobak S, Oksel F, Aksu K, Kabasakal Y. The frequency of sicca symptoms and Sjögren's syndrome in patients with systemic sclerosis. *International Journal of Rheumatic Diseases*. 2013 Feb;16(1):88-92.
12. Albilal JB, Lam DK, Blanas N, Clokie CM, Sándor GK. Small mouths... Big problems? A review of scleroderma and its oral health implications. *Journal of the Canadian Dental Association*. 2007;73(9).
13. Dagenais M, MacDonald D, Baron M, Hudson M, Tatibouet S, Steele R, Gravel S, Mohit S, El Sayegh T, Pope J, Fontaine A. The Canadian systemic sclerosis oral health study IV: oral radiographic manifestations in systemic sclerosis compared with the general population. *Oral Surgery, Oral Medicine, Oral Pathology and Oral Radiology*. 2015;120(2):104-11.
14. Yalcin ED, Avcu N, Uysal S, Arslan U. Evaluation of radiomorphometric indices and bone findings on panoramic images in patients with scleroderma. *Oral Surgery, Oral Medicine, Oral Pathology and Oral Radiology*. 2019;127(1):e23-30.
15. Ferreli C, Gasparini G, Parodi A, et al. Cutaneous manifestations of scleroderma and scleroderma-like disorders: A Comprehensive Review. *Clinic Rev Allerg Immunol*. 2017;53:306–336 Available:https://doi.org/10.1007/s12016-017-8625-4.
16. Auluck A, Pai KM, Shetty C, Shenoi SD. Mandibular resorption in progressive systemic sclerosis: a report of three cases. *Dentomaxillofacial Radiology*. 2005;34(6):384-6.
17. de Figueiredo MA, de Figueiredo JA, Porter S. Root resorption associated with mandibular bone erosion in a patient with scleroderma. *Journal of Endodontics*. 2008;34(1):102-3.
18. Jung S, Minoux M, Manière MC, Martin T, Schmittbuhl M. Previously undescribed pulpal and periodontal ligament calcifications in systemic sclerosis: a case report. *Oral Surgery, Oral Medicine, Oral Pathology and Oral Radiology*. 2013;115(4):e47-51.
19. Gomes da Silva GS, Maymone de Melo ML, Leão JC, Carvalho AT, Porter S, Duarte AL, Dantas AT, Gueiros LA. Oral features of systemic sclerosis: A case-control study. *Oral Diseases*. 2019;25(8):1995-2002.
20. Dumoitier N, Lofek S, Mouthon L. Pathophysiology of systemic sclerosis: state of the art in 2014. *La Presse Médicale*. 2014;43(10):e267-78.
21. Bhattacharyya S, Wei J, Varga J. Understanding fibrosis in systemic sclerosis: shifting paradigms, emerging opportunities. *Nature Reviews Rheumatology*. 2012;8(1):42.
22. Krieg T, Abraham D, Lafyatis R. Fibrosis in connective tissue disease: the role of the myofibroblast and fibroblast-epithelial cell interactions. *Arthritis Research & Therapy*. 2007;9(2):1-7.
23. Veale BJ, Jablonski RY, Frech TM, Pauling JD. Orofacial manifestations of systemic sclerosis. *British Dental Journal*. 2016;221(6):305-10.
24. Gupta RA, Fiorentino D. Localized scleroderma and systemic sclerosis: is

- there a connection? Best Pract Res Clin Rheumatol. 2007;21(6):1025-36. DOI: 10.1016/j.berh.2007.09.003. PMID: 18068859.
25. Herrick AL. Vascular function in systemic sclerosis. *Current Opinion in Rheumatology*. 2000;12(6):527-33.
 26. Kuwana M, Okazaki Y. Brief report: Impaired in vivo neovascularization capacity of endothelial progenitor cells in patients with systemic sclerosis. *Arthritis & Rheumatology*. 2014;66(5):1300-5.
 27. Papa ND, Quirici N, Soligo D, Scavullo C, Cortiana M, Borsotti C, Maglione W, Comina DP, Vitali C, Fraticelli P, Gabrielli A. Bone marrow endothelial progenitors are defective in systemic sclerosis. *Arthritis & Rheumatism: Official Journal of the American College of Rheumatology*. 2006;54(8):2605-15.
 28. Zhang S, Zhu J, Zhu Y, Zhang X, Wu R, Li S, Su Y. Oral manifestations of patients with systemic sclerosis: A meta-analysis for case-controlled studies. *BMC Oral Health*. 2021;21(1):1-0.
 29. Baron M, Hudson M, Tatibouet S, Steele R, Lo E, Gravel S, Gyger G, Sayegh TE, Pope J, Fontaine A, Masseto A. The Canadian systemic sclerosis oral health study: Orofacial manifestations and oral health-related quality of life in systemic sclerosis compared with the general population. *Rheumatology*. 2014;53(8):1386-94.
 30. Wood RE, Lee P. Analysis of the oral manifestations of systemic sclerosis (scleroderma). *Oral Surgery, Oral Medicine, Oral Pathology*. 1988;65(2):172-8.
 31. Leung WK, Chu CH, Mok MY, Yeung KS, Ng SK. Periodontal status of adults with systemic sclerosis: Case-control study. *Journal of Periodontology*. 2011;82(8):1140-5.
 32. Scardina GA, Pizzigatti ME, Messina P. Periodontal microcirculatory abnormalities in patients with systemic sclerosis. *Journal of Periodontology*. 2005;76(11):1991-5.
 33. Chakar C, Menassa G, Khayat R. Periodontal Microbiome Part I: A Literature Review. *International Arab Journal of Dentistry (IAJD)*. 2021;12(1):40-7.
 34. Rina Elimelech BD, Yaniv Mayer DM, Yolanda Braun-Moscovici MD, Eli E, Alexandra Balbir-Gurman MD. Periodontal conditions and tumor necrosis factor-alpha level in gingival crevicular fluid of scleroderma patients. *Sat*. 2015;20:21.
 35. Avouac J, Sordet C, Depinay C, Ardizzone M, Vacher-Lavenu MC, Sibilia J, Kahan A, Allanore Y. Systemic sclerosis-associated Sjögren's syndrome and relationship to the limited cutaneous subtype: Results of a prospective study of sicca syndrome in 133 consecutive patients. *Arthritis & Rheumatism: Official Journal of the American College of Rheumatology*. 2006;54(7):2243-9.
 36. Cairo F, Nieri M, Cincinelli S, Mervelt J, Pagliaro U. The interproximal clinical attachment level to classify gingival recessions and predict root coverage outcomes: an explorative and reliability study. *Journal of Clinical Periodontology*. 2011;38(7):661-6.

© 2022 Semaan et al.; This is an Open Access article distributed under the terms of the Creative Commons Attribution License (<http://creativecommons.org/licenses/by/4.0>), which permits unrestricted use, distribution, and reproduction in any medium, provided the original work is properly cited.

Peer-review history:
The peer review history for this paper can be accessed here:
<https://www.sdiarticle5.com/review-history/86007>