



Possible Ameliorative and Preventive Effect of Leaf Extract of *Andrographis paniculata* on Atherosclerosis: An Experience with Isoproterenol Induced Wistar Rats

E. I. Onwubuya^a, A. A. Oladejo^{b*}, O. A. Kalu^a
and I. K. Ndubueze^b

^a Department of Medicine, Nnamdi Azikiwe Teaching Hospital, Nnewi, Nnamdi Azikiwe University, Anambra State, Nigeria.

^b Department of Applied Biochemistry, Faculty of Biosciences, Nnamdi Azikiwe University, Awka, Anambra State, Nigeria.

Authors' contributions

This work was carried out in collaboration among all authors. All authors read and approved the final manuscript.

Article Information

DOI: 10.9734/JOCAMR/2023/v23i1467

Open Peer Review History:

This journal follows the Advanced Open Peer Review policy. Identity of the Reviewers, Editor(s) and additional Reviewers, peer review comments, different versions of the manuscript, comments of the editors, etc are available here: <https://www.sdiarticle5.com/review-history/101059>

Original Research Article

Received: 20/04/2023

Accepted: 23/06/2023

Published: 05/07/2023

ABSTRACT

Atherosclerosis has been regarded as one of the leading causes of death in modern-day man worldwide. The use of medicinal plants especially *Andrographis paniculata* in the treatment of chronic diseases, particularly atherosclerotic disorder is becoming popular. This study aimed to evaluate the possible ameliorative and preventive effect of leaf extract of *Andrographis paniculata*

*Corresponding author: E-mail: aa.oladejo@unizik.edu.ng, adebayoo997@gmail.com;

on atherosclerosis in isoproterenol-induced Wistar rats. Thirty animals were randomly divided into five groups (A-E) of six animals per group, per cage. Groups A, B and C served as the treatment groups and were orally pre-treated with 100, 200 and 400 mg/kg body weight extract of *A. paniculata* for fourteen days, group D served as the positive control group and was administered 10 mg atorvastatin while group E served as the negative control and was administered distilled water. On the fifteenth and sixteenth day, 150 mg/kg isoproterenol was administered intraperitoneal at 24 h intervals to all the animals and were subsequently sacrificed. The sera obtained were used for a bioassay study. Analysis of serum total cholesterol, triglycerides, low density lipoprotein (LDL) and high density lipoprotein (HDL) were carried out using standard methods. The result obtained revealed a significant decrease ($p>0.05$) in the serum total cholesterol, triglycerides and LDL in the extract treated groups in a dose dependent manner when compared with the untreated control while there was a significant increase in the serum HDL level of extract treated group compared to the untreated control; thereby supporting the protective effect of *A. paniculata* against atherosclerotic disorder.

Keywords: Atherosclerosis; *Andrographis paniculata*; chronic diseases; isoproterenol.

1. INTRODUCTION

Atherosclerosis and its associated complications are the principal cause of cardiovascular morbidity and mortality worldwide [1]. "Increased levels of plasma concentration of lipids especially low density lipoprotein cholesterol (LDL-C) and triglyceride along with free radicals are recognized as the leading cause in the development of atherosclerosis and other cardiovascular diseases" [2]. Atherosclerosis is characterized by localized thickening and hardening of the artery walls, usually caused by continuous and progressive deposition of lipid substances and other waste products, thereby causing localized narrowing of the vessels and subsequently blocking blood flow; courtesy of years of mismatched lifestyle [3]. According to the National Cholesterol Education Program (NCEP), three out of every five adults live with at least one or more metabolic diseases, especially atherosclerosis [4].

Although several drugs are being used in the treatment of atherosclerotic diseases, treatment with statins have been known to cause untold side effects which are known to be unbearable to some patients and subsequently may discontinue their use, thereby encouraging the progression of atherosclerosis. In addition, their provocative cost may indirectly discourage the patient from the particular choice [5,6].

Addressing the metabolic diseases in the populace will be a way to resolve chronic cardiovascular conditions. Thus, the use of plants, abundant in our environment to combat atherosclerosis is a strategy that should provide

an alternative approach to fight this common foe. Hence, investigating the ameliorative effect of leaf extract of *Andrographis paniculata* on atherosclerosis in isoproterenol-induced Wistar rats remains vital and imperative.

"*Andrographis paniculata* (Nees), commonly known as the king of bitters is one of the important herbal medicines that have been effectively used in traditional Asian medicines for centuries" [7]. In Nigeria, dried powder of the aerial part of *A. paniculata* (leaves and stems) is widely used as an alternative medicine [8]. It has been reported to possess anti-inflammatory [9], anticancer [10], anti-hyperglycemic [11], cardioprotective [8], as well as immunomodulatory [12] effects in both rats and mice. Although the pharmacological activities of *A. paniculata* have been well explored and documented, there is a dearth of reports on its ameliorative effects on atherosclerosis especially in isoproterenol-induced Wistar rats. This study therefore aims at exploring the ameliorative and preventive effect of leaf extract of *Andrographis paniculata* on atherosclerosis in isoproterenol-induced Wistar rats.

2. MATERIALS AND METHODS

2.1 Sample Collection and Preparation

Fresh green leaves of *Andrographis paniculata* were collected from farmland in Owerri, Imo-State, Nigeria. Identification and authentication of the plant was carried out at the Department of Botany, Nnamdi Azikiwe University, Awka and a voucher specimen was deposited at the herbarium of the Department for future

references. The plant material was shredded with a knife and air-dried under shade for 21 days in order to get rid of the moisture as well as preserve the bioactive compounds. The dried leaf was pulverized using a laboratory blender and the fine powders obtained was weighed and stored in an air-tight container at room temperature for further use.

2.2 Extraction of Plant Materials

The weighed powdered sample (245.79 g) was then used for the extraction with a solvent combination of ethanol and water (7:3) (2500 ml) for 72 hr via maceration in an unheated medium. The mixture was decanted and filtered using sterile Whatman paper No. 1. The filtrate was there after evaporated to dryness with the aid of a rotary evaporator set at 50 °C to obtain crude ethanol extract which was carefully preserved for further analysis. The method of Nkafamiya et al [13] was used to calculate the yield (12.36g) of the crude extract using the formula below:

$$\text{Percentage yield} = \frac{\text{Mass of crude extract (g)}}{\text{Mass of powdered sample (g)}} \times 100$$

2.3 Animal Studies

2.3.1 Procurement of study animals

Wistar albino rats (30) weighing approximately 180 g were purchased from Chris Farm Ltd Mgbakwu, Awka, Anambra State and were brought to the animal house of the Department of Applied Biochemistry, Nnamdi Azikiwe University, Awka. The rats were kept in standard cages with saw dust as bedding, and at standard room temperature as well as standard housing conditions of 12:12 light: dark cycles and fed with standard rat pellets and water *ad libitum*. The animals were allowed to acclimatize to the new environment for seven days.

2.3.2 Dose preparation and treatment

The hydro-ethanolic leaf extract of *Andrographis paniculata* was prepared with distilled water in three divided doses (100, 200, and 400) mg / kg, Atorvastatin (10 mg/kg) was used as a reference drug (atorvastatin is a statin drug used to lower the level of cholesterol in the blood) and distilled water was used as a vehicle for the untreated

group. The animals were administered the extract and drug orally for fourteen consecutive days concurrently prior to induction with water *per os* and feed *ad libitum*.

2.3.3 Experimental design

The animals were randomly grouped into five, with six animals in each group, and the treatment was as follows: Groups A, B and C animals were designated as *A. paniculata* treatment group and were pre-treated with the ethanol leaf extract at 100 mg/kg, 200 mg/kg and 400 mg/kg, respectively, for 14 days and thereafter 0.2 ml isoproterenol (ISO) at 150 mg/kg was injected intraperitoneally at an interval of 24 h on the 15th and 16th day. Group D animals were designated as isoproterenol control and were administered 0.2 ml of 10 mg atorvastatin for 14 days and thereafter 0.2 ml isoproterenol (ISO) at 150 mg/kg was injected intraperitoneally at an interval of 24 h on the 15th and 16th day while group E animals (designated as vehicle control group) were administered 0.2 ml distilled water for 14 days; and on the 15th and 16th day, 0.2 ml isoproterenol (ISO) at 150 mg/kg was injected intraperitoneally at an interval of 24 h.

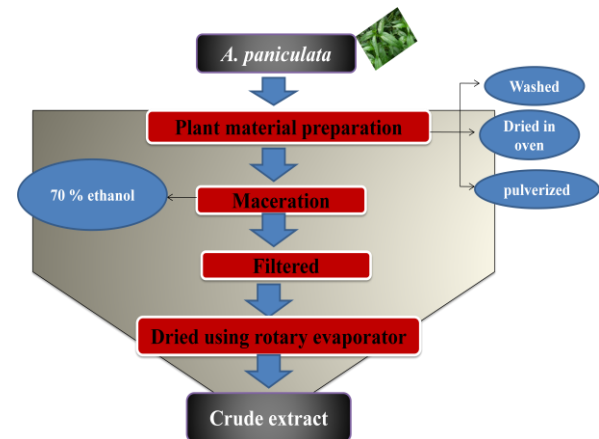


Fig. 1. Procedure for the extraction of *A. paniculata* crude extract

2.3.4 Collection of blood sample

At the end of the experimental period, the animals were anesthetized with chloroform vapor and sacrificed. A 5 ml sterile syringe with needle was used for blood collection through cardiac puncture and the sera obtained were used for bioassay studies.

2.3.5 Biochemical assays

Assay of low density lipoprotein cholesterol (LDL-C), high density lipoprotein cholesterol (HDL-C), triglyceride and total cholesterol levels were carried out with standard assay kit sourced from Randox laboratories Ltd, United Kingdom with maximum adherence to the manufacturer's instruction.

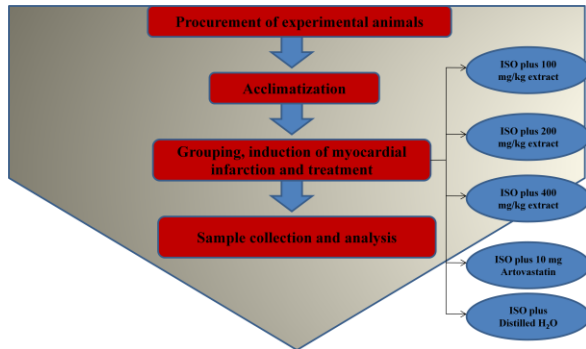


Fig. 2. Experimental design of the study

2.4 Data Analysis

The results obtained in this research were expressed as Mean \pm S.D of triplicate determinations within each group. One-way analysis of variance (ANOVA) was carried out on the results and significance was accepted at $p < 0.05$. GraphPad Prism5 Program (GraphPad Software, San Diego, CA, USA) was used for the graphical analyses of the results obtained.

3. RESULTS

The result of this study is presented in Figs. 3 to 6. The result showed a significant decrease ($P > 0.05$) in the serum cholesterol, triglycerides and LDL in the extract treated group in a dose dependent manner compared to the untreated control (Figs. 3, 4 and 5) while the serum HDL was significantly increased in the extract treated groups when compared to the untreated control (Fig. 6).

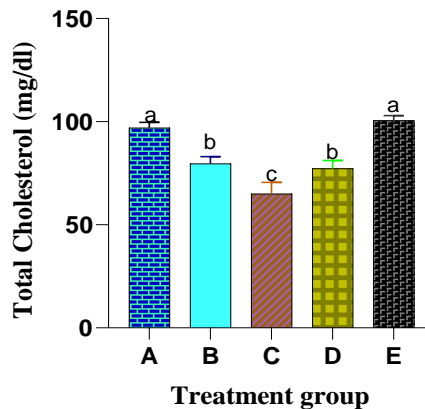


Fig. 3. Effect of *A. paniculata* leaf extract on the total cholesterol levels in isoproterenol-induced wistar rats

Columns with different alphabets are significantly different at $P < 0.05$

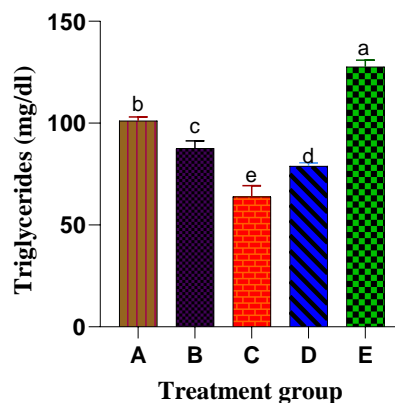


Fig. 4. Effect of *A. paniculata* leaf extract on the triglyceride levels in isoproterenol-induced wistar rats

Columns with different alphabets are significantly different at $P < 0.05$

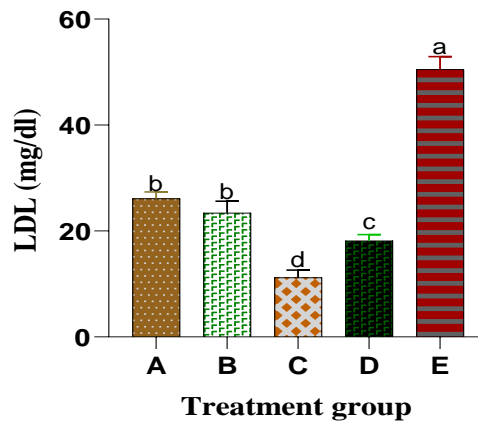


Fig. 5. Effect of *A. paniculata* leaf extract on the level of Low density lipoprotein cholesterol (LDL-C) in isoproterenol-induced wistar rats

Columns with different alphabets are significantly different at $P < 0.05$

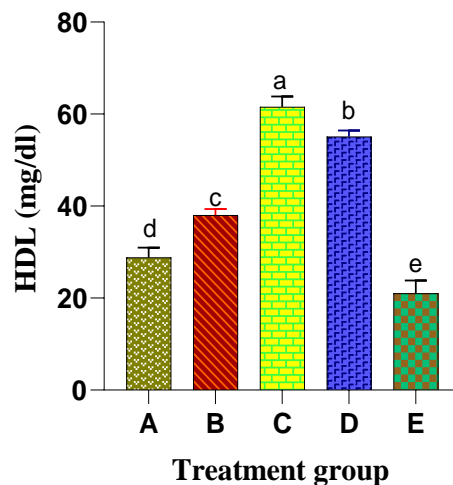


Fig. 6. Effect of *A. paniculata* leaf extract on the level of High density lipoprotein cholesterol (HDL-C) in isoproterenol-induced wistar rats

Columns with different alphabets are significantly different at $P < 0.05$

4. DISCUSSION

Over the years, medicinal plants have contributed immensely to the prevention and treatment of chronic diseases including atherosclerosis. Plants are known to contain bioactive compounds which help them to perform these functions [6]. Assessing the impacts of plants' administration on atherosclerotic disorder remains crucial in evaluating their therapeutic index against cardiovascular diseases. Thus, the possible ameliorative effects of leaf extract of *Andrographis paniculata* on atherosclerosis were carried out.

Overall, the results of this finding showed that extract of *A. paniculata* could help to ameliorate cardiovascular disorders especially

atherosclerosis. Fig. 3 showed the effect of *Andrographis paniculata* leaf extract on the total cholesterol level in isoproterenol induced Wistar rats. The results showed that the extract of *A. paniculata* significantly reduces serum total cholesterol levels in a dose dependent manner (400 mg/kg < 200 mg/kg < 100 mg/kg). This is consistent with the findings of Adiguna *et al* [14]. The increase in serum total cholesterol level in the untreated control group as observed in this study (Fig. 3) could be as a result of indirect stimulation of HMG CoA (3-hydroxy-3-methylglutaryl-Coenzyme A) reductase following induction of isoproterenol. Since lowering serum total cholesterol is the primary objective of any treatment in a cardiovascular disease state, the possible total cholesterol lowering effects of *A. paniculata* extract as observed in this study could

be attributed to decreased activity of hepatic HMG CoA reductase and/or stimulation of cholesterol-7-alpha-hydroxylase, which converts cholesterol into bile acids. It could also be due to the presence of saponins, a phytochemical that forms insoluble complexes with cholesterol or their bile salt precursor, thus making them unavailable for absorption. This is consistent with the assertion of Banti and Bajo [15]. Similarly, Onwubuya and Oladejo [8] reported that bioactive compounds in medicinal plants especially *A. paniculata* are responsible for their many pharmacological activities.

Triglycerides are lipid compounds composed of a glycerol esterified to 3-fatty acid chains of varying length and composition. High serum triglyceride levels above the reference range (less than 150 mg/dl) have been known to contribute to the localized hardening or thickening of the artery walls and consequently lead to stroke, heart attack and other cardiovascular diseases. Their progressive increases in the serum have also been attributed to causing acute inflammation of the pancreas [6]. As evident in our study (Fig. 4), induction of isoproterenol significantly increases the serum triglyceride levels in the experimental animals; however, treatment with the plant extract (*A. paniculata*) was able to mitigate this continued increase in a dose-dependent manner (400 mg/kg < 200 mg/kg < 100 mg/kg), thereby exerting protective effect on the cardiomyocytes. An increase in serum triglyceride concentration following the induction of isoproterenol may plausibly be from the inhibition of triglyceride degradation. The extract of *A. paniculata* could have reduced serum triglyceride levels by both activating endothelium bound lipoprotein lipase which hydrolyses the triglyceride into fatty acid and hence decreasing triglyceride levels. Sikarwar and Patil [16] made similar assertions.

Similarly, the administration of *A. paniculata* extract was able to significantly reduce the continued increase in the serum low-density lipoprotein (LDL) of the animals following the induction of isoproterenol (Fig. 5).

LDL which is often referred to as the "bad cholesterol" play a crucial role in the pathogenesis of atherosclerosis. Sufficient evidence from epidemiologic, genetic and clinical intervention studies has indisputably shown that increased serum LDL is the primary cause of atherosclerotic disorder [17]. LDL is known to be responsible for transporting 60-70% of total cholesterol to the body cells. Hence, an increase

in total cholesterol level consequently increases LDL. The increased LDL which was not removed in the process of lipid metabolism is likely to flow into the sub-endothelial space, as well as to undergo oxidation. Since there have been reports that some isoflavones (a type of flavonoid) increase resistance to LDL oxidation [18], it is possible that the presence of this flavonoid in *A. paniculata* is responsible for the clearance of LDL in the extract treated groups [8]. Similarly, Khatana et al, [19] reported that "phenolics may work by increasing LDL receptors densities in the liver binding to apo-lipoprotein B thereby making liver cells more efficient to remove LDL from blood".

Fig. 6 presents the serum concentration of high-density lipoprotein (HDL) in isoproterenol induced animals. As evident in the result, there was a significant increase in the serum concentration of HDL in a dose-dependent manner (400 mg/kg > 200 mg/kg > 100 mg/kg) compared to the untreated group. It has been established that HDL acts as a cholesterol scavenger, and thereby mops up excess cholesterol and cholesterol esters from the blood and peripheral tissues, breaking them down to bile acids; and subsequently inhibiting the formation of atherosclerotic plaque in the aorta [20]. Hence, they are referred to as 'protective cholesterol'. This could possibly be due to the increasing activity of lecithin-cholesterol acyl transferase (LCAT), an enzyme responsible for incorporating free cholesterol into HDL [21], thereby promoting reverse cholesterol transport and competitively inhibiting the uptake of LDL, thus protecting the walls of the artery from clogging and subsequently preventing atherosclerosis.

5. CONCLUSION

The findings of this investigation revealed that the ethanol leaf extract of *A. paniculata* has a protective effect on atherosclerosis occasioned by the induction of isoproterenol and therefore could serve as an affordable and accessible alternative for the prevention of cardiovascular related disorders, particularly atherosclerosis.

CONSENT

It is not applicable.

ETHICAL APPROVAL

All the experimental procedures and protocols used in this study were in accordance with the

guidelines principles of Laboratory Animal Care of the Nnamdi Azikiwe University-Animal Research Ethics Committee NAU/AREC/2021/00028.

COMPETING INTERESTS

Authors have declared that no competing interests exist.

REFERENCES

1. Meng H, Ruan J, Yan Z, Chen Y, Liu J, Li X, Meng F. New progress in early diagnosis of atherosclerosis. *International Journal of Molecular Sciences*. 2022;23:8939.
2. Summerhill VI, Grechko AV, Yet SF, Sobenin IA, Orekhov AN. The atherogenic role of circulating modified lipids in Atherosclerosis. *International Journal of Molecular Sciences*. 2019;20:3561.
3. Onwubuya EI, Ahaneku GI, Analike RA, Agbo JS, Ahaneku JE, Oladejo AA. Cardiovascular risk factor profile among public servants in a developing country: A look at the prevalence of metabolic syndrome in a Nigerian University Community. *Asian Journal of Research in Cardiovascular Diseases*. 2021;3(2):32-46.
4. National Cholesterol Education Program (NCEP). National Heart, Lung, and Blood Institute National Institutes of Health, NIH Publication No. 01-3670; 2002.
5. Karimi A, Majlesi M, Rafieian-Kopaei M. Herbal versus synthetic drugs; beliefs and facts. *Journal of Nephro pharmacology*, 2015;4(1):27-30.
6. Oladejo AA, Onwubuya EI, Ogbunugafor HA, Okafor CS, Ogbodo CU. Inhibitory effects of *Bryophyllum pinnatum* leaf extract on inflammatory biomarkers. *Journal of Advances in Medical and Pharmaceutical Sciences*. 2021;23(2):7-13.
7. Akbar S. *Andrographis paniculata*: A review of pharmacological activities and clinical effects. *Alternative Medicine Review*. 2011;16:66-77.
8. Onwubuya EI, Oladejo AA. Cardio-protective effect of the leaf extract of *Andrographis paniculata* in Isoproterenol-induced myocardial infarction. *Cardiology and Angiology: An International Journal*. 2022;11(4):467-478.
9. Li X, Yuan W, Wu J, Zhen J, Sun Q, Yu M. Andrographolide, a natural anti-inflammatory agent: An Update. *Frontiers in Pharmacology*. 2022;13:920435.
10. Malik Z, Parveen B, Zahiruddin S, Aasif-Khan M, Khan A, Massey S, Ahmad S, Husain SA. Anticancer potential of andrographolide from *Andrographis paniculata* and its mechanisms of action. *Journal of Ethnopharmacology*. 2021;272:113936.
11. Suemanotham N, Phochantachinda S, Chatchaisak D, Sakcamduang W, Chansawhang A, Pitchakarn, P, Chantong B. Antidiabetic effects of *Andrographis paniculata* supplementation on biochemical parameters, inflammatory responses, and oxidative stress in canine diabetes. *Frontiers in Pharmacology*. 2023;14:1077228.
12. Rajanna M, Bharathi B, Shivakumar BR, Deepak M, Prashanth D, Prabakaran D, Vijayabhaskar T, Arun B. Immunomodulatory effects of *Andrographis paniculata* extract in healthy adults: An open-label study. *Journal of Ayurveda and Integrative Medicine*. 2021;12:529e534.
13. Nkafamiya II, Maina HM, Osemeahon SA, Modibbo UU. Percentage oil yield and physiochemical properties of different groundnut species (*Arachis hypogaea*). *African Journal of Food Science*. 2010; 4(7):418-421.
14. Adiguna SP, Panggabean JA, Swasono RT, Rahmawati SI, Izzati F, Bayu A, Putra MY, Formisano C, Giuseppina C. Evaluations of Andrographolide-rich fractions of *Andrographis paniculata* with Enhanced Potential Antioxidant, Anticancer, Antihypertensive, and Anti-Inflammatory Activities. *Plants*. 2023; 12:1220.
15. Banti M, Bajo W. Review on nutritional importance and anti-nutritional factors of legumes. *International Journal of Nutrition and Food Sciences*. 2020;9(6):138.
16. Sikarwar MS, Patil MB. Antihyperlipidemic effect of ethanolic extract of *Hibiscus rosa sinensis* Flowers in Hyperlipidemic Rats. *RGUHS Journal of Pharmaceutical Sciences*. 2011;1(2):117-122.
17. Ference BA, Ginsberg HN, Graham I, Ray KK, Packard CJ, Bruckert E, Hegele RA, Krauss RM, Raal FJ, Schunkert H, Watts GF, Borén J, Fazio S, Horton JD, Masana L, Nicholls SJ, Nordestgaard BG, van de

- Sluis B, Taskinen MR, Tokgözoğlu L, Landmesser U, Laufs U, Wiklund O, Stock JK, Chapman MJ, Catapano AL. Low-density lipoproteins cause atherosclerotic cardiovascular disease: Evidence from genetic, epidemiologic and clinical studies. *European Heart Journal*. 2017;38(32):2459-2472.
18. Beckmann N, Cannaert C, Babib AL, Bie FX, Zurbrugg S, Kneuer R, Dousset V. *In vivo* visualization of macrophage infiltration and activity in inflammation using magnetic resonance imaging. *Nanomedicine and Nanobiotechnology*. 2009;1(3):272-298.
19. Khatana C, Saini NK, Chakrabarti S, Saini V, Sharma A, Saini RV, Saini AK. Mechanistic insights into the oxidized Low-density lipoprotein-induced atherosclerosis. *Hindawi Oxidative Medicine and Cellular Longevity*. 2020; 2(2):1-14
20. Yongzheng L, Xiaolin C, Li Z, Xu W, Yanyan X, Zhen Q, Gangqiong L, Qiguang W, Kang T, Khoon SL, Chris JC, Jinying Z, Junnan T. The functional role of lipoproteins in atherosclerosis: Novel directions for diagnosis and targeting therapy. *Aging and disease*. 2022; 13(2):491-520.
21. Gao H, Wu J, Sun Z, Zhang F, Shi T, Lu K, Qian D, Yin Z, Zhao Y, Qin J, Xue B. Influence of lecithin cholesterol acyltransferase alteration during different pathophysiologic conditions: A 45 years bibliometrics analysis. *Frontiers in Pharmacology*. 2022;13:1062249.

© 2023 Onwubuya et al.; This is an Open Access article distributed under the terms of the Creative Commons Attribution License (<http://creativecommons.org/licenses/by/4.0>), which permits unrestricted use, distribution, and reproduction in any medium, provided the original work is properly cited.

Peer-review history:
The peer review history for this paper can be accessed here:
<https://www.sdiarticle5.com/review-history/101059>