



Study of Association of AgNOR vs Ki-67 in Thyroid Lesions

C. Hamsini¹, V. Ramamoorthy¹ and S. Mary Lilly^{1*}

¹*Department of Pathology, Sree Balaji Medical College & Hospital Affiliated to Bharath Institute of Higher Education and Research, Chennai, Tamil Nadu, India.*

Authors' contributions

This work was carried out in collaboration among all authors. All authors read and approved the final manuscript.

Article Information

DOI: 10.9734/JPRI/2021/v33i22A31384

Editor(s):

(1) Dr. Ana Cláudia Coelho, University of Trás-os-Montes and Alto Douro, Portugal.

Reviewers:

(1) Mukul Patar, Gauhati Medical College and Hospital, India.

(2) Xiaohong Fu, Naval Medical University, China.

Complete Peer review History: <http://www.sdiarticle4.com/review-history/66762>

Original Research Article

Received 27 January 2021

Accepted 03 April 2021

Published 09 April 2021

ABSTRACT

The thyroid is an important endocrine gland, which plays a major role in the functions of almost all normal metabolic processes. In present study, by focusing the sections at very high magnification (100x, oil immersion level) AgNOR dots are visible as black dots inside the nucleus. Our studies which have reported that thyroid lesions with less AgNOR counts are more likely to regress as compared to those with high AgNOR counts and that showed its prognostic significance. Thus, the AgNOR technique can be useful as a supportive tool in both the prognosis and therapeutic value in thyroid lesions most commonly in malignant lesions that are stained by routinely performed haematoxylin and eosin. The Present Study is aim to find out the prevalence of thyroid lesions in the patients and also to Study and find out the different types of neoplastic and non- neoplastic thyroid lesions and their relation with AgNOR and Ki-67 proliferation makers. The Present Study focuses on to evaluate the association of AgNOR vs Ki-67 in the prognostic value of thyroid lesions.

Keywords: *Thyroid lesions; prognostic; Ki-67; AgNOR; lymph node and follicular carcinoma.*

*Corresponding author: E-mail: MaryLilly.s@bharathuniv.ac.in;

1. INTRODUCTION

Thyroid nodules which are more commonly encountered during routine medical care and their prevalence increases with age, with the average of 4–7% in adult population [1]. Thyroid carcinoma, which accounts for approximately 1% of all the cancers, is the most common malignancy among all the endocrine organs [2]. Approximately 5% occur as thyroid cancers among all the thyroid nodules, irrespective of their size [3]. Based on histopathology, thyroid carcinomas are classified into follicular thyroid cancer (FTC), papillary thyroid cancer (PTC), medullary thyroid cancer (MTC), anaplastic thyroid cancer and poorly differentiated thyroid cancer [4]. It has been documented that 90 people were diagnosed with thyroid cancer out of 1,00,000 people and among these patients, 6.8 people were died in china. It has also been reported that 1,980 people died of the disease in 2016 and it has been estimated that there will be 64,300 new patients of thyroid cancer in USA [4]. The diagnosis of thyroid cancer is often based on magnetic resonance imaging, ultrasound, computed tomography, fine needle aspiration and radionuclide imaging. Although various methods are well applied in clinics, patients often have poor outcome. Reports have shown that the patients' age when being diagnosed, sex, tumour size, lymph node, distant metastases and pathologic differentiation of the cancer are the risk factors of prognosis in thyroid cancer.

Of all thyroid cancers, PTC is found as the most common form of thyroid cancer. Though it is found difficult to differentiate PTC from benign papillary hyperplasia of the thyroid gland based on their morphology, it is important to differentiate benign ones from malignant ones for early treatment and better patient management. Due to overlapping of morphological features, distinction of certain neoplasms was found difficult. Though characteristic nuclear changes were found important for the diagnosis of papillary thyroid carcinoma (PTC), but when these features are present focally along with papillary structures then they cause diagnostic dilemma in distinguishing it from other thyroid lesions [5].

Histomorphologic examination of slides which are routinely stained by Haematoxylin and Eosin (H&E) is used as the standard diagnosis currently. This has been documented in literature that interobserver or intraobserver disagreements in the diagnosis of follicular and papillary thyroid lesions [6]. A large number of molecular alterations in thyroid cancer have been

documented in distinguishing malignant from benign thyroid lesions, in the recent years. Alterations of some proteins have been observed in thyroid cancer, such as, Ki67, CK19, Calcitonin, TG, TTF-1, RET, HBME-1, BRAF, FHL1, galectin-3, Tfr1/CD71 and SERPINA1 [7] and have been translated into clinical practice which were used for the significant improvement in the preoperative diagnosis of thyroid cancer [8]. Among these markers, this has been found that, Ki67 and cytokeratin-19 (CK-19), galectin-3, and TG have been used most frequently in thyroid pathology.

Several newer Immunohistochemistry (IHC) markers have been described and validated for differentiating benign from malignant ones and Follicular Variant of Papillary Carcinoma (FVPTC) from Follicular Carcinoma (FCa) or Follicular Adenoma (FA) [8]. However, none of the studies showed the markers had prognostic value in thyroid cancer. Cell proliferative activity is an important factor in cancer biologic behaviour. Different proliferation markers such as Ki67 [9], proliferating cell nuclear antigen (PCNA) [10] and argyrophilic nucleolar organizer regions (AgNORs) [11] have been examined and observed their importance in thyroid tumours. Even though the diagnostic and prognostic values of Ki-67/MIB-1 in thyroid cancer remain unclear, but it has been observed that Ki-67/MIB-1 has an effect on the clinical progression and prognosis in cancers with the growing evidence [4]. Ki-67, which is considered as a nuclear antigen, is expressed in all the cell nuclei, except those in the G0 phase. MIB-1 acts as a monoclonal antibody and that increases against Ki-67 [4]. In recent years, Ki-67 has been studied in many cancers, including cervical cancer, [12] lung cancer, [13] breast cancer [14] and thyroid cancer [15]. This has been reported that Ki-67 is also found as an important and independent prognostic factor in thyroid cancer patients, in many studies [16-20]

The nucleolar organizer regions (NORs) which are DNA segments, that encode ribosomal RNA [21]. NORs are associated with some nucleolar proteins which are usually called as AgNOR proteins or AgNORs, that are stained black with silver methods [22,23]. It has also been reported that other than Ki-67, AgNORs are also related to the rate of cell proliferative activity [24]. As they also found useful in distinction, so they can be used in distinguishing different lesions [25]. Many studies show a linear correlation between AgNOR and Ki-67 in different malignancies [26,27].

2. MATERIALS AND METHODS

2.1 Sources of Data

This study was carried out in the Department of Pathology, Sree Balaji Medical College & Hospital, Bharath Institute of Higher Education and Research during my study period of 17 months that is between February 2017 to July 2018. A total of 78 specimens of hemi thyroidectomy and total thyroidectomy were received for histopathological examination from Department of Surgery. Out of 78 thyroid specimens, 60 specimens were selected for study by excluding the remaining non-neoplastic lesions of thyroid like Hashimoto's thyroiditis, autoimmune thyroiditis and other thyroiditis to avoid errors of statistical analysis.

2.2 Inclusion Criteria

A total of 60 cases were included in this study and according to WHO guidelines, all these cases were diagnosed. The cases included were: 25 PTC (in which 12 were of classic variant, 7 were of follicular variant, 2 were of solid variant, 4 were of oncocyctic variant), 3 FTC (in which 2 were of oncocyctic variant), 10 benign neoplasms (in which 8 were follicular micro and macroadenoma, 2 were hurthle cell adenoma), 22 nodular goitres (NG).

2.3 Exclusion Criteria

The cases with medullary, anaplastic carcinomas and poorly differentiated carcinoma cases were excluded from the current study as any of these cases were diagnosed in our department in the study period of 17 months and also excluded few non-neoplastic lesions like Hashimoto's thyroiditis, autoimmune thyroiditis and other thyroiditis which were diagnosed in our department to avoid errors of statistical analysis.

2.4 Method of Data Collection

Out of the 78 thyroid specimens which were received for histopathological examination following initial cytological evaluation by fine needle aspiration cytology, 60 gross specimens were taken for study. These biopsy specimens were routinely fixed in 10% formalin and processed in paraffin wax. 5 microns thick Sections were cut and taken for the study and hematoxylin and eosin staining of sections was done. Histopathological examination of these sections were done. Special stain (AgNOR Stain)

and Immunohistochemical study using Ki-67 monoclonal antibody as a proliferation marker was done in 60 cases.

2.5 Staining Procedures

2.5.1 Hematoxylin & Eosin

Section: Paraffin Procedure:

1. Wax removal was done – for 10-15 minutes
2. Xylene 1 and Xylene 2 for 10 minutes each
3. Dipped in acetone – 10 dips each
4. Washed in water for 2 minutes
5. Stained with harris hematoxylin and left for 8-10 minutes
6. Washed in tap water for 2 minutes
7. Dipped in 1% acid alcohol -1 dip
8. Washed under running water for 5-8 minutes
9. Dipped in Eosin -2 dips and washed with tap water
10. Allowed it to dry for 2-3 minutes
11. Mounted with DPX (Distyrene, plasticizer, and xylene)

3. RESULTS

Nucleus: stained blue colour

Connective tissue and cytoplasm stained: pink colour

3.1 AgNOR Staining

AgNOR staining was performed by adopting both previous and also modified procedures. In previous methods counter stain (Neutral red) was used. But in this study, neutral red counter stain was not used.

3.1.1 Preparation of solutions: (as shown in Table:1)

Solution A: This solution was prepared by dissolving 500 mg gelatin powder in 25 ml deionized water at 37 degrees C and then 250 micro L formic acid was added. Continuous shaking for about 10 min at 37 degrees C was sufficient to dissolve the gelatin and a clear solution was obtained.

Solution B: It was prepared with silver nitrate and deionized water.

3.1.2 Working solution

This was prepared by mixing one part by volume of solution A with two parts by volume of

Table 1. Reagents use for the study

Name of reagents	Amounts of reagents	Concentration	Comments
Solution A Gelatin powder	500 mg	2%	
Formic acid	250 micro L		
Deionized water	25 ml		
Solution B : Silver nitrate		50%	
Deionized water	30 g		
	60 ml		
Working solution:			
Solution A	1 part		Make just before use
Solution B	2 parts		
Sodium thiosulphate			
toning solution		10%	

solution B and it was filtered through filter paper into plastic bottle. As it degrades immediately, it was used immediately.

3.2 AgNOR Staining Procedure

The AgNOR technique was adapted from the study as mentioned earlier and also from the study which was described by Crocker and Nar. [28]

- 4 microns thick sections were taken for each case.
- Deparaffinized in xylene.
- Hydrated through decreasing grades of ethanol to double-distilled deionized water.
- The sections were then reacted with freshly prepared silver colloidal solution (that contains one part by volume of 2% gelatin in 1% formic acid and two parts by volume of 50% aqueous silver nitrate solution) in a closed Coplin jar for 35 min at room temperature, ensuring a dark environment throughout the reaction time.
- The silver colloidal solution was washed with double-distilled deionized water. The sections were then treated with 10% sodium thiosulphate for 5 mins.
- And washed in double-distilled deionized water
- Dehydrated through increasing grades of ethanol
- Cleared in xylene, and mounted.

3.3 AgNORs Quantitative Analysis²¹

From the selected areas, an average of 5–10 microscopic fields, were analysed from each case, at magnification 100x (Under oil immersion). 100 nuclei were analysed in each case, whole nuclei were taken as actual lesion.

Each overlapped and fragmented nuclei were counted and taken as 1.

3.4 Ki-67 Immunohistochemistry and Determination of the Labeling Index (LI)

IHC of Ki-67 technique was adopted from Path in Situ IHC Protocol:

1. 3mm sections were cut and taken on charged slides and incubated at 60-70 C for 1 hour.
2. Deparaffinized by 2 changes of xylene 15 minutes each.
3. Hydrated through descending grades of alcohol as follows:
 - Absolute alcohol- Two changes, 5minutes each.
 - 90% alcohol- 5 minutes.
 - 70% alcohol- 5 minutes.
 - Washed in distilled water, two changes, 2 minutes each.
4. Antigen retrieval was done for 15- 20 minutes in MERS. pH of retrieval buffer may be either 6, 8 or 9.5 according to the marker.
5. Washed in distilled water, two changes, 2 minutes each
6. Washed in PBS/TBS for 2 minutes.
7. Endogenous peroxidase blocking was done by adding H₂O₂ on the section, kept for 5minutes. Washed in the wash buffer for 3-5 minutes, twice.
8. Added primary antibody and kept for 30 minutes in a moist chamber. Then washed in wash buffer 2 times, 3-5 minutes each.
9. Added Poly excel Target binder and incubated for 12-15 minutes. Washed with wash buffer, 3-5 minutes twice.

10. Added Polyexcel HRP and incubated for 12- 15 minutes. Washed in wash buffer, 3- 5 minutes, twice.
11. Added working DAB Chromogen (1ml DAB Buffer+ 1 drop DAB Chromogen, mix well) and kept for 2- 5minutes, then washed in distilled water.
12. Counterstained with Haematoxylin for 30 seconds, washed with water.
13. Dehydrated (70%, 90%, and absolute), cleared (Xylene) and mounted as usual.

3.5 KI-67 Labelling Index

Ki-67 labelling index was analyzed in 5 different high-power microscopic fields (40x) and positive cells that showed brown nuclear reactivity were counted²². Generally, Ki-67 LI was observed higher in the peripheral portion than in the central portion of the lesion²³. Values were expressed in percentages.

3.6 Statistical Analysis

- A statistical analysis was performed with the use of SPSS version
- For multiple comparisons, post hoc Bonferroni test was used to detect the exact significance between the groups. The P value of ≤ 0.05 was taken as significant.

4. RESULTS

The present study consists of 60 cases of thyroid masses which were removed surgically and were sent for the Histopathological Examination to our department (Department of Pathology, SBMCH). All these specimens were received from the Department of Surgery, SBMCH. These 60 cases include 22(36.67%) Non-neoplastic lesions of Thyroid which include Nodular Goitre, MNG, Nodular Goitre with papillary hyperplasia, 10(16.67%) benign neoplasms of Thyroid which include 8 cases of Follicular Adenoma and 2 cases of Hurthle cell adenoma and 28 Malignant lesions of Thyroid which include 25(41.67%) cases of Papillary carcinoma of Thyroid and 3 (5%) cases of Follicular carcinoma of Thyroid.

This study does not include other Non-neoplastic lesions like thyroiditis²⁴ (Sub-acute, Hashimoto's etc.), Grave's disease and other benign and malignant lesions of Thyroid other than the lesions which are mentioned above.

4.1 Diagnostic Criteria for Non-neoplastic Lesions (MNG, NG, NGPH)

- Variable sized dilated follicles with flattened epithelium.
- Nodules may be present and also reactive fibrosis surrounding nodule present but without thick capsule.
- Papillary projections (Sanderson polsters) may be seen in cystically dilated follicles; and they may mimic papillary carcinoma but they lack nuclear features of PTC.
- Degenerative changes like haemorrhage, cystic change, foamy histiocytes and giant cell formation in the goitre.

4.2 Diagnostic Criteria for Follicular Adenoma

- Completely enveloped by thin fibrous capsule.
- Closely packed follicles, trabeculae or solid sheets.
- Patterns: 3 patterns are seen such as Normofollicular (simple), Microfollicular (fetal): small follicles that may have signet cell features and Macrofollicular (Colloid): These are large and colloid filled follicles with flattened epithelium.
- Cells show cuboidal to low columnar cells with pale staining and round inconspicuous nucleoli.
- Secondary changes like haemorrhage, sclerosis, edema, necrosis and cystic changes can be seen.
- There is no capsular or vascular invasion, no / rare mitotic figures and no papillary nuclear features are seen.

4.3 Diagnostic Criteria for Follicular Carcinoma

- Invasion of adjacent thyroid parenchyma, capsule (complete penetration) or blood vessels (in or beyond the capsule).
- No nuclear features of papillary thyroid carcinoma are seen.
- Nuclear atypia can be seen. Focal spindled areas and mitotic figures ($< 3/10$ HPF) are also present.
- There will be no necrosis, no squamous metaplasia and no/rare lymphatic invasion²⁵.

Table 2. Prevalence of thyroid lesions

Year-wise distribution of thyroid lesions Year	Total no. of Biopsy specimens received	Total no. of specimens received from surgery department	Total no. of Thyroid specimens received	% of Thyroid Cases among total biopsy specimens	% of Thyroid cases among cases received from surgery dept.
01-03-2017 to 31-12-2017	1705	676	48	2.82 %	7.1%
01-01-2018 To 31-07-2018	1188	496	30	2.52%	6.05%
Total (17 months)	2893	1172	78	2.70%	6.65%

4.4 Diagnostic Criteria for Papillary Thyroid Carcinoma

- True papillae with complex branching and fibrovascular cores associated with follicles.
- Papillae which are lined by cuboidal cells and overlapping of nuclei are seen with finely dispersed optically clear chromatin (Orphan Annie eye/ground glass appearance).
- There will be nuclear grooving with pseudo nuclear inclusions and large vesicular nucleus are seen.
- Psammoma bodies which are characteristic are seen, necrotic degeneration and squamous metaplasia are also seen. There may be Solid and trabecular areas.
- Inflammatory cells like lymphocytes, histiocytes, and multinucleated giant cells seen²⁶.

- Rarely mitotic figures or mucinous metaplasia and rare vascular invasion can be found.

During 17 months study period, total of 2893 biopsy specimens were received in our department for histopathological examination. Among these cases, a total of 1172 cases were received from surgery department, out of which 78 cases were thyroid specimens. The prevalence of thyroid specimens coming to our department from all the departments is 2.70%, out of the specimens from the surgery department, the prevalence of thyroid specimens is 6.68%.

5. HISTOPATHOLOGICAL EVALUATION OF THYROID LESIONS

The histopathological diagnosis was done for all the 78 thyroid cases, out of them 60 cases were taken for study by excluding few Non- neoplastic lesions like inflammatory lesions²⁷ as mentioned earlier and their distribution in the current study was shown in Table:3 and chart:1.

Table 3. Distribution of thyroid lesions among 60 cases

Diagnosis		No. of cases	% of cases
Non-neoplastic Benign	Nodular colloid goitre	22	36.67%
	Follicular adenoma (8)	10	16.67%
	Hurthle cell adenoma (2)		
Malignant	Follicular carcinoma Oncocytic (1)	3	5.00%
	Papillary carcinoma Follicular (10)	25	41.67%
	Classic (6)		
	Oncocytic (4)		
Total	Solid (2)		
	Micropapillary (3)		
		60	100.00%

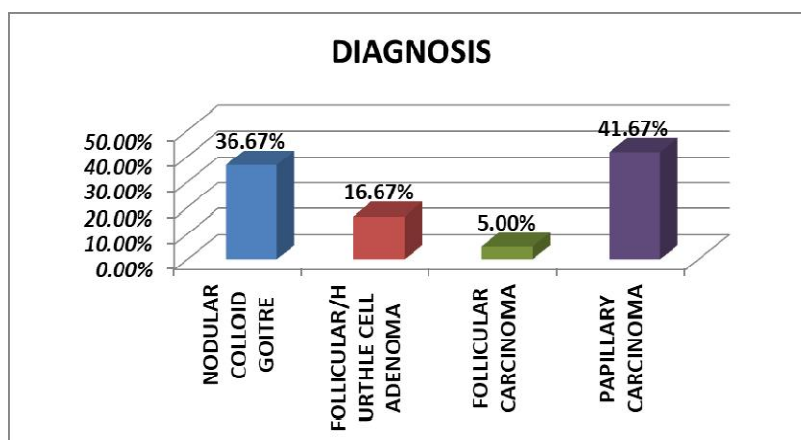


Fig. 1. Graphical representation showing diagnosis of different cases

Among the distribution of thyroid lesions, the prevalence of papillary carcinoma of thyroid cases were reported as more common which were of 41.67% in this study followed by nodular colloid goitre of 36.67%. Follicular carcinoma was of least prevalence of 5%. No medullary carcinoma and anaplastic carcinoma cases were received during this study period.

6. DISCUSSION

During the last decade, there have been increasing attempts to find out additional criteria to make accurate diagnosis of thyroid nodules. The simple and low-cost antibody-based tests can be incorporated in most of the laboratories if they are proved successful, for routine evaluation of thyroid nodules [1]. It is urgent to find out the reliable and repeatable IHC markers to distinguish between benign thyroid nodules and malignant lesions. Many studies have been tried to classify various biomarkers for thyroid carcinoma till date, on the basis of their gene expression profiles. Alterations of some proteins such as CK19, TG, galectin-3, Ki67, Calcitonin, TTF-1, BRAF, RET, Tfr1/CD71, FHL1, HBME-1, SERPINA1 were found in thyroid cancer. Some of these proteins can be applied and used in clinical practice to differentiate thyroid cancer from benign thyroid lesions [8].

Widespread application of AgNORs in tumour histopathology has been reported in assessing the growth potential and malignant potential of tumours [28], to distinguish between benign and malignant neoplasms, to assess the prognosis and also to evaluate the risk of recurrence [29]. Present study highlighted the use of Ki-67 and AgNOR counts in differentiating benign and malignant thyroid lesions [30].

6.1 Incidence of Thyroid Lesions

60 gross specimens were taken for study which were received for histopathological examination after initial cytological evaluation by FNAC (fine needle aspiration cytology) in our department of pathology, Sree Balaji Medical College, Chennai. In present study, Non-neoplastic lesions accounts for 22 cases and neoplastic lesions accounts for 38cases.

The ratio between non-neoplastic and neoplastic thyroid lesions in this study is 1:1.72. During 17 months study period, total of 2893 biopsy specimens were received in our department for histopathological examination. Among these cases, a total of 1172 cases were received from surgery department, out of which 78 cases were thyroid specimens. The histopathological diagnosis was done for all the 78 thyroid cases, out of them 60 cases were taken for study by excluding few Non- neoplastic lesions like inflammatory lesions which were received for histopathological examination following initial cytological evaluation by fine needle aspiration cytology in our department of pathology in Sree Balaji Medical College, Chennai.

In present study, Non-neoplastic lesions accounts for 22 cases and neoplastic lesions accounts for 38 cases. The ratio between non-neoplastic and neoplastic thyroid lesions in this study is 1:1.72. The prevalence of thyroid specimens coming to our department from all the departments is 2.70%, out of the specimens from the surgery department, the prevalence of thyroid specimens is 6.68%.

Among the distribution of thyroid lesions, the prevalence of papillary carcinoma cases were

reported as more common which were of 41.67% in this study followed by nodular colloid goitre of 36.67%. Follicular Adenoma cases were reported as 16.67%. Follicular carcinoma cases were reported as least prevalence of 5%. A total of 60 patients belonging to the age group of 19-70 years with the mean age of 43.08 years, were subjected to histopathological study of thyroid lesions. Female patients were of 81.67% and male patients were of 18.33% and with female to male ratio was of 4.5:1.

The present study showed that mean mAgNOR in case of nodular goitre was 1.59 (SD \pm 0.13) with a range of 1.4–1.75, in benign lesions i.e.; Follicular Adenoma / Hurthle cell Adenoma was 3.63 (SD \pm 0.41) with a range of 2.9 – 4.05, in malignant lesions i.e.; in papillary carcinoma was 2.77 (SD \pm 0.56) with a range of 1.5 – 4.05 and in follicular carcinoma was 4.92 (SD \pm 0.27) with a range of 4.68 – 5.21, highest in FTC followed by FA.

Although overlapping in range values were seen in both follicular adenoma and Papillary carcinoma, with the mean mAgNOR values and pAgNOR values, still it can be suggested that mAgNOR count and pAgNOR values can differentiate follicular adenoma and papillary carcinoma and also can differentiate non-neoplastic, benign and malignant lesions of thyroid.

7. CONCLUSION

The data which is currently available established that the evaluation of the quantity of interphase AgNORs is an independent prognostic factor in human tumour types. They are useful in discriminating between benign and malignant conditions being significantly higher in neoplastic cells than in normal cells and also useful as a significant prognostic indicator in malignant lesions. As the mean number of AgNORs is proportional to the rapidity of cell duplication, it was also found that it was related to the proliferation rate of tumour cell population. It has also been suggested that the number of AgNORs might have few diagnostic and prognostic values in different neoplasms. Although, many studies show a linear correlation between AgNOR and Ki-67 in different malignancies [26,27], the counting of mean AgNOR is more sensitive, simple and cost effective as compared to Ki-67 LI for differentiating between benign and malignant thyroid follicular neoplasms. Therefore, use of both proliferation markers can be suggested to differentiate thyroid lesions in difficult situations.

CONSENT

As per international standard or university standard, patients' written consent has been collected and preserved by the author(s).

ETHICAL APPROVAL

As per international standard or university standard ethical approval has been collected and preserved by the authors.

COMPETING INTERESTS

Authors have declared that no competing interests exist.

REFERENCES

1. Choudhury M, Singh S, Agarwal S. Diagnostic utility of Ki67 and p53 immunostaining on solitary thyroid nodule- a cytohistological and radionuclide scintigraphic study. *Indian Journal of Pathology and Microbiology*. 2011;54(3):472.
2. Kjellman P, Wallin G, Höög A, Auer G, Larsson C, Zedenius J. MIB-1 index in thyroid tumors: a predictor of the clinical course in papillary thyroid carcinoma?. *Thyroid*. 2003;13(4):371-80.
3. Yeung MJ, Serpell JW. Management of the solitary thyroid nodule. *The oncologist*. 2008;13(2):105-12.
4. Pan DH, Wen DY, Luo YH, Chen G, Yang H, Chen JQ, He Y. The diagnostic and prognostic values of Ki-67/MIB-1 expression in thyroid cancer: a meta-analysis with 6,051 cases. *Onco Targets and Therapy*. 2017;10:3261.
5. Baloch ZW, LiVolsi VA. Cytologic and architectural mimics of papillary thyroid carcinoma: diagnostic challenges in fine-needle aspiration and surgical pathology specimens. *Pathology Patterns Reviews*. 2006;125(suppl_1): S135-44.
6. Elsheikh TM, Asa SL, Chan JK, DeLellis RA, Heffess CS, LiVolsi VA, Wenig BM. Interobserver and intraobserver variation among experts in the diagnosis of thyroid follicular lesions with borderline nuclear features of papillary carcinoma. *American Journal of Clinical Pathology*. 2008; 130(5):736-44.
7. Kato MA, Fahey TJ. Molecular markers in thyroid cancer diagnostics. *Surgical Clinics*. 2009;89(5):1139-55.

8. Song Q, Wang D, Lou Y, Li C, Fang C, He X, Li J. Diagnostic significance of CK19, TG, Ki67 and galectin-3 expression for papillary thyroid carcinoma in the northeastern region of China. *Diagnostic Pathology*. 2011;6(1):126.
9. Sofiadis A, Tani E, Foukakis T, Kjellman P, Skoog L, Höög A, Wallin G, Zedenius J, Larsson C. Diagnostic and prognostic potential of MIB-1 proliferation index in thyroid fine needle aspiration biopsy. *International Journal of Oncology*. 2009; 35(2):369-74.
10. Slowinska-Klencka D, Klencki M, Popowicz B, Sporny S, Lewinski A. Multiparameter analysis of AgNOR in thyroid lesions: comparison with PCNA expression. *Histology and histopathology*. 2004;19(3): 785-92.
11. Mehrotra A, Goel MM, Singh K. Ki-67 and AgNOR proliferative markers as diagnostic adjuncts to fine needle aspiration cytology of thyroid follicular lesions. *Analytical and quantitative cytology and histology*. 2002; 24(4):205-11.
12. Yu JQ, Zhou Q, Zheng YF, Bao Y. Expression of vimentin and Ki-67 proteins in cervical squamous cell carcinoma and their relationships with clinicopathological features. *Asian Pac J Cancer Prev*. 2015; 16(10):4271-5.
13. Ghanim B, Klikovits T, Hoda MA, Lang G, Szirtes I, Setinek U, Rozsas A, Renyi-Vamos F, Laszlo V, Grusch M, Filipits M. Ki67 index is an independent prognostic factor in epithelioid but not in non-epithelioid malignant pleural mesothelioma: a multicenter study. *British Journal of Cancer*. 2015;112 (5):783.
14. Hao S, He ZX, Yu KD, Yang WT, Shao ZM. New insights into the prognostic value of Ki-67 labeling index in patients with triple- negative breast cancer. *Oncotarget*. 2016 ;7(17):24824.
15. Ito Y, Miyauchi A, Kakudo K, Hirokawa M, Kobayashi K, Miya Prognostic significance of ki-67 labeling index in papillary thyroid carcinoma. *World Journal of Surgery*. 2010;34(12):3015-21.
16. Piciu D, Irimie A. Diagnosis and treatment guidelines in thyroid carcinoma. American and European consensus, adapted to Romania. *Acta Endocrinologica-Bucharest*. 2007;3(1):103.
17. Bărbuș E, Peștean C, Larg MI, Piciu D. Quality of life in thyroid cancer patients: a literature review. *Clujul Medical*. 2017;90(2):147.
18. Heikkilä A, Siironen P, Hagström J, Heiskanen I, Sankila R, Louhimo J, Haglund C, Arola J. Follicular thyroid neoplasm: clinicopathologic features suggesting malignancy. *Apmis*. 2010;118 (11):846-54.
19. Dean DS, Gharib H. Epidemiology of thyroid nodules. *Best practice & research Clinical endocrinology & metabolism*. 2008; 22(6):901-11.
20. Nixon IJ, Simo R. The neoplastic goitre. *Current opinion in otolaryngology & head and neck surgery*. 2013;21(2):143-9.
21. Howell WM. Selective staining of nucleolus organizer regions (NORs). *Cell Nucleus*. 1982; 11:89-142.
22. Ploton D, Menager M, Jeannesson P, Himber G, Pigeon F, Adnet JJ. Improvement in the staining and in the visualization of the argyrophilic proteins of the nucleolar organizer region at the optical level. *The Histochemical Journal*. 1986;18(1):5-14.
23. Bukhari MH, Niazi S, Khan SA, Hashmi I, Perveen S, Qureshi SS, Chaudhry NA, Qureshi GR, Hasan M. Modified method of AgNOR staining for tissue and interpretation in histopathology. *International Journal of Experimental Pathology*. 2007;88(1):47-53.
24. Canet V, Montmasson MP, Usson Y, Giroud F, Brugal G. Correlation between silver-stained nucleolar organizer region area and cell cycle time. *Cytometry: The Journal of the International Society for Analytical Cytology*. 2001;43(2):110-6.
25. Aiad HA, Bashandy MA, Abdou AG, Zahran AA. Significance of AgNORs and ki-67 proliferative markers in differential diagnosis of thyroid lesions. *Pathology & Oncology Research*. 2013;19(2):167-75.
26. Dervan PA, Gilmartin LG, Loftus B, Carney DN. Argyrophilic nucleolar organiser region counts correlate with Ki67 scores. *Am. J. Clin. Pathol*. 1989;92:401-407.
27. Hall PA, Crocker J, Watts A, Stansfeld AG. A comparison of nucleolar organiser region staining and Ki-67 immunostaining in non-Hodgkin's lymphoma. *Histopathology*. 1988;12:373-381.
28. Crocker J, Nar P. Nucleolar organizer regions in lymphomas. *The Journal of Pathology*. 1987;151(2):111-8.
29. Öfner D, Hittmair A, Marth C, Öfner C, Totsch M, Daxenbichler G, Mikuz G, Margreiter R, Schmid KW. Relationship

- between quantity of silver stained nucleolar organizer regions associated proteins (Ag-NORs) and population doubling time in ten breast cancer cell lines. Pathology-Research and Practice. 1992;188(6):742-6.
30. Lundgren CI, Hall P, Ekbohm A, Frisell J, Zedenius J, Dickman PW. Incidence and survival of Swedish patients with differentiated thyroid cancer. International Journal of Cancer. 2003;106(4):569-73.

© 2021 Hamsini et al.; This is an Open Access article distributed under the terms of the Creative Commons Attribution License (<http://creativecommons.org/licenses/by/4.0>), which permits unrestricted use, distribution, and reproduction in any medium, provided the original work is properly cited.

Peer-review history:

*The peer review history for this paper can be accessed here:
<http://www.sdiarticle4.com/review-history/66762>*