



The Child with a Large Head: Cranial Computed Tomography Findings in 123 Nigerian Children with Macrocephaly

Ukamaka D. Itanyi ^{a*}, Habiba Momodu ^a,
Joshua O. Aiyekomogbon ^a, Hadijat O. Kolade-Yunusa ^a,
Ibrahim A. Yaro ^a and Chinedu S. Aruah ^a

^a Department of Radiology, Faculty of Clinical Sciences, University of Abuja, Nigeria.

Authors' contributions

This work was carried out in collaboration among all authors. Author UDI designed the study and wrote the first draft of the manuscript. Authors UDI and HM performed the literature search. Author HM wrote the protocol. Authors JOA, HOKY and IAY collected data. Author CSA managed the literature searches. All authors approved the final manuscript.

Article Information

DOI: 10.9734/AJMAH/2024/v22i2983

Open Peer Review History:

This journal follows the Advanced Open Peer Review policy. Identity of the Reviewers, Editor(s) and additional Reviewers, peer review comments, different versions of the manuscript, comments of the editors, etc are available here: <https://www.sdiarticle5.com/review-history/112341>

Original Research Article

Received: 25/11/2023
Accepted: 01/02/2024
Published: 10/02/2024

ABSTRACT

Objectives: Differentiation of benign macrocephaly from other etiologies that may require prompt evaluation and intervention is very necessary to prevent long term neurological deficits. Cross-sectional imaging of the brain with Computed Tomography (CT) or Magnetic Resonance Imaging (MRI) is recommended in evaluation of such patients. In resource poor-settings, CT is more readily available, hence the objective in this study is to evaluate the spectrum of CT findings in children with macrocephaly in our locality and document the possible etiologic factors that are amenable to surgical intervention.

Materials and Methods: This is a retrospective study of pediatric patients with clinical diagnosis of large head/macrocephaly who were evaluated with cranial CT in a tertiary hospital in Abuja from

*Corresponding author: E-mail: amakaitanyi1995@gmail.com;

January 2018- June 2022. SAS software (SAS Institute, Cary, North Carolina, USA) version 9.4 was used for database management and analysis with $P \leq 0.05$ level of significance.

Results: One hundred and twenty three children were included in the study with ages ranging from 2 days to 4 years. Majority of the children were males, 74 (60.2%). The predominant age group at presentation was between 0 to 6 months, 78 (63.4%). Hydrocephalus was the main cause of macrocephaly in 110 patients (89.4%). Congenital hydrocephalus was predominant in 81 children (73.6%). Communicating hydrocephalus was noted in 44 children (40%) while 62 (56.4%) were non-communicating. The commonest level of obstruction was at the aqueduct of Sylvius and exit foramina in 22 (35.5%) patients each. There was no significant statistical difference between the genders ($P=0.920$).

Conclusion: CT is a veritable tool in the evaluation of the child with a large head with an appreciable number of surgically amenable pathologies noted. Hydrocephalus is the commonest etiology of macrocephaly in our environment with the majority of the cases due to congenital abnormalities.

Keywords: Large heads; macrocephaly; computed tomography; children; cranial.

1. INTRODUCTION

Macrocephaly (large head) is defined as head circumference more than two standard deviations (SD) above the mean value or greater than the 97th centile for a given age and gender [1]. The patency of the fontanelles plays a key role to head growth and skull compliance with a volumetric increase in any of the intracranial compartments before the closure of the fontanelles leading to an increase in the occipitofrontal circumference (OFC). Macrocephaly is relatively common in pediatric practice occurring in about 5% of the population [2].

The etiology of macrocephaly is diverse and includes common causes like benign enlargement of subdural space (BESS) and hydrocephalus. It may also be as a result of genetic syndromes or due to intracranial hypertension secondary to tumors and cysts, pseudotumor cerebri, subdural collections or abnormal increase in size of the brain parenchyma [2].

Since clinical diagnosis can be nonspecific, imaging plays a cardinal role in establishing diagnosis and treatment of these patients with the main purpose of establishing predictors for surgical intervention, preoperative planning, and follow-up.

Radiologic investigations used include skull X-ray, trans-frontanelle ultrasonography, Computed tomography (CT) and Magnetic resonance Imaging (MRI) with a good correlation between cross sectional imaging [3].

Skull radiography, commonly used in our environment, is limited in the evaluation of the intracranial compartment and so not very useful. Ultrasonography is non-ionizing and useful before the closure of the fontanelles and has excellent spatial and anatomic resolution, particularly within the first 2 months of life after which smaller acoustic windows will limit the sensitivity of the examination [4]. Due to ignorance, most patients in our locality present late further reducing the overall usefulness of Ultrasonography [5].

MRI is non-ionizing with an excellent spatial resolution allowing for proper definition of the ventricular chain in hydrocephalus and level of obstruction, detection of intracranial masses and vascular malformations [6]. The non-availability, exorbitant cost of the few machines and long duration of image acquisition requiring sedation and contraindications in patients with ferromagnetic implants are disadvantages to its use.

CT scan on the other hand is more readily available in our environment, reproducible and with greater advantage in emergency situations because of its speed of image acquisition and superior ability to detect small foci of hemorrhage and calcifications [7]. It is however ionizing with risk of radiation hazard to the developing brain.

Early detection and differentiation of benign macrocephaly from other etiologies that may require prompt evaluation and intervention is very necessary to prevent long term neurological deficits [8].

The purpose of this study is to evaluate the spectrum of CT findings in children with macrocephaly, document the possible etiologic factors involved and determine the occurrence of surgically amenable pathologies while adding to the body of literature.

2. MATERIALS AND METHODS

This is a cross sectional evaluation of pediatric patients with clinical features of macrocephaly referred to the Radiology department of a tertiary health care centre in Abuja, Nigeria for cranial CT scan. The study period was from January 2018- June 2022. The study complied with the local ethical standard in accordance with the Helsinki Declaration. No patient consent was obtained since stored data was used. Confidentiality of data was strictly maintained.

CT scan was performed using Toshiba ACTIVION 16 CT machine [2007, Japan]. A scanogram and helical-acquired continuous axial slices of 5 mm thickness were taken from the base of the skull to the vertex. Images obtained were subjected to multiplanar reformatting in coronal and sagittal orthogonal planes. The principal researcher examined all the cranial CT scans in soft tissue window (80W and 35C for the brain). A 512 x 512 matrix with a 1.0 mm slice thickness, kernel H60 sharp, 200 mm field of view, and modified window width (50) and level (250) was employed for the CT brain protocol. Intravenous contrast was used in 20 patients with predetermined clinical features of space occupying lesions and 25 with clinical features of intracranial infection. Criteria for

diagnosis of hydrocephalus included dilated intracranial ventricles including the temporal horns and inferior recesses of third ventricle, transependymal hypodensity and Evan's index greater than 0.3 (ratio of the maximum width of the frontal horn to the maximum inner diameter of the skull [9]).

Patients with previous intracranial surgery were excluded from the study. Data was obtained from the patient's records and Images viewed from the departmental Picture archiving and communication system, PACS.

2.1 Data Analysis

SAS software (SAS Institute, Cary, North Carolina, USA) version 9.4 was used for database management and analysis.

Numerical descriptors used to summarize data include mean, standard deviation, minimum and maximum values for continuous variables while frequency and percentage were used to describe categorical variables. Fisher's exact test was used to assess the relationship between sex and the different radiologic parameters with $p \leq 0.05$ level of significance.

3. RESULTS

One hundred and twenty three children were included in the study, 74 males (60.2%) and 49 (39.8%) females in a ratio of 1.5:1. The age range was from 2 days to 4 years and predominant age group was 0-6months. See Fig. 1.

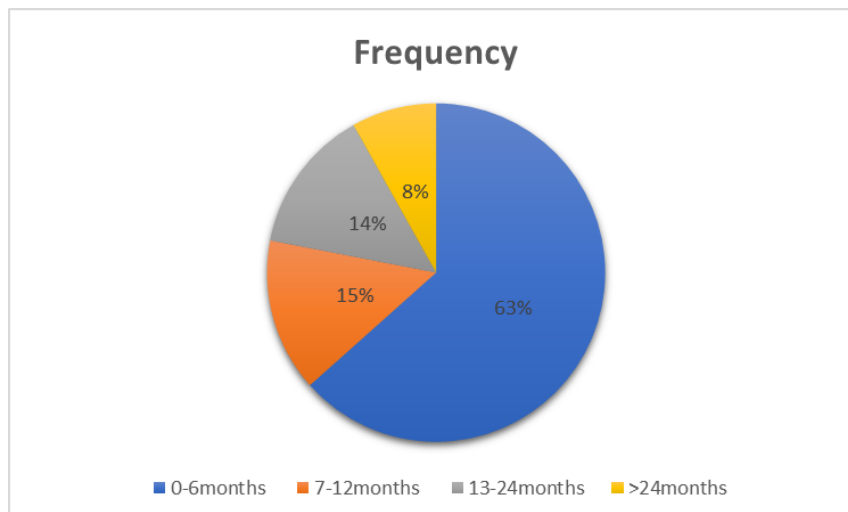


Fig. 1. Pie chart showing age range of patients

Table 1. Etiology of hydrocephalus among participants

Hydrocephalus	Frequency (%)	Percentage
A. Congenital/developmental malformation		
Aqueductal Stenosis	17	15.5
Arnold Chiari	8	7.3
Dandy Walker	13	11.8
Congenital cysts + ventriculomegaly	13	11.8
Congenital infantile hydrocephalus	27	24.5
Encephalocele	2	1.8
Vein of Galen aneurysm	1	0.9
B. Acquired		
Post Meningitis	18	16.4
Intracranial tumors	8	7.3
Post neonatal trauma	3	2.7
Total	110 (100)	100

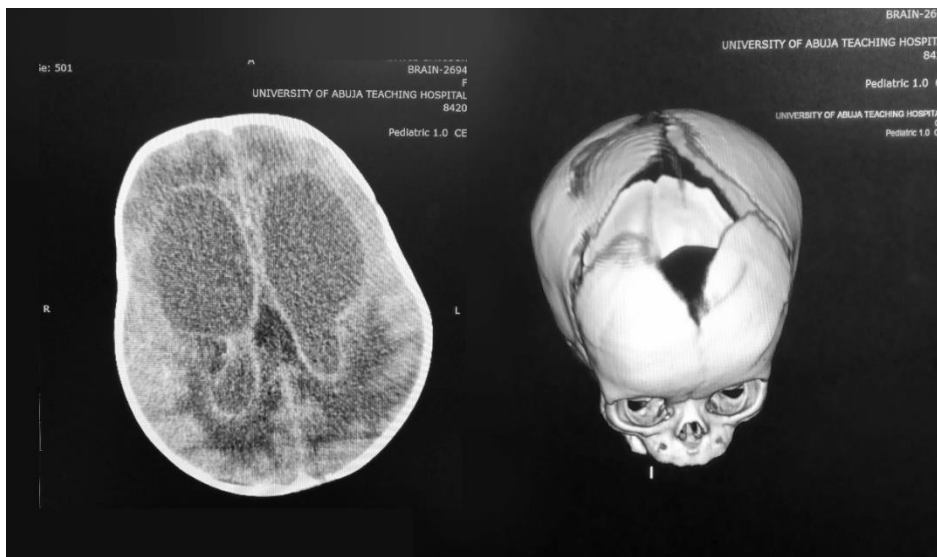


Fig. 2. Axial and 3D reformatted cranial CT images of a 3/12 female with post-meningitic hydrocephalus and macrocephaly.

Table 2. Characteristics of hydrocephalus among study patients

Obstruction Type	All	%	Female (n,%)	Male (n,%)
Communicating	44	40	20 (18.2)	24 (21.8)
Obstructive	62	56.4	23 (20.9)	39 (35.5)
Unspecified	4	3.6	1 (0.9)	3 (2.7)
Total	110	100%	44 (39.8)	56 (60)

Table 3. Distribution of levels of non-communicating hydrocephalus

Obstruction level	All	%	Female (n,%)	Male (n,%)
Aqueduct	22	35.5	9 (14.5)	13 (21)
3 rd ventricle	7	11.3	1 (1.6)	6 (9.7)
4 th ventricle	7	11.3	3(4.8)	4(6.5)
Lateral ventricle	4	6.5	2 (3.2)	2 (3.2)
Exit foramina	22	35.5	9(14.5)	13 (21)
Total	62	100	24 (25.8)	38 (61.3)

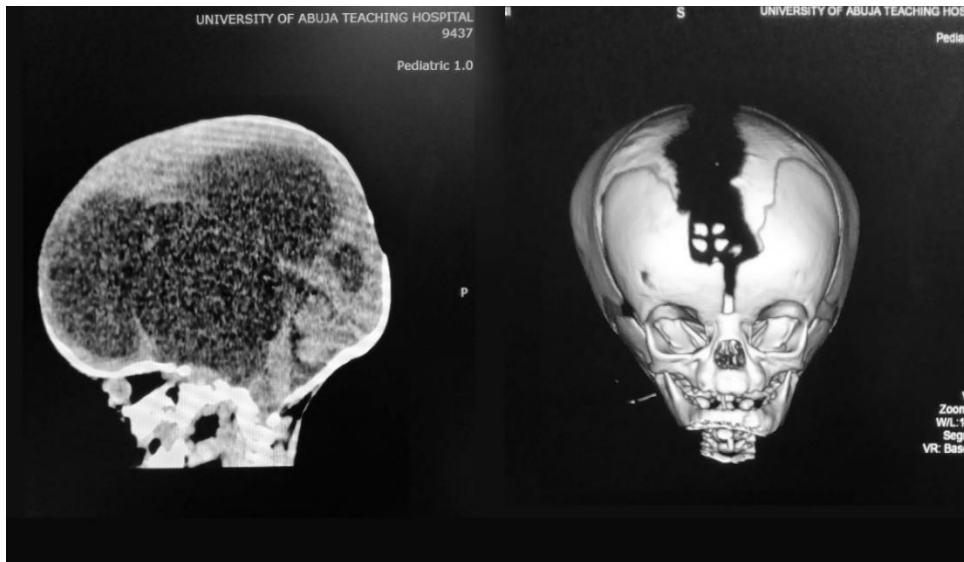


Fig. 3. Sagittal and 3D reformatted cranial CT of a 4/12 old male with macrocephaly and severe non-communicating hydrocephalus at the level of the aqueduct

Clinically, all the patients presented with enlarged head, and some presented with additional clinical indications including post meningitis in 18 (14.6%) and clinical features of space occupying lesion in 6 (4.9%).

On Brain CT, 110 (89.4%) of the children had macrocephaly secondary to hydrocephalus seen as increased Evans index >0.3.

Benign enlargement of subarachnoid space was the cause of macrocephaly in 6 (4.9%) children with 7 (5.7) % syndromic children.

Most of the cases of hydrocephalus were congenital (73.6%) with severe infantile hydrocephalus the commonest (24.5%); while the acquired type was seen in 26.4% of cases. See Table 1 and Fig. 2.

The predominant type of hydrocephalus was obstructive in 62 patients (56.4%) with the commonest level of obstruction at the aqueduct of sylvius and 4th ventricle (71%). See Table 2

and 3 and Fig. 3. The p-value from the Fisher's exact test was 0.9202, therefore, no relationship was found between sex and type of hydrocephalus and the obstruction level of non-communicating hydrocephalus.

4. DISCUSSION

Despite the lack of consensus for imaging guidelines in children with macrocephaly, it is recommended that CT or MR brain imaging should be considered in children with abnormal ultrasound findings of neurodevelopmental abnormalities or features of raised intracranial pressure [10]. CT, which is more readily available and less costly, finds greater use in our resource challenged environment hence its use in this study.

The male predominance in macrocephaly seen in this study is consistent with others in different parts of the world [11,12-15]. Our finding of hydrocephalus as the dominant etiology of

macrocephaly defers markedly with the studies by Jeong et al. [12], Yilmazbaş et al. [13] and Sampson et al. [14] who reported familial macrocephaly and BESS as the commonest etiology in imaging. Unlike these studies which were conducted in more developed countries with different health seeking behaviors, we noted BESS and syndromic children in 4.9% and 5.7% respectively. Self-medication and late presentation of pediatric patients to clinics is a very common occurrence in Nigeria hence the likelihood that patients with pathologic causes of macrocephaly are more probable to come in for further evaluation [5]. This presumably explains the similarity between our study and that done in South-East Nigeria which showed BESS and Hydranencephaly in 1.25% and 6.2% respectively [16].

Among the syndromic children in the current study were holoprosencephaly in 3, Hydranencephaly in 3 and Schizencephaly in 1 child. This finding is important since Holoprosencephaly has been associated with Trisomy 13 and Trisomy 18 with prevalence ranging from 62% to 86% and 11% to 17%, respectively [17].

Without an international consensus on categorization of hydrocephalus, a number of classification systems are being used. Hydrocephalus, which is the commonest cause of macrocephaly in our study, can be classified based on etiology. Most of our patients (73.6%) had congenital etiology similar to the studies by Ayodeji et al. [18] who reported (69%) in North Central Nigeria, Gele et al. [11] in Sokoto, Nigeria (54%) and Al Nadawwi et al. [19] in Iraq who reported (72%). This finding of high level of congenital cause for hydrocephalus is very important since it has been attributed to poor socioeconomic status, poor use of antenatal care and consequently lack of folic acid supplementation which are noted to be common in Northern Nigeria [20] where the index study was undertaken.

The finding however differed from that of Waif et al. [19] in Uganda, Jaiswal et al. [20] in India and Usman et al. [23] in NE Nigeria which reported predominantly acquired cases mostly due to post infective causes.

Post-infectious etiology in the current study (16.4%) falls within the range recorded in Africa (7% - 60%) in Africa [21]. The inflammatory exudates and scarring or gliosis associated with brain infections can lead to obstruction to CSF

flow in the ventricular system and /or subarachnoid spaces, leading to either obstructive or communicating hydrocephalus [8].

Non-communicating hydrocephalus has been documented to be commoner in children and is concordant with the index study which records majority of the children (56.4%) with non-communicating hydrocephalus vs (40%) with communicating hydrocephalus. This is similar to most other studies [16,18,21-24]. Imaging is invaluable in distinguishing between the two types since early identification can save lives especially in the cases of non-communicating hydrocephalus, which may require surgical decompression [25]. The commonest levels of obstruction were at the aqueduct of Sylvius (connecting the third ventricle to the posterior fossa) and the exit foramina making up 71% of cases. Major contributing factors to this level of obstruction were developmental anomalies including Dandy walker malformations (11.8 %) and Aqueductal stenosis (15.5%). The latter was primary without any definable cause on CT. Genetic factors have been implicated in the development of such isolated cases [26].

Hydrocephalus and subsequently macrocephaly is a common presentation in pediatric patients with intracranial neoplasm. Unlike a previous study which showed that 56.7% of pediatric patients with primary brain tumor had hydrocephalus, [27] intracranial tumors were noted as a contributor to obstructive hydrocephalus in all the children with primary brain tumor in the index study. The index study noted 4 infratentorial and 4 supratentorial tumors with 1 intraventricular tumor.

Although post-hemorrhagic hydrocephalus of prematurity is one of the common causes of hydrocephalus in developed countries with an incidence between 25% - 50% [28], we recorded only 0.7%. This is close to the study by Obanife et al. [29] who reported 2.9% of cases. They exerted that the relative rarity can be ascribed to the underdevelopment of neonatal care services in their locality.

Indications for surgical intervention in macrocephaly are determined by the etiology with Ventriculoperitoneal shunt (VPS) still the most common treatment for hydrocephalus in Nigeria [18]. BESS, being self-limiting is followed up unlike hydrocephalus which can be pathological.

The study by Medina et al. [2] showed that imaging was a veritable tool in predicting lesions that required surgical intervention and these included moderate-to-severe ventriculomegaly and focal space-occupying lesions as noted in the current study.

The significance of this study is that it has highlighted surgically amenable etiologies of macrocephaly in our locality and the role of CT in diagnostic evaluation of these patients especially in the absence of MRI.

The poor record keeping in our facility limited our ability to further compare signs and symptoms of neurological deficits of children to imaging findings. This is important in determining children that require neuroimaging.

5. CONCLUSION

Cranial Computed Tomography is a veritable tool in the evaluation of the child with a large head with an appreciable number of surgically amenable pathologies noted. Hydrocephalus is the commonest etiology of macrocephaly in our environment with most of the cases due to congenital abnormalities. This further highlights the need for meticulous evaluation of the fetal head during prenatal obstetric scan.

CONSENT

It is not applicable.

ETHICAL APPROVAL

Permission for this study was obtained by the hospital ethical research committee. UATH/HREC/PR/2024/01/101.

ACKNOWLEDGEMENT

We acknowledge the support of the departmental secretarial staff in preparing the manuscript.

COMPETING INTERESTS

Authors have declared that no competing interests exist.

REFERENCES

1. Varma R, William SD, Wessel HB. Neurology. Zitelli BJ, Davis HW. Atlas of pediatric physical diagnosis. Fifth Edition. Philadelphia: Mosby Elsevier. 2007;563.
2. Medina LS, Frawley K, Zurakowski D, Buttros D, DeGrauw AJ, Crone KR. Children with macrocrania: Clinical and imaging predictors of disorders requiring surgery. American Journal of Neuroradiology. 2001, Mar 1;22(3):564-70.
3. Vertinsky AT, Barnes PD. Macrocephaly, increased intracranial pressure, and hydrocephalus in the infant and young child. Topics in Magnetic Resonance Imaging. 2007, Feb 1;18(1):31-51.
4. Smith R, Leonidas JC, Maytal J. The value of head ultrasound in infants with macrocephaly. Pediatr Radiol. 1998;28: 143–146.
5. Okolo CO. Late presentation of paediatric patients to clinics: A major barrier to uptake of laboratory services in Nigeria. Antimicrobial Resistance and Infection Control. 2015, Dec;4(1):1.
6. Algin O, Ozmen E, Karaoglanoglu M. The role of MRI in pediatric obstructive hydrocephalus: An update. Journal of Pediatric Neuroradiology. 2012;2:71–80.
7. Itanyi DU, Uduma FU, Aiyekomogbon JO. Value of computed tomography scan in evaluation of adult onset seizures in north-central Nigeria. Sub-Saharan African Journal of Medicine. 2018, Oct 1;5(4):111.
8. Jones SG, Samanta D. Macrocephaly. [Updated 2023 Jul 24]. In: StatPearls [Internet]. Treasure Island (FL): StatPearls Publishing; 2023, Jan 12.
9. Palla R. Evaluation of Evan's index by computed tomography in hydrocephalic children in tertiary hospital of Telangana. IJARS. 2018, Jan;7(1):AO01-AO04.
10. Haws ME, Linscott L, Thomas C, Orscheln E, Radhakrishnan R, Kline-Fath B. A retrospective analysis of the utility of head computed tomography and/or magnetic resonance imaging in the management of benign macrocrania. J Pediatr. 2017;182: 283-289.e1. DOI:10.1016/j.jpeds.2016.11.033
11. Gele IH. Cranial computed tomographic findings in children with hydrocephalus in Sokoto north western Nigeria. SAR J Med Case Rep. 2021;2(2):5-10.
12. Jeong G, Kim M, Han BH. Clinical features of macrocephaly at birth in Korea. Korean journal of Pediatrics. 2014, Feb;57(2):75.
13. Yılmazbaş P, Gökçay G, Eren T, Karapınar E, Kural B. Macrocephaly diagnosed during well child visits. Pediatr Int. 2018, May;60(5):474-477.

- DOI:10.1111/ped.13543. PMID: 29498760.
14. Sampson MA, Berg AD, Huber JN, Olgun G. Necessity of intracranial imaging in infants and children with macrocephaly. *Pediatric Neurology*. 2019, Apr 1;93:21-6.
 15. ÖZTÜRK Z, SERİN MZ. Neuroimaging indications for children with macrocephaly. *Türkiye Çocuk Hastalıkları Dergisi*. 2020, Jan 1;14(1):85-8.
 16. Dim NR, Nnamani AO, Mgbe EK, Okwor CN, Iloanusi NI, Uche EO, Okere PC. Paediatric hydrocephalus: Pre-treatment computed tomography findings in 80 consecutive patients. *International Journal of Medicine and Health Development*. 2018;23(1):289-94.
 17. Syngelaki A, Guerra L, Ceccacci I, Efturk T, Nicolaidis KH. Impact of holoprosencephaly, exomphalos, megacystis and high NT in first tri-mester screening for chromosomal abnormalities. *Ultrasound Obstet Gynecol*. 2017;50(1):45-48.
 18. Yusuf AS, Omokanye HK, Adeleke NA, Akanbi RO, Ajiboye SO, Ibrahim HG. Management and outcome of infantile hydrocephalus in a tertiary health institution in Nigeria. *Journal of Neurosciences in Rural Practice*. 2017 Apr; 8(02):249-53.
 19. Al Naddawi MN, Hameed NN, Rasheed AA. Demographic and clinical presentations of pediatric hydrocephalus in medical city. *Iraqi Postgraduate Medical Journal*. 2011, Jun 28;10(2).
 20. Adewuyi EO, Auta A, Khanal V, Bamidele OD, Akuoko CP, Adefemi K, Tapshak SJ, Zhao Y. Prevalence and factors associated with underutilization of antenatal care services in Nigeria: A comparative study of rural and urban residences based on the 2013 Nigeria demographic and health survey. *PLoS One*. 2018, May 21 ;13(5): e0197324. DOI: 10.1371/journal.pone.0197324.
 21. Warf BC. Hydrocephalus in Uganda: The predominance of infectious origin and primary management with endoscopic third ventriculostomy. *J Neurosurg*. 2005;102(1 Suppl):S1–15.
 22. Jaiswal A, Jaiswal J. Incidence of hydrocephalus in pediatric age in a tertiary care centre of Chhattisgarh. *Journal of Evolution of Medical and Dental Sciences*. 2015, Oct 15;4(83):14564-72.
 23. Usman B, Wabada S, Oyinloye A, Ahmadu B, Mada W, Bulus S, Dodo M, Abubakar AM. Demography and management of childhood hydrocephalus in Yola, adamawa state, Nigeria. *Jewel Journal of Medical Sciences*. 2020, Jun 1;1(1):78-85.
 24. Paulson JN, Williams BL, Hehnlly C, Mishra N, Sinnar SA, Zhang L et al. Paenibacillus infection with frequent viral coinfection contributes to postinfectious hydrocephalus in Ugandan infants. *Sci Transl Med*. 2020, Sep 30;12(563).
 25. Maller VV, Gray RI. Noncommunicating hydrocephalus. *Seminars in Ultrasound, CT, and MRI*. 2016;(2):109-119.
 26. Kahle KT, Kulkarni AV, Limbrick Jr DD, Warf BC. Hydrocephalus in children. *Lancet*. 2016;387:788–99. Available:[http://dx.doi.org/10.1016/S0140-6736\(15\)60694-8](http://dx.doi.org/10.1016/S0140-6736(15)60694-8)]
 27. Wong TT, Liang ML, Chen HH, Chang FC. Hydrocephalus with brain tumors in children. *Child's Nervous System*. 2011; (27):1723-34.6.
 28. Chritian EA, Melamed EF, Peck E, Krieger MD, McComb GJ. Surgical management of hydrocephalus secondary to intraventricular haemorrhage in the preterm infant. *J. Neurosurg (Paediatric)*. 2016;17:276–84.
 29. Obanife HO, Nasiru JI, Lasseini A, Ega OJ, Shehu BB. Childhood hydrocephalus in Sokoto: Experience with 401 Series. *J Pediatr Neurosci*. 2021, Apr-Jun;16(2):119-124.

© 2024 Itanyi et al.; This is an Open Access article distributed under the terms of the Creative Commons Attribution License (<http://creativecommons.org/licenses/by/4.0>), which permits unrestricted use, distribution, and reproduction in any medium, provided the original work is properly cited.

Peer-review history:

The peer review history for this paper can be accessed here:
<https://www.sdiarticle5.com/review-history/112341>